

Case Report

## Extracorporeal shock wave therapy relieved pain in patients with coccydynia: a report of two cases

Yousef Marwan, MBBS<sup>a,\*</sup>, Wael Husain, MBBS, FRCSC<sup>a</sup>,  
Waleed Alhajii, MBBS, MSc, Facharzt<sup>b</sup>, Magdy Mogawer, MBBS<sup>b</sup>

<sup>a</sup>Department of Orthopaedic Surgery, Jaber Al-Ahmad Armed Forces Hospital, PO Box 24923, 13110 Safat, Kuwait

<sup>b</sup>Department of Radiology, Jaber Al-Ahmad Armed Forces Hospital, Safat, Kuwait

Received 25 October 2012; revised 27 June 2013; accepted 13 July 2013

### Abstract

**BACKGROUND CONTEXT:** Extracorporeal shock wave therapy (ECSWT) has been used widely for musculoskeletal conditions; however, no reports are available about its use for coccydynia.

**PURPOSE:** Study the effect of ECSWT in relieving pain of coccydynia.

**STUDY DESIGN:** Case report.

**METHODS:** Extracorporeal shock wave therapy was used for two male patients, Patients 1 and 2, who failed to respond completely to other conservative management of coccydynia. Numerical pain scale (NPS) and visual analogue scale (VAS) were used to assess the pain. Consent to publish the data was obtained from both the patients.

**RESULTS:** Before starting ECSWT, Patient 1 reported a pain intensity of 6/10 and 5.1/10 on NPS and VAS, respectively, whereas the intensity of pain in Patient 2 was 7/10 and 6.9/10 on NPS and VAS, respectively. Four weeks after ECSWT, Patient 1 reported complete relief of pain on NPS and VAS, whereas Patient 2 reported a pain intensity of 1/10 and 0.8/10 on NPS and VAS, respectively. The same intensity of pain was reported by both patients after 12 months of follow-up.

**CONCLUSIONS:** Extracorporeal shock wave therapy relieved pain of coccydynia in our patients. © 2014 Elsevier Inc. All rights reserved.

### Keywords:

Coccydynia; Coccygodynia; Coccyx; Extracorporeal shock wave therapy; Spine

### Introduction

Coccydynia refers to pain in the region of the coccyx that can be idiopathic or with underlying pathology [1–4]. The pain arising from this condition can limit daily activities; thus, a prompt diagnosis and management is necessary [1–8]. Nonoperative methods including the use of nonsteroidal anti-inflammatory drugs (NSAIDs), postural adjustments (eg, using donut pillow), physical therapy (eg, levator antistretching and massaging), local injections of steroid or anesthetics, coccygeal manipulation, and radiofrequency ablation are commonly used to treat coccydynia

[9–11]. Alternatively, surgical management through total coccygectomy or excision of the mobile segment of the coccyx can be used for cases refractory to the nonoperative treatment [1,12–16].

Extracorporeal shock wave therapy (ECSWT) has been used in the treatment of many musculoskeletal conditions during the past 15 years. These conditions include delayed unions/nonunions of fractures, calcific tendinitis of the shoulder, lateral epicondylitis of the elbow, avascular necrosis of the femoral head, jumper's knee, Achilles tendinopathy, plantar fasciitis, and others [17]. Although the mechanism of action of ECSWT in relieving the pain of musculoskeletal conditions is not clearly understood, it is believed that the neovascularization and the increase in blood supply resulting from this therapy initiate healing and repair [17–20].

In this report, we present two cases of coccydynia that were treated successfully using ECSWT. Both patients were informed that data regarding their cases will be used for publication, and their consents were taken.

FDA device/drug status: Not approved for this indication (Extracorporeal shock wave).

Author disclosures: **YM:** Nothing to disclose. **WH:** Nothing to disclose. **WA:** Nothing to disclose. **MM:** Nothing to disclose.

\* Corresponding author. Department of Orthopaedic Surgery, Jaber Al-Ahmad Armed Forces Hospital, PO Box 24923, 13110 Safat, Kuwait. Tel.: (965) 94060660.

E-mail address: [yousefmarwan@hotmail.com](mailto:yousefmarwan@hotmail.com) (Y. Marwan)

### Case reports

Patient 1, a 38-year-old man, presented with 3 months history of pain in and around the tailbone/coccyx area. The pain was associated with prolonged sitting and relieved by sitting on the legs or on one buttock. It exacerbates when

rising from a seated position. No relation between the pain and the defecation was reported. There was no history of pain in other parts of the spine and pelvis. The patient did not complain of any genitourinary or gastroenterology symptoms. He also denied any history of trauma to the area of pain. The patient is known to have peptic ulcer disease

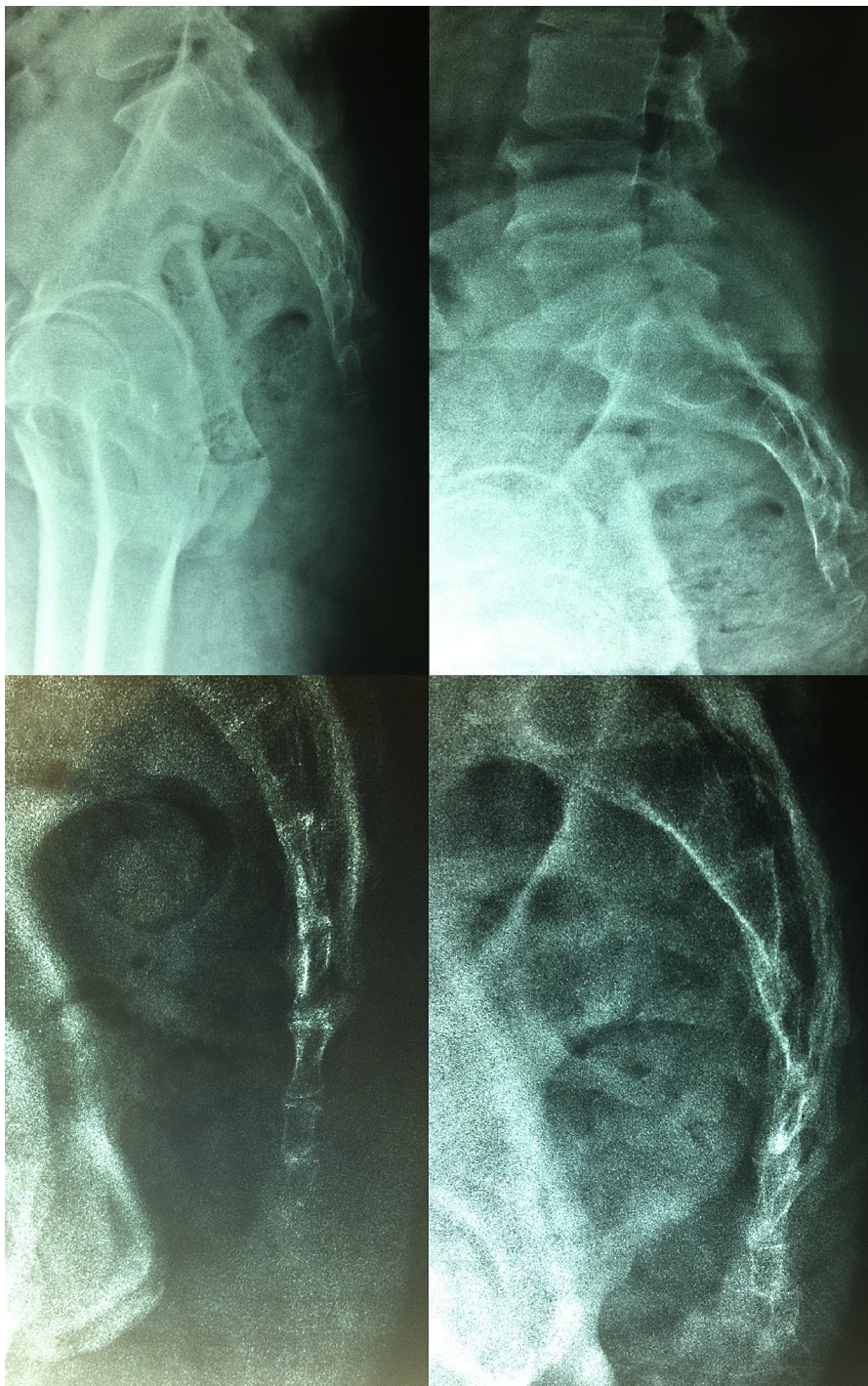


Figure. Dynamic films of the coccyx for two male patients with coccydynia. (Top Left) represents the standing film of Patient 1; (Top Right) represents the sitting film of Patient 1; (Bottom Left) represents the standing film of Patient 2; and (Bottom Right) represents the sitting film of Patient 2. Dynamic films of Patient 1 show marked anterior curvature of the coccyx with apex pointing anteriorly, coccygeal angle of motion of  $1^{\circ}$ , and calcification of most of the coccygeal segments. Dynamic films of Patient 2 show posterior subluxation at the level of the second intercoccygeal joint and a coccygeal angle of motion of  $10^{\circ}$ .

since 12 years ago (was on esomeprazole 20 mg once daily). Patient 2, a 40-year-old man, presented with the same symptoms of Patient 1; however, his pain started around 1 year ago, and he had no past medical illnesses or history of trauma to the sacrococcygeal area. He was referred to a general surgeon after ruling out perianal conditions.

On physical examination, both patients experienced tenderness over the sacrococcygeal region. Pain was also elicited by rectal manipulation of the coccyx. No other positive findings were found during physical examination. The body mass index (BMI; kilograms per meter square) of both patients was calculated after measuring their weight and height. Patient 1 had a BMI of 27.41 kg/m<sup>2</sup>, whereas Patient 2 had a BMI of 26.01 kg/m<sup>2</sup>. Dynamic radiographs of the coccyx were obtained for both patients (Figure). Radiographs of Patient 1 revealed marked anterior curvature of the coccyx with apex pointing anteriorly, coccygeal angle of motion was almost 1°, and calcification of most of the coccygeal segments. On the other hand, radiographs of Patient 2 revealed posterior subluxation at the level of the second intercoccygeal joint, and the coccygeal angle of motion was 10°.

Before starting any treatment, both patients were asked to report their intensity of pain on a numerical pain scale (NPS; from 0=no pain to 10=maximal pain) and visual analogue scale (VAS, 10 cm). The intensity of pain in Patient 1 was 9/10 and 8.9 on NPS and VAS, respectively, whereas Patient 2 reported a pain intensity of 8/10 and 7.7 on NPS and VAS, respectively. Both patients were started on an NSAID (etoricoxib 60 mg once daily) and advised to use a donut pillow when sitting. Four weeks after this treatment regimen, the pain intensities of 6/10 and 7/10 on NPS were reported by Patients 1 and 2, respectively. Moreover, the pain intensities were 5.1 and 6.9 on VAS for Patients 1 and 2, respectively. Following this, both patients were referred for three sessions (one session/week for 3 consecutive weeks) of ECSWT delivering 3,000 shock waves per session of 0.2 mJ/mm<sup>2</sup> directed to the coccyx and were advised to discontinue using the NSAID and the donut pillow. Patient 1 reported complete relief of pain (intensity of 0 on NPS and VAS) 4 weeks, 12 weeks, and 1 year after the last session of ECSWT. On the other hand, the pain intensities of 1/10 and 0.8 on NPS and VAS, respectively, were reported by Patient 2 at 4 weeks, 12 weeks, and 1 year after the last session of ECSWT. At 1 year after the treatment, dynamic films of the coccyx were obtained for both patients. These films did not show any changes compared with the films obtained before starting the treatment. No treatment complications were noted in both patients.

## Discussion

In this report, we presented the first two cases of coccydynia that were treated using ECSWT. The proposed reason

for the pain in patients with coccydynia is the development of inflammatory changes in the area of the coccyx [1]. Regardless of the cause of coccydynia (eg, trauma, instability, etc.), the result is a chronic inflammation, which leads to the production of pain [1,21]. This is why we used this modality of treatment for these patients and also might explain the reason why our patients responded well to the treatment. The ECSWT probably reduced the inflammatory process in the coccygeal region in our patients.

Although ECSWT provided good treatment outcomes in our cases, this report has its limitations. The possibility of a placebo effect contributing to the outcome gained following the use of ECSWT in relieving the pain of coccydynia cannot be ruled out. Moreover, we used ECSWT only for male patients with specific abnormalities (one patient had subluxation and the other had immobility and calcifications). Because we limited our follow-up to 12 months only and our patients still had the same abnormal radiographic findings at that time, we are not sure if the pain will reoccur again or not. Therefore, we recommend larger case series about the use of ECSWT for coccydynia. These series should include patients from both genders and with diverse etiologies of coccydynia. A longer duration of follow-up is also recommended. In addition, randomized controlled trials comparing the use of ECSWT and other treatment modalities for this condition should be considered.

## Conclusion

Extracorporeal shock wave therapy appeared to be useful in relieving the pain of coccydynia in our patients. It can be considered as a good conservative therapy for this condition; however, this should be confirmed by larger future studies.

## References

- [1] Nathan ST, Fisher BE, Roberts CS. Coccydynia: a review of pathoanatomy, aetiology, treatment and outcome. *J Bone Joint Surg Br* 2010;92:1622–7.
- [2] Maigne J, Doursounian L, Chatterlier G. Causes and mechanisms of common coccydynia: role of body mass index and coccygeal trauma. *Spine* 2000;25:3072–9.
- [3] Postacchini F, Massobrio M. Idiopathic coccygodynia. Analysis of fifty-one operative cases and a radiographic study of the normal coccyx. *J Bone Joint Surg* 1983;65:1116–24.
- [4] Fogel G, Cunningham P, Esses S. Coccygodynia: evaluation and management. *J Am Acad Orthop Surg* 2004;12:49–54.
- [5] Patel R, Appannagari A, Whang PG. Coccydynia. *Curr Rev Musculoskelet Med* 2008;1:223–6.
- [6] Maigne J, Tamalet B. Standardized radiologic protocol for the study of common coccydynia and characteristics of the lesions observed in the sitting position. *Spine* 1996;21:2588–93.
- [7] Maigne JY, Pigeau I, Roger B. Magnetic resonance imaging findings in the painful adult coccyx. *Eur Spine J* 2012;21:2097–104.
- [8] Maigne JY, Pigeau I, Aguer N, et al. Chronic coccydynia in adolescents. A series of 53 patients. *Eur J Phys Rehabil Med* 2011;47:245–51.
- [9] Wray C, Easom S, Hoskinson J. Coccydynia: aetiology and treatment. *J Bone Joint Surg Br* 1991;73:335–8.

- [10] Maigne J, Chatterlier G. Comparison of three manual coccydynia treatments: a pilot study. *Spine* 2001;26:E479–84.
- [11] Scemama P, Shaparin N, Kaufman A, Dua S. Radiofrequency ablation within the first intercoccygeal disk for coccygodynia: a case report. *Pain Pract* 2011;11:278–81.
- [12] Ballain B, Eisenstein M, Alo G, et al. Coccygectomy for coccydynia: case series and review of literature. *Spine* 2006;31:E414–20.
- [13] Pennekamp P, Kraft C, Stutz A, et al. Coccygectomy for coccygodynia: does pathogenesis matter? *J Trauma* 2005;59:1414–9.
- [14] Cheng SW, Chen QY, Lin ZQ, et al. Coccygectomy for stubborn coccydynia. *Chin J Traumatol* 2011;14:25–8.
- [15] Trollegaard AM, Aarby NS, Hellberg S. Coccygectomy: an effective treatment option for chronic coccydynia: retrospective results in 41 consecutive patients. *J Bone Joint Surg Br* 2010;92:242–5.
- [16] Mouhsine E, Garofalo R, Chevalley F, et al. Posttraumatic coccygeal instability. *Spine J* 2006;6:544–9.
- [17] Wang CJ. Extracorporeal shockwave therapy in musculoskeletal disorders. *J Orthop Surg Res* 2012;7:11.
- [18] Wang CJ, Huang HY, Pai CH. Shock wave enhances neovascularization at the tendon-bone junction. *J Foot Ankle Surg* 2002;41:16–22.
- [19] Wang CJ, Yang KD, Wang FS, et al. Shock wave induces neovascularization at the tendon-bone junction. A study in rabbits. *J Orthop Res* 2003;21:984–9.
- [20] Wang CJ, Ko JY, Chan YS, et al. Extracorporeal shockwave for chronic patellar tendinopathy. *Am J Sports Med* 2007;35:972–8.
- [21] Simpson J. Clinical lectures on the diseases of women Lecture XVII: coccydynia and diseases and deformities of the coccyx. *Medical Times Gazette* 1859;40:1–7.