



# **DIGEST Guidelines for Extracorporeal Shock Wave Therapy**

**Translation by MTS Medial UG  
Sponsoring Member of DIGEST**



# **DIGEST Guidelines**

for Extracorporeal Shock Wave Therapy  
Updated 05/2019

## **Table of Contents**

<b>1</b>	<b>Physics and Technology of ESWT</b>	Dr. Vinzenz Auesperg	p. 03
<b>2</b>	<b>Practical Application</b>		
	<u>Tendopathies Upper Extremities</u>		
	Tendinosis calcarea	Prof. Dr. Ludger Gerdesmeyer	p. 20
	Radial epicondylopathy	Sergej Thiele	p. 26
	Ulnare epicondylopathy	Sergej Thiele	p. 30
	Morbus Dupuytren	Prof. Dr. Karsten Knobloch	p. 33
	<u>Tendopathies Lower Extremities</u>		
	Trochanteric pain syndrome	PD Dr. Jörg Hausdorf	p. 37
	Plantar fasciitis	PD Dr. Jörg Hausdorf	p. 40
	Achilles tendon tendinopathy	Dr. Martin Ringeisen	p. 44
	Patellar tip syndrome	Dr. Martin Ringeisen	p. 49
	Tibial stress syndrome	Dr. Martin Ringeisen	p. 56
	Hamstring tendinopathy	Dr. Martin Ringeisen	p. 59
	Morbus Ledderhose	Prof. Dr. Karsten Knobloch	p. 62
	<u>Cartilage and Bone</u>		
	Arthrosis	Sergej Thiele	p. 65
	Osteochondrosis dissecans	Sergej Thiele	p. 69
	Bone marrow edema syndrome	Sergej Thiele / Dr. W. Schaden	p. 73
	Pseudarthrosis	Dr. Wolfgang Schaden	p. 77
	Stress fractures	Dr. Wolfgang Schaden	p. 82
	<u>Skin</u>		
	ESWT on the skin	Prof. Dr. Karsten Knobloch	p. 90
	ESWT on cellulite	Prof. Dr. Karsten Knobloch	p. 97
	<u>Myofascial pain therapy</u>		
	Myofascial pain therapy	Dr. Hannes Müller-Ehrenberg	p. 102
	<u>Urology</u>		
	ESWT urological diseases	Dr. Hannes Müller-Ehrenberg	p. 108

# 1 Physics and Technology of ESWT

## Physical Basics

The Encyclopedia Britannica online ([www.britannica.com](http://www.britannica.com)) definition of shock wave is "a strong pressure wave in any elastic medium such as air, water, or a solid substance, produced by supersonic aircraft, explosions, lightning, or other phenomena that create violent changes in pressure. Shock waves differ from sound waves in that the wave front, in which compression takes place, is a region of sudden and violent change in stress, density, and temperature. Because of this, shock waves propagate in a manner different from that of ordinary acoustic waves. In particular, shock waves travel faster than sound and their speed increases as the amplitude is raised. Furthermore, the intensity of a shock wave also decreases faster than does that of a sound wave because some of the energy of the shock wave is expended to heat the medium in which it travels. The amplitude of a strong shock wave, as created in air by an explosion, decreases almost as the inverse square of the distance until the wave has become so weak that it obeys the laws of acoustic waves. Shock waves alter the mechanical, electrical, and thermal properties of solids and thus, can be used to study the equation of state (a relation between pressure, temperature, and volume) of any material".

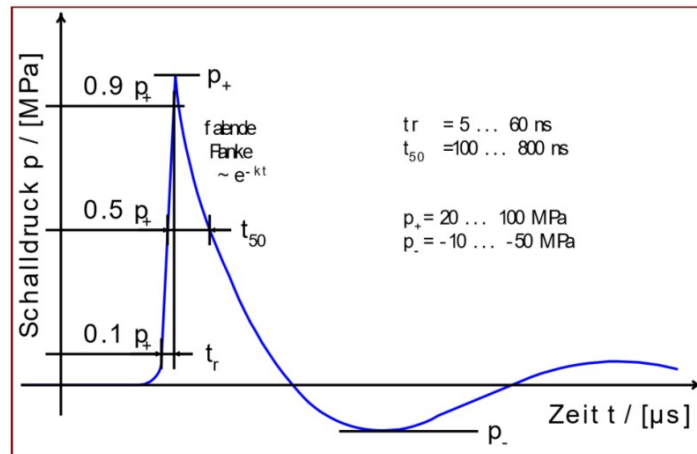
Although shock waves have some characteristics similar to those of other waves, they differ considerably. Here these differences and similarities will be discussed.

## **Characteristic Properties and Parameters of Shock Waves**

The energy of a shock wave is released as pressure on the environment. This pressure is very high, builds up extremely fast and with a classical shock wave the pressure amplitude is mainly positive pressure. The negative part is much weaker and longer and corresponds to the tension wave.

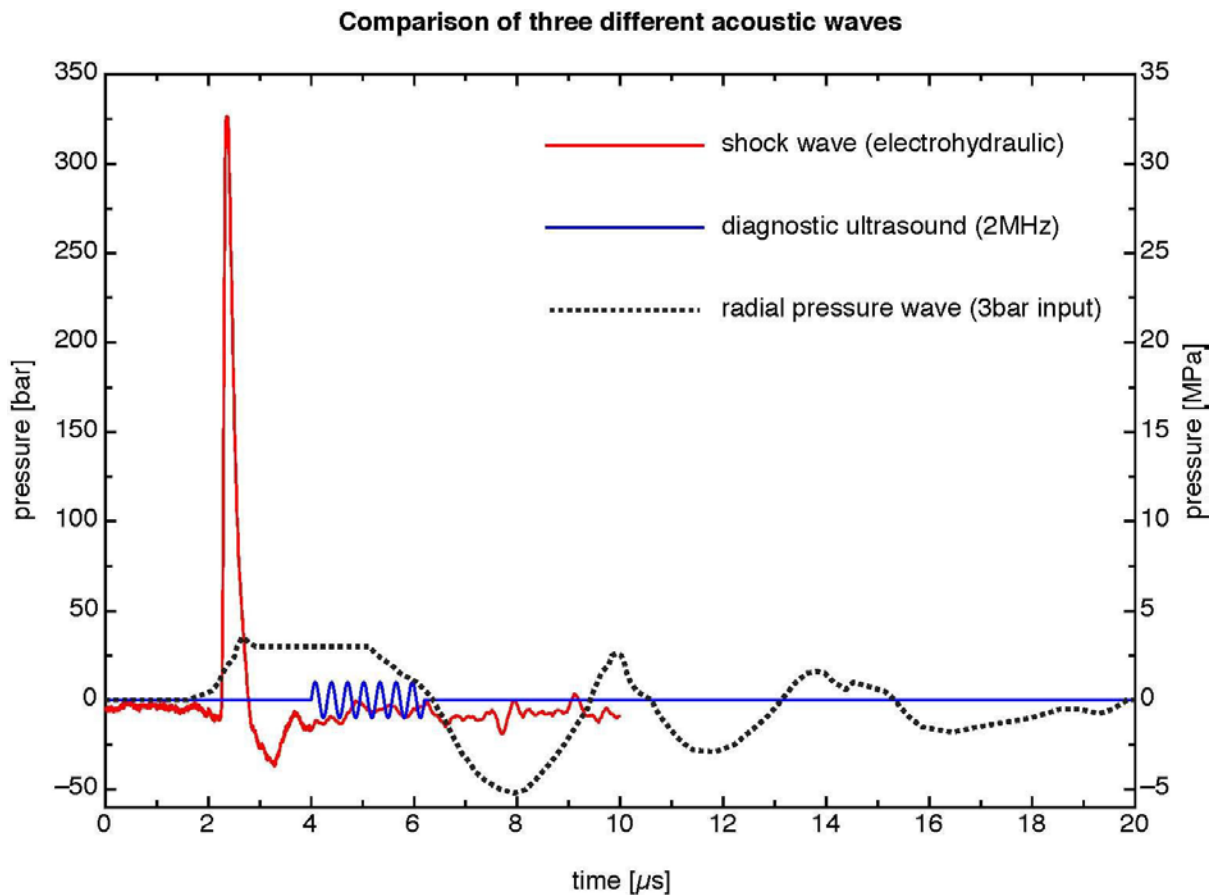
The graphic should show the classical form of a shock wave, the following properties are characteristic:

- Extremely fast rise of the curve
- Very high pressure
- Low negative wave compared to very high peak pressure



Shock waves are mechanical pressure impulses which propagate in the medium in a wave-like manner.

To better illustrate the differences to other wave types, here is a graph showing shock waves, pressure waves and ultrasound in the same coordinates.



Source:  
 electrohydraulic shock wave: MTS Europe GmbH, measurement orthogold100, focused applicator  
 diagnostic ultrasound: sine wave, calculated with 1 MPa peak pressure at 2MHz  
 radial pressure wave: R. O. Cleveland, P. V. Chitnis, and S. R. McClure. Acoustic field of a ballistic shock wave therapy device. *Ultrasound Med Biol*, 33(8):1327–1335, 2007, Figure 6a

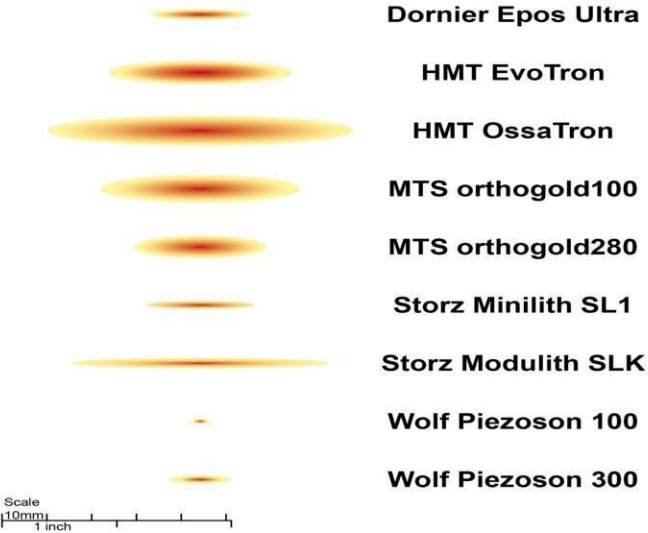
Which parameters of the shock waves are the most suitable to describe the sound fields of the devices used, is not yet completely clear today. Again and again one comes up against limits, because one cannot characterize the applied impulses with one or the other parameter. In accordance with the extracorporeal shock wave lithotripsy in urology (ESWL), the technicians of the manufacturers have especially chosen the EFD (energy flux density), the peak pressure (P) and the total energy (E) in the -6 dB focus. It is now agreed that further parameters should be documented, but the process of determination is not yet complete.

The following list lists the most important parameters currently in use:

Positive pressure	MPa	
-6 dB Focus		mm
5 MPa Focus		mm
Positive energy flux density (EFD+)		mJ/mm <sup>2</sup>
Total energy flux density		mJ/mm <sup>2</sup>
Positive energy in -6dB focus		mJ
Total energy in -6dB focus		mJ
Positive energy in 5 MPa focus		mJ
Total energy in 5 MPa focus		mJ
Positive energy in 5 mm focus		mJ
Total energy in 5 mm focus		mJ

In the graph it can be seen that the size of the focus is obviously very different. Some of these devices are no longer available on the market, so it is pointless to discuss their superiority, which is only noteworthy here that all devices define themselves as high-energy devices.

Focal size at highest setting (-6dB)



Finally, it should be noted here that the documentation must not only include the device used, but also the energy levels applied and the number of impulses in the individual energy levels. This is the only way to retrospectively calculate a value for the total applied energy. On the homepage of the ISMST (International Society for Medical Shockwave Treatment) a

corresponding recommendation is placed, which requires the documentation of the device data and the treatment parameters. This recommendation was developed with the cooperation of DIGEST and applies to all devices equally!

→ <https://www.shockwavetherapy.org/about-eswt/ismst-recommendations/>

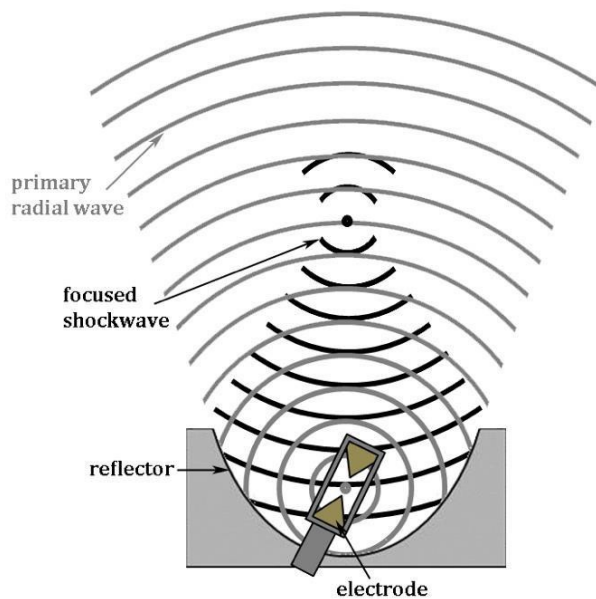
## Generation of Shock Waves

The illustration shows that there are apparently very different devices. These differences are due to the different ways in which shock waves are generated.

The shock waves are generated for medical applications in a therapy head and coupled by means of a usually flexible coupling piece in the form of a membrane or a three-dimensional body. In order to achieve a suitable coupling, it is necessary to introduce a coupling medium such as ultrasonic gel between the interfaces. Otherwise even the smallest air bubbles will interfere with the propagation of the sound. Since any layer of air effectively prevents the propagation of the shock waves.

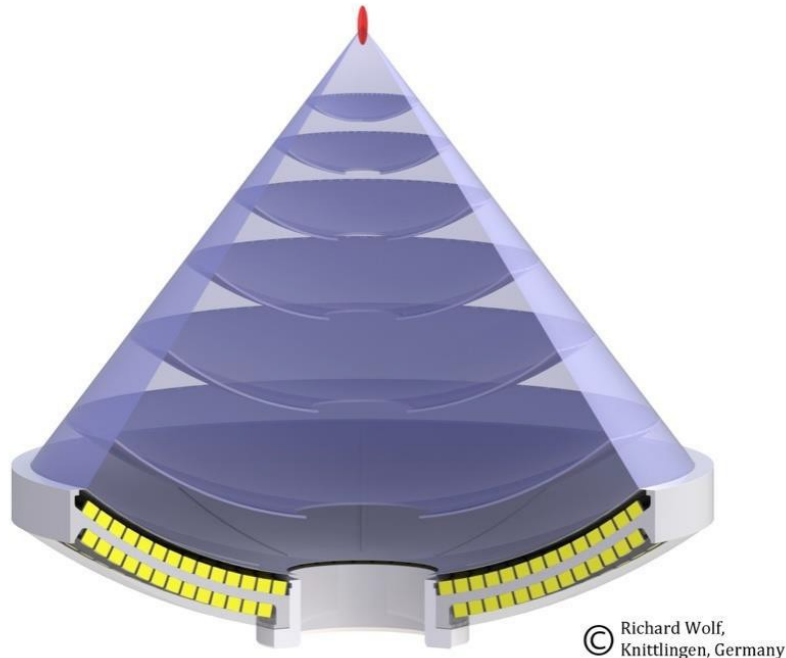
## Electrohydraulic Generation Principle

The oldest principle used in medicine is that in which the shock waves are generated by a spark plug, the electrohydraulic principle. The shock waves propagate in a medium (water) and are also focused in one place by a parabolic mirror.



## Piezoelectric Generation Principle

The piezoelectric principle is based on a focusing of pressure waves, which is produced by the electrical activation of piezoelectric crystals. The piezoelectric crystals are mounted in a shell in such a way that the pressure waves of each crystal meet in a focus.



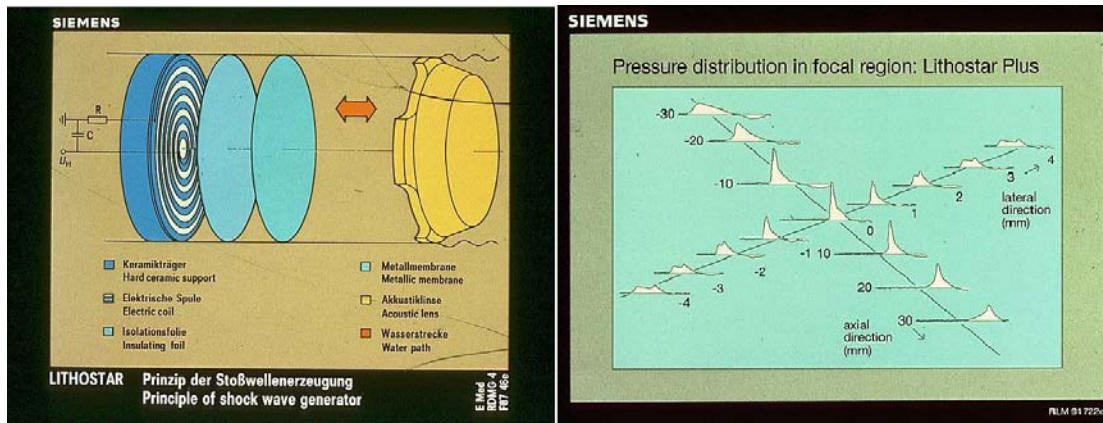
© Richard Wolf,  
Knittlingen, Germany

*Scheme of piezoelectric shock wave generation*

## Electromagnetic Generation Principle

In electromagnetic shock wave generation the shock wave is emitted by a flat coil or a cylindrical coil by electrical pulses. In the flat coil a membrane is deflected which compresses a medium (water). The pulse is focused by means of an acoustic lens. In the cylindrical coil the shock wave is focused by a reflector.

The electromagnetic and piezoelectric systems produce pressure waves that only become shock waves in the focus by summing the energy. The electrohydraulic systems produce shock waves already in focus 1, but in focus 2 the energies are significantly higher.



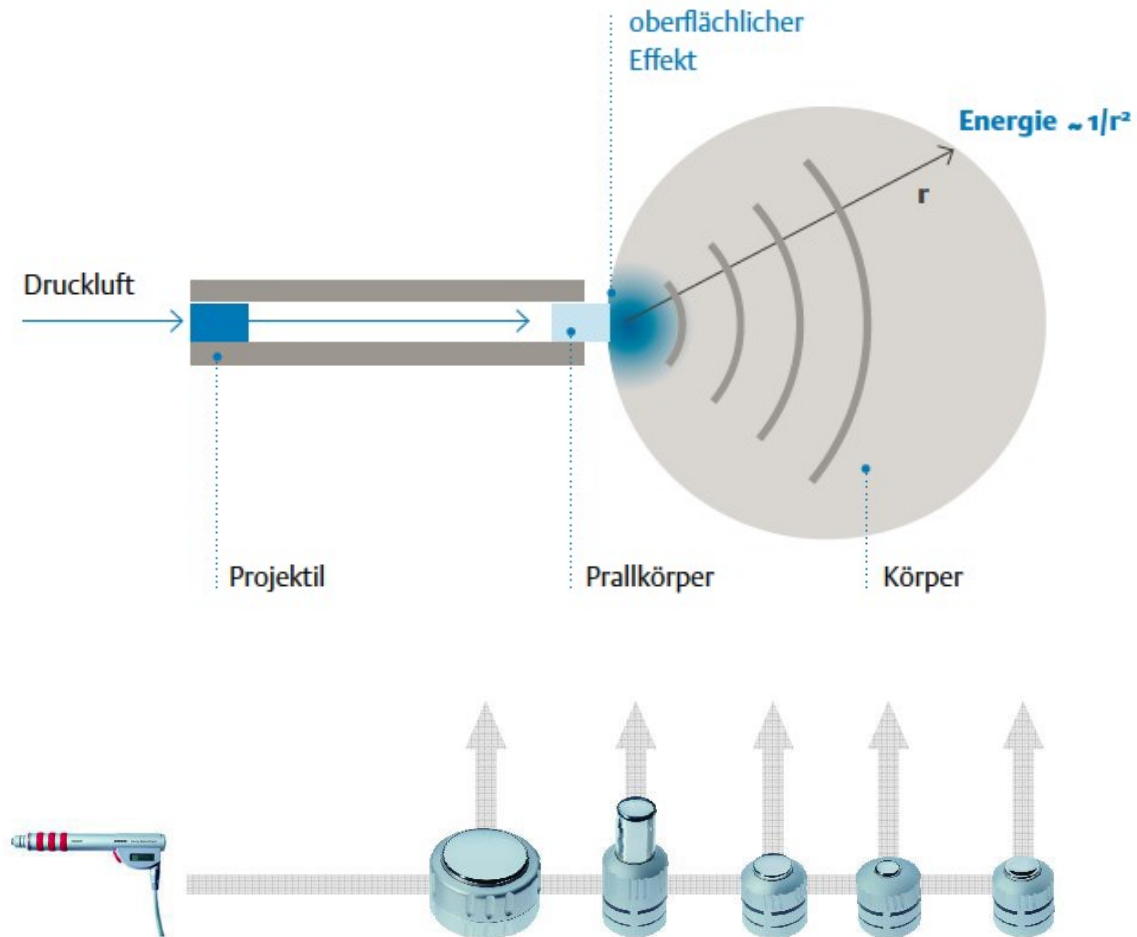
A) The light blue membrane is deflected by the coil, which increases the pressure in the vessel between membrane and lens. The pressure is focused by the lens. B) One sees that only in the center (focus) the waves are divided and summed up in such a way that they get the classical shock wave form, outside the center there are more or less energetic pressure waves.

## Radial or Ballistic Generation Principle

The techniques described in the previous chapters are opposed to the r-ESWT technique. It would be more correct not to speak of shock waves in this technique. However, in medical usage the term radial shock wave therapy has established itself and it is generally accepted that this technique is called so even if other terms are also used; ("radial shock wave therapy", RSWT; "Extracorporeal Pulse Activation Therapy", EPAT; "radial pressure wave therapy").



The generation of radial pressure waves is generated by the collision of a projectile accelerated by compressed air or electromagnetic induction on an impact body (applicator). The projectile has a velocity of approx. 5 to 25 m / s. The impact body is deflected by approximately 0.6 mm by the impact of the projectile. Most of the energy is transferred as a pressure wave into the adjacent medium. The wave propagates radially from the applicator, with the square of the distance the energy decreases.



\*Data origin: EMS Physical Laboratory

The different devices generate sound fields which can differ fundamentally from each other. When the pressure pulses are generated radially, the rapid division of the wave front and the characteristic significantly lower negative and positive deflection of the waves are never discernible, as can be seen in high-energy devices with maximum energy levels.

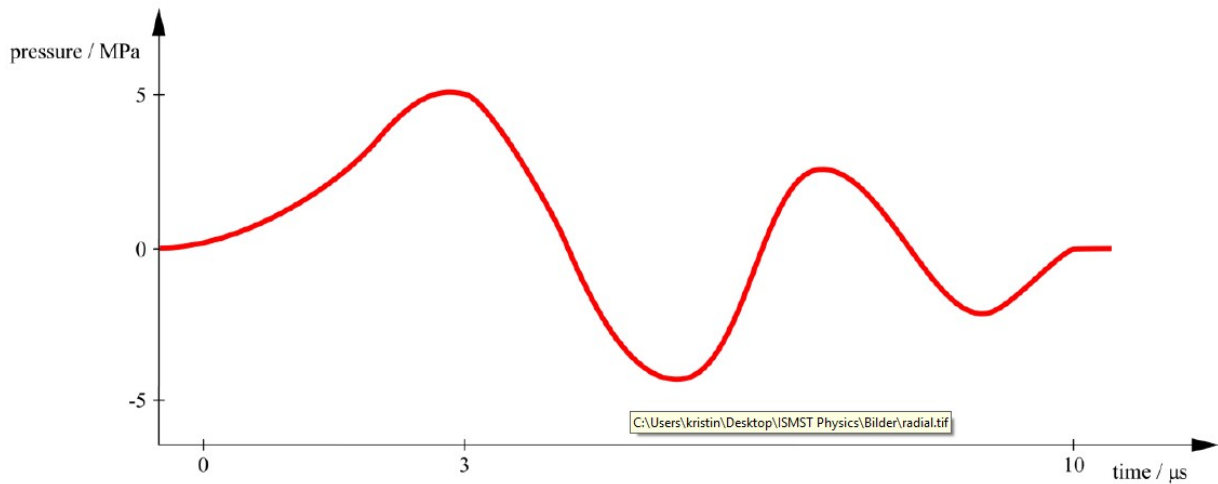


Fig.: Diagram of a pressure wave profile of a radial "shock wave"

The different types of generation of shock waves (including pressure waves) differ in many respects, as is impressively shown in the graph "Comparison of three different acoustic waves" (see chapter Characteristic Properties and Parameters of Shock Waves).

To date, the significance of the various parameters in orthopaedic shock wave therapy is unclear, but it is useful to document those that are known in order to compare the clinical results and perhaps arrive at the ideal physical settings.

It is important to note at this point that the vast majority of treatments in (orthopaedic) indications are performed with more or less energetic pressure waves and not with "classical" shock waves, as shown graphically above. It would be very helpful if the different sound fields could be better characterized with parameters, but we are not there yet.

## Physical Mechanisms of Action

Here different observations are arranged in a way which seems logical for the author. It should be noted in advance that many questions are open.

### *Speed and acoustic impedance of shock waves in different media*

When understanding the effect of shock waves one recognizes the similarity to other waves. Shock waves pass through a medium in a characteristic speed. The speed in the different media is a typical feature for shock waves, exemplarily some are listed here.

Material	Density (kg / m <sup>3</sup> )	Speed of Sound (m / s)	Acoustic Impedance (kg / m <sup>2</sup> s)
Air	1.2	330	16
Water	1000	1437	1.44 x 10 <sup>6</sup>
Fat	970	1480	1.44 x 10 <sup>6</sup>
Muscle	1060	1570	1.66 x 10 <sup>6</sup>
Bones:			
Cortical	1700	3600	6.12 x 10 <sup>6</sup>
Cancellous	1000	1450	1.4 x 10 <sup>6</sup>

**Table 1:** The table shows how differently the properties of the media affect the shock waves. Impedance varies with water content of the tissue.

As with other waves, the energy is released at interfaces, at those places where the waves from one medium meet another medium. The following phenomena occur at the interfaces, which we also know from classical wave theory:

Transmission (transverse wave, longitudinal wave)

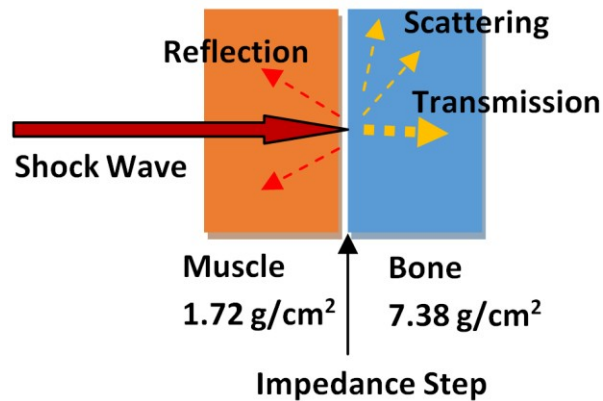
(Partial) reflection

Diffraction and / or deflection, scattering

Wave velocity x density of the medium = acoustic impedance

Pressure / tension wave, shear forces

The higher the impedance jump, i. e. the greater the differences in sound conduction in the adjacent media, the more energy is released at this point. In order to minimise the loss of energy, ultrasound gel or similar is used as the coupling medium; The first treatments were carried out in a bathtub.

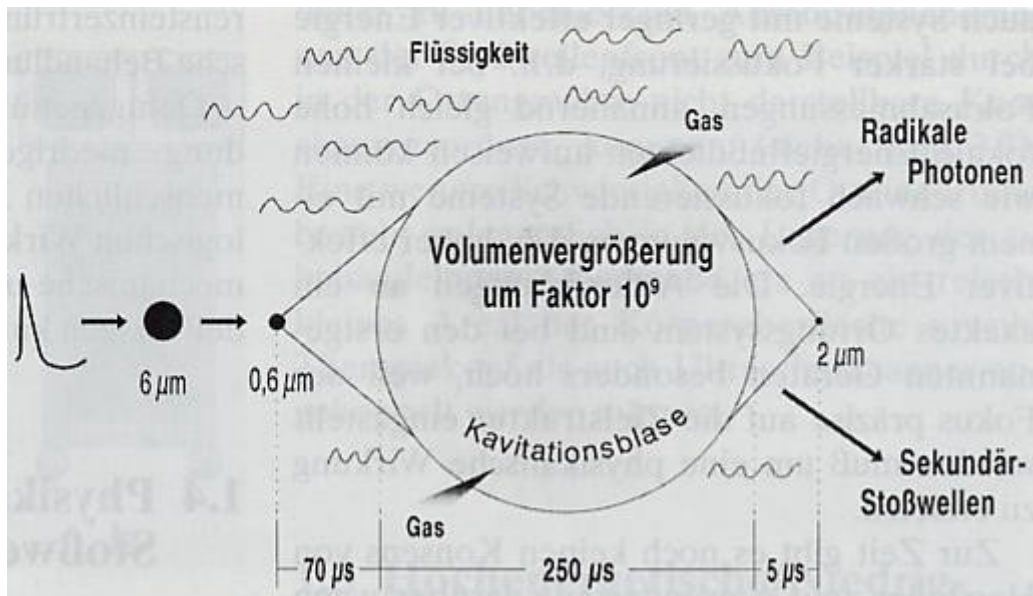


## Cavitation

If one looks at Wikipedia, one reads: "Cavitation (lat. cavitare "hollow out") is the formation and dissolution of vapour-filled cavities (vapour bubbles) in liquids. There are two borderline cases between which there are many transitional forms. In steam cavitation or hard (transient) cavitation, the cavities mainly contain steam from the surrounding liquid. Such cavities collapse under the influence of external pressure by bubble implosion and can generate an intense shock wave (microscopic steam impact). In soft or stable gas cavitation, gases dissolved in the liquid enter the cavities and attenuate or prevent their collapse".

Due to the extreme pressure differences, bubbles form in the medium, the bubbles collapse and the released energy generates further shock waves (jet streams) and photons or free radicals. This phenomenon can be proven in experiments, but today it is not possible to say how necessary cavitation is in order to produce a biological effect.

As described above, there are also bubbles in liquids which are pre-existent but, similar to the hard (transient) cavitation bubbles, change under the influence of a shock wave, causing similar phenomena but only at a much lower level. They are also known as pseudo-cavitation bubbles.



In the following, different effects are described which can be observed in the medium or in the tissue:

- **Direct, mechanical effect or tearing (stone disintegration, bone fissures, tissue tearing)**

The direct, mechanical effect of high-energy shock waves we know from nature; It is the force that leads to the destruction of houses in an earthquake or, as is well known, destroys everything on the coast in a tsunami; Part of the energy of a lightning bolt is also emitted to the environment as a shock wave, which can be heard as thunder further away and can have a destructive effect. The bang of an airplane when breaking through the speed of sound is also a shock wave.

In medicine, we use the destructive effect of shock waves to disintegrate concretions (kidney stones, bladders, ureter stones, gallstones or saliva stones).

At very high shock wave energies, the connective tissue parts of the body such as skin, muscles, lungs, parenchymatous organs or blood vessels can also rupture. This effect is not sought in orthopaedics, which is why such high energies are not used in orthopaedics.

The effect occurs at sites of high impedance jumps of different tissues that are penetrated by the shock wave, i. e. at the interfaces of different tissues and structures embedded in the tissue.

The shattering, destructive effect is only aimed at in urology today (or surgery). In the stimulation of non-healing or poorly healing bone fractures, so-called pseudoarthrosis or delayed bone fracture healing, it was also discussed whether the shattering or fracture of the bony structures leads to healing, but as we know from recent studies, one can assume that disintegration is not needed in orthopedics.

If the shock wave energy would be selected accordingly high, one could observe the destructive effects. In animal experiments, these effects of high shock wave energies on tendons have been impressively demonstrated. Within the framework of an animal experiment, for bone examinations, bone fragments ("bone embolism") could even be found by chance in the lungs of the experimental animal. We are therefore really careful not to produce any damaging effect of ESWT.

With the same idea of disintegration (comminution), the treatment of calcium deposits on the shoulder was started in Hamburg at the beginning of the 1990s. However, it is also known in the case of calcium treatment that it is not the disintegrative effects that lead to healing, but rather molecular biological changes in the treated tissue (see below).

- **Thermal and chemical effects**

The significance of this ESWT effect is unclear. Thermal and chemical effects are detectable but their influence on tissue changes is unclear. Probably these effects have a much greater significance in very high energy shock waves. The thermal effects are similar to those of ultrasound but shock waves are emitted at such a low frequency in orthopedic applications that the thermal effects appear negligible.

- **Biological effects of shock waves**

Much of what is described here is still little researched today. One should go so far and even write that the biological mechanisms of action described here are largely hypotheses, but there are some publications that give rise to the following analyses.

A cascade of reactions to the mechanical stimulus of the shock wave is most likely to be triggered:

- **Mechanotransduction**

The "vibration" of the tissue by the shock waves is a mechanotransduction, a transformation of a mechanical stimulus on the tissue. Mechanical energy is transferred to the cell by altering the cytoskeleton and extracellular molecules connected to the cytoskeleton. It is probable that stimulus transmission occurs particularly in the cell nucleus, but also in other cellular structures (endoplasmic reticulum, mitochondria, etc.).

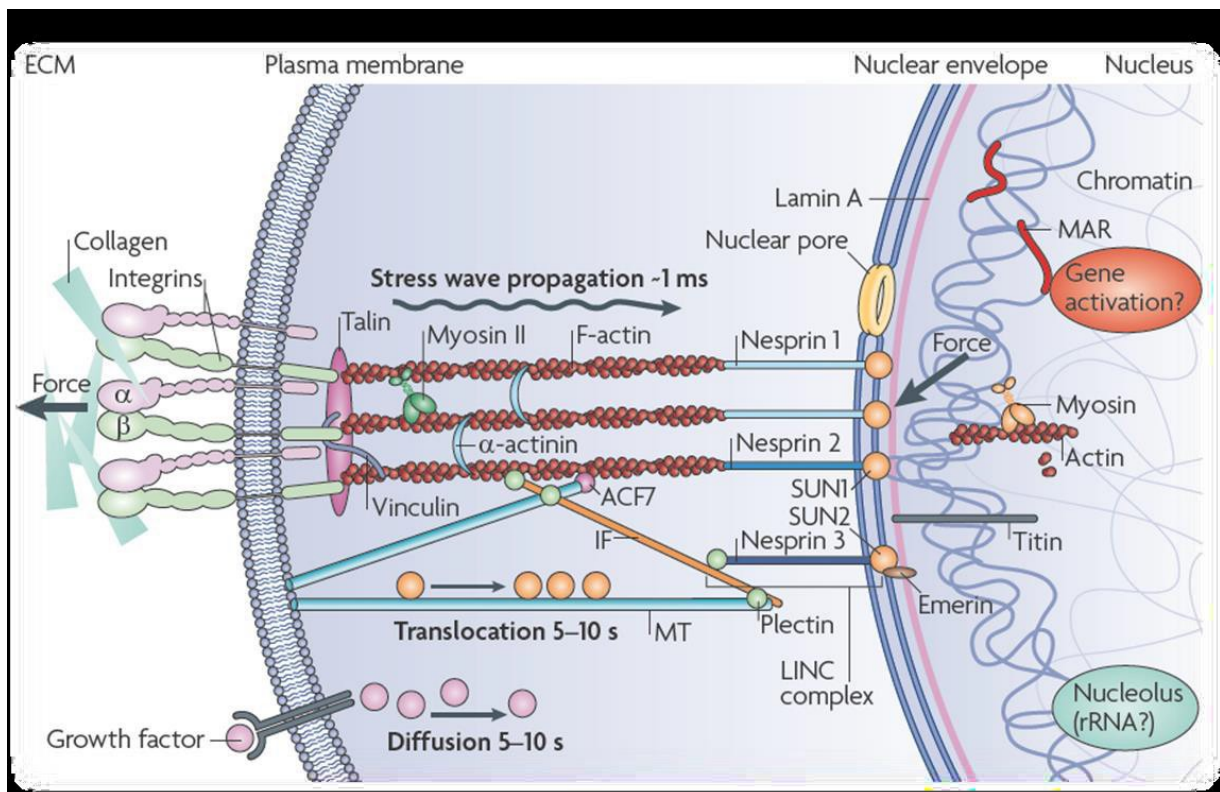
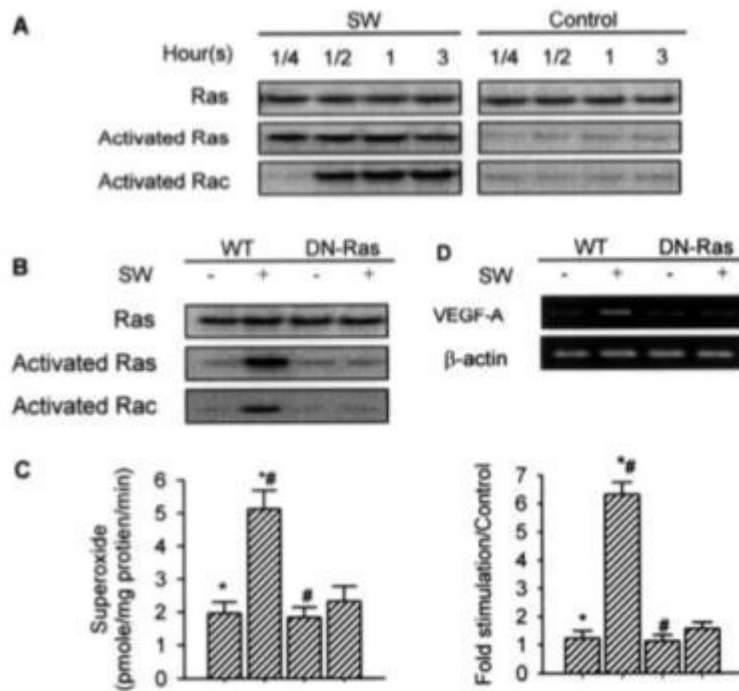


Illustration of mechanotransduction by Wang, Tytell, Ingber (Nature Rev 2009)

- **Gene expression:**

The stimulation of the cell nucleus via the excited cytoskeleton might result in gene expression. In any case, Wang et al. 2004 have shown that ESWT stimulates the RAS system in rats and that, for example, m-RNA is released for VEGF, a performance that is only achieved in the cell nucleus.





**FIG. 4. Ras and Rac activation in SW-treated osteoblasts.** SW activated Ras protein in 15 min and Rac protein in 30 min. Cell cultures with and without SW treatment were subjected to immunoprecipitation and immunoblotting (A). Transfection of dominant negative Ras mutant suppressed SW-enhanced Ras and Rac activation in 15 and 30 min, respectively (B). Dominant negative Ras mutant reduced SW-induced superoxide production in 30 min. \* ( $p < 0.001$ ) and # ( $p < 0.001$ ) represent a significant difference between two groups (C). Dominant negative Ras mutant abrogated SW-enhanced VEGF-A mRNA expression in 12 h. After standardization of housekeeping gene expression, equal amounts of cDNA from each sample were subjected to 40 cycles of PCR to amplify VEGF-A expression. \* ( $p < 0.001$ ) and # ( $p < 0.001$ ) indicate a significant difference between two groups (D). Results are presented with mean values  $\pm$  S.E. calculated from six paired triplicate experiments.

Wang et al. (2004 J.BiolChemistry): Ras Induction of Superoxide Activates ERK-dependent Angiogenic Transcription Factor HIF-1 and VEGF-A Expression in ShockWave-stimulated Osteoblasts

### • Enzymatic tissue response

Analogous to gene therapy, a tissue response is found that can also be measured by different enzyme changes. As with gene therapy, enzymatic changes can be observed long after gene therapy or gene expression.

In animal experiments (rats, rabbits, dogs) changes of the following substances could be found by shock wave effect:

- Nitric oxide (NO)
- Prostaglandin E2
- COX-2
- Substance P



- PGP (phosphoglycolate phosphatase)
- CGRP (calcitonin gene related peptide)
- eNOS (endothelial nitric oxide synthetase)
- VEGF (vessel endothelial growth factor)
- PCNA (proliferating cell antinuclear antigen)
- Signal-regulated kinase (ERK)
- p38 kinase

The formation of heat shock proteins was also found in connection with NO.

Animal experiments are not transferable 1 : 1 to humans. The list of the many substances that were successfully tested in animal experiments should show that obviously extremely complex changes in tissue are induced by shock waves.

- **Macroscopically recognizable healing**

The healing of the tissue is a process that takes months and can therefore be detected late macroscopically and microscopically.

Today, we assume that neovascularisation plays a central role in the healing of ESWT-treated areas (formation of new blood vessels).

In addition, changes in the nerve cells can also be detected, which would explain a change in pain after ESWT (reduction in the number of non-myelinated nerve fibres by ESWT). In the last 5 years, there has been a flood of basic ESWT knowledge which, piece by piece, represents an interesting counterpart to the clinical research results.

- **Hyperstimulation analgesia (gate-control mechanism)**

The importance of this ESWT effect has never been confirmed by animal testing and is now considered to be an unlikely hypothesis:

Repeated nerve irritation can cause a change in pain processing in the spinal cord or central nervous system (gate-control). In the past, it was thought that such a "gate-control mechanism" would lead to pain relief (according to Melzak). Today, the molecular biological changes described above are much more likely.

## ***Contraindications and adverse effects of ESWT***

The following list shows the contraindications for which ESWT is not performed:

- Epiphyseal plate in focus
- Coagulopathy (high-energy ESWT is associated with a risk of bleeding, also with marcumarization)
- Acute infection (the chronic infection was dropped as a contraindication)
- Lung in focus
- Brain or nerve in focus
- Pregnancy
- Malignant tumor in focus

There is no definite evidence of persistent complications from ESWT, but there have been tendon ruptures after ESWT, for example, and ESWT has been accused of this. Rompe and Maier had carried out impressive experiments with tendons, which showed that at energies  $> 0.6 \text{ mJ} / \text{mm}^2$  such tendons suffer damages. The tendon ruptures described have always occurred after repeated cortisone infiltrations, so ESWT should therefore rather not be able to prevent the rupture any more than it was the cause of it.

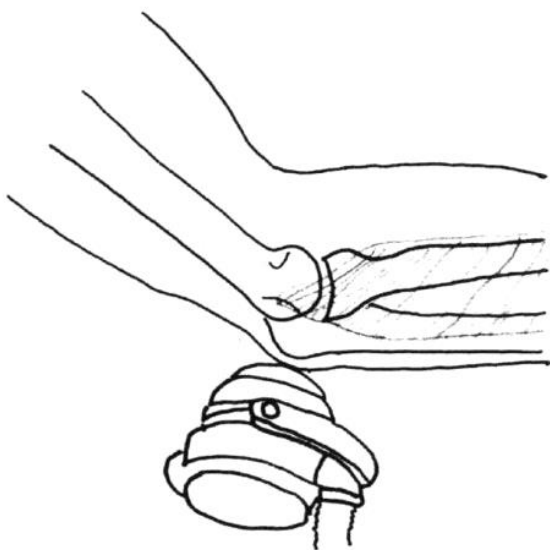
Among other things, pain (including headaches - migraines), redness of the skin (blistering) and bruising (haematomas) can usually occur during and after treatment. Tendon loosening (edemas, occasionally also tendon tears) were observed after the treatment. Complications not previously known may also occur.

### **Procedure of shock wave treatment:**

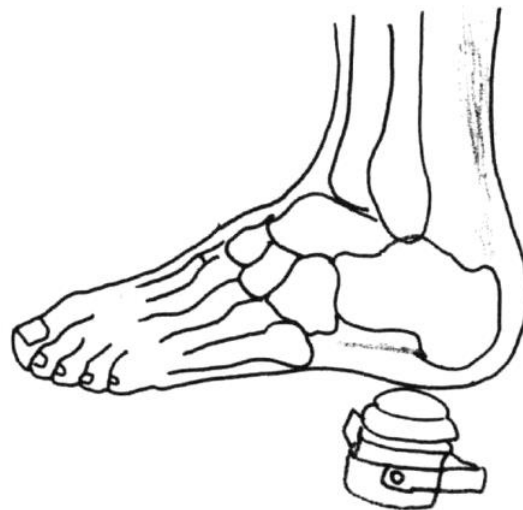- ⇒ Other treatment options (immobilization, splints, bandages, tape bandages, cold, heat, electricity, ultrasound, stretching and physiotherapy exercises, medication as ointment, for ingestion or infiltration, acupuncture, alternative methods, surgery, ...) are explained before ESWT.
- ⇒ Patients give their written consent to the ESWT.
- ⇒ The treatment is carried out by the doctor!
- ⇒ The treatment is painful! Nevertheless, pain anesthesia (anesthesia or local anesthesia) is usually not necessary for the treatment.
- ⇒ The shock waves are introduced with an applicator (with contact gel) through the skin. The adjustment is made before and during the treatment by means of a clinical examination and pain description of the patient (feedback), ultrasound, X-ray or laser. A fixed position is important, an interruption of the treatment e. g. with pain is at any time possible. Usually 1000 - 3000 single shocks (1 - 5 impulses per second) are applied during one treatment, with small wounds at least 500 impulses per treatment. The duration of treatment is about 10 - 60 minutes.

- ⇒ Depending on the disease, one or more treatments are necessary (see also the chapter where the indications are described). The treatment data are recorded precisely.
- ⇒ As post-treatment, medication (painkillers) may be recommended, further immobilization (plaster, fixator, ...) with relief and corresponding additional thrombosis prevention in the case of bone fracture treatment, controls should be agreed after ESWT.

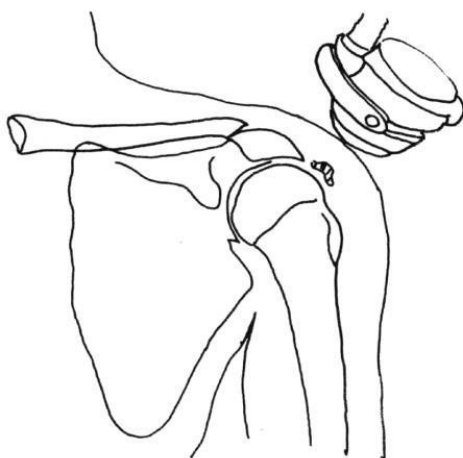
The chances of success are indicated differently in the literature, a listing and exact discussion of the same goes beyond the scope here. In this respect every user should deal with the recent literature or keep up to date.



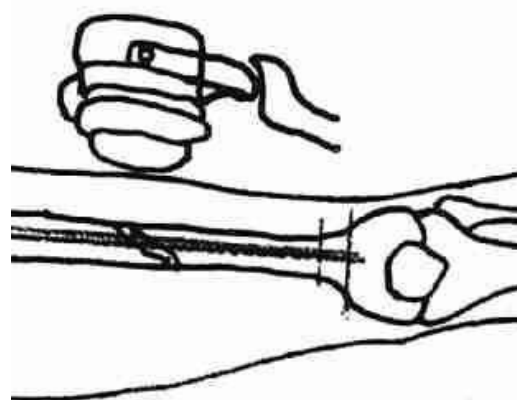
1: ESWT at the elbow in epicondylitis humeri lateralis



2: ESWT in plantar fasciitis with / without heel spur



3: ESWT on the shoulder at Tend.calc.



4: ESWT in pseudoarthrosis

## 2 Practical Application

### **Tendinosis calcarea**

Prof. Dr. Ludger Gerdesmeyer

**ICD-10:** M-75.3

#### **Synonyms**

Kalkschulter, Tendinitis calcarea, calcifying tendinitis, calcific lesion

#### **Key words**

Painful shoulder, shoulder joint, rotator cuff, calcium deposit, calcium shoulder, shock wave therapy, ESWT

#### **Definition**

Rotator cuff calcification as a consequence of dystrophic tendon disease with optional chondroid metaplasia.

#### **Aetiology**

The tendinosis calcarea of the rotator cuff is a common cause of shoulder pain. Data on the incidence of the disease show a considerable range of variation. It is given with 2.5 % to 20 %. It is usually a self-limiting disease with high spontaneous healing rates. In a clinically symptomatic calcific shoulder with calcific deposits with radiologically sharp edges and a homogeneous or inhomogeneous structure (type Gärtner 3 and 2), spontaneous resorption occurs within 3 years in 33 % of cases. The spontaneous resolution rate is considerably higher for calcium deposits with soft edges and inhomogeneous X-ray structure (type Gärtner 3) with up to 85 %. Within one year, 6.4 % of asymptomatic calcific shoulders are spontaneously resorbed. There is no data for a chronic and conservatively unsuccessfully treated tendinosis calcarea. There is no reliable correlation between tendinosis calcarea and rotator cuff lesions. A bilateral occurrence is observed between 9 % - 40 % of cases. The supraspinatus tendon is affected in 82 % - 94.5 % of cases. The classical calcium deposit is located in the hypovascular zone, approx. 1.5 cm proximal to the attachment zone.

#### **Pathogenesis**

A distinction is made between an acute phase and a chronic phase. The acute phase suddenly begins with severe pain over a period of 2 - 3 weeks with swelling, overheating and clear pain at night and at rest. Then the pain gradually subsides until it is completely free of symptoms. Residual pain can persist for months (post calcification tendinitis).

Macroscopically, a pasty milky emulsion is found which mineralogically consists of poorly crystallised carbonate apatite. The crystals are formed in the tendon or resorbed after breakthrough into the bursa subacromialis / subdeltoidea (resorption stage). The chronic phase of tendinosis calcarea is characterized by slowly increasing pain. The self-limiting cyclic course of the disease, which leads from a pre-calcification phase into the calcification phase

and finally into a post-calcification phase, is interrupted. Chronic patients are in the calcification phase for years. Mechanical, vascular and biochemical factors are discussed as possible causes of calcification.

Local pressure increases lead to reduced blood flow and hypoxia of the tendon tissue with degeneration of the tendon cells and dystrophic calcification.

### Classification

The classification is based on size on the one hand and radiological criteria on the other. The classification according to Gardner has established itself.

Classification according to Gärtner	
Grade I	Sharp edges, homogeneous structure, radiopaque
Grade II	Sharp edges, inhomogeneous structure, less radiopaque
Grade III	Fuzzy edges, inhomogeneous structure, less radiopaque

### Medical key systems

ICD10

M75.3 Tendinitis calcarea in the shoulder area

S46.0 Injury to a tendon of the rotator cuff

S46.7 Injury to several muscles and tendons at shoulder and upper arm level

### Anamnesis

Special anamnesis

Disease duration

Accident anamnesis

Direct, indirect impact of violence, pseudoparalysis

Pain

Localisation, radiation, painful movement restriction, night rest pain

Functional restriction mobility

Functional handles

General diseases and risk factors

Skeletal or connective tissue diseases

Metabolic diseases

Pre-treatments

## **Diagnosics**

### **Clinical diagnostic**

Inspection: Muscle relief, symmetry, skin redness

Palpation: Palpable resistance in the area of the attachment zone of the rotator cuff

Findings:

Extent of movement (active and passive)

Pain caused by movement

Specific positive tests for differential diagnosis, rotator cuff rupture and subacromial impingement (drop arm sign), jobe test, patte test, palm-up test, O'Brian test, lift off test, Neer's Matsen's Hawkins's impingement signs

Assessment of blood circulation, motor skills and sensitivity

### **Apparative diagnostics**

Sonography of the shoulder

X-ray of the shoulder in 3 planes

y-view image according to Neer

### **Optional investigation**

MR

X-ray of adjacent joints (e. g. cervical spine)

Clinical chemistry laboratory

### **Differential diagnoses**

Impingement syndrome (mechanical outlet, secondary or functional impingement)

Frozen shoulder

Vertebragene, vascular, neurovascular shoulder pain

Neuralgic shoulder amyotrophy

Rotator cuff lesions

Gout arthropathy

Clinical scores

Constant score

### **Therapy**

Myofascial shoulder pain

### **Objectives**

Pain relief and restoration of shoulder function

Induction of calcium depot resorption

### **Therapeutic principle**

Treatment of tendinosis calcarea of the shoulder can be conservative or surgical.

Conservative treatments must be carried out before surgical procedures are performed.

Shock wave therapy is a method of first choice.

### **Conservative therapy**

Systemic NSAR

Systemic analgesics

Local infiltration

Infiltration with PRP (Platelet Riched Plasma)

Passive movement exercises

Active muscle strengthening for depression and centering of the humeral head

Ergotherapy

Medical training therapy

### **Surgical therapy**

Sonographically or radiologically controlled needling of the calcium deposit

Arthroscopic resection

Open resection

### **Shock wave therapy**

**Indication:** Indication by the expert physician.

**Contraindication:** Malignant tumor in focus, osteomyelitis.

**Room requirements:** Certification criteria of a medical practice e. g. hygiene plan, emergency management available according to DIN standard.

**Patient preparation:** Differentiated and documented education and information (onset of effect after weeks). Explicit information about the risk of tendon rupture in the case of previous damage and premature sports exertion after treatment.

**Doctor and assistant staff:** ESWT is a service to be provided personally by a doctor qualified by means of specialist knowledge.

**Implementation of the therapy:** For the treatment of tendinosis calcarea, high-energy treatment with focused shock wave is used.

#### **Documentation:**

Designation of the shock wave source and the parameters used.

#### **Localisation:**

The treatment is controlled by imaging procedures (X-ray or ultrasound). The treatment target area is the calcium depot.

- Focused ESWT:

The mean energy flux density of the shock waves should be between 0.18 and 0.32 mJ / mm<sup>2</sup>. Up to 5 treatment sessions are performed with an interval between 1 - 2 weeks. Between 1500 and 2000 shock waves with a frequency of up to 5 Hz are applied per treatment session.

**Complications:**

Possible complications are: Haematoma discoloration, petchial skin bleeding, temporary pain enhancement, vascular injury, nerve injury.

**Literature:**

Bosworth B. Calcium deposits in the shoulder and subacromial bursitis: a survey of 12122 shoulders. JAMA 1941;116:2477-2489

Uthoff HK, Loehr JF. Calcifying tendinitis. In: Rockwood CA, Matsen FA (eds): The shoulder. Saunders, Philadelphia (1998), 989-1008

Harmon PH. Methods and results in the treatment of 2580 painful shoulders with special reference to calcific tendinitis and the frozen shoulder. Am J Surg 1958;95:527-544

Gärtner J. Tendinosis calcarea - Behandlungsergebnisse mit dem Needling. Z Orthop Ihre Grenzgeb 1993;131:461-469

Rompe JD, Buch M, Gerdesmeyer L, Haake M, Loew M, Maier M, Heine J. Muskuloskeletale Stosswellenapplikation - Aktueller Stand der klinischen Forschung zu den Standardindikationen. Z Orthop Ihre Grenzgeb 2002;140:267-274

Green S, Buchbinder R, Glazier R, Forbes A. Systematic review of randomised controlled trials of interventions for painful shoulder: selection criteria, outcome assessment, and efficacy. BMJ 1998;316:354-360

Rochwerger A, Franceschi JP, Viton JM. Surgical management of calcific tendinitis of the shoulder: an analysis of 26 cases. Clin Rheumatol 1999;18:313-316

Loew M, Daecke W, Kusnierczak D, Rahmizadeh M, Ewerbeck V. Extracorporeal shockwave application - an effective treatment for patients with chronic and therapy-resistant calcifying tendinitis? J Bone Joint Surg 1999;81-B:863-867

Constant CR, Murley AHG. A clinical method of functional assessment of the shoulder. Clin Orthop 1987;214:160-164

Rompe JD, Zoellner J, Nafe B. Bedeutung der Kalkdepotelimination bei Tendinosis calcarea der Schulter. Z Orthop Ihre Grenzgeb 2000;138:335-339



DaeckeW,KusnierczakD, LoewM: Importance of extra corporeal shockwave therapy(ESWT)in chronic calcific tendinitis of the shoulder.Orthopade 2002;-31:645–651

GerdesmeyerL,WagenpfeilS,HaakeM,MaierM,LoewM,WörtlerK,LampeR,Seil R,HandleG, GasselS,RompeJD:Extracorporeal shockwave therapy fo rthe treatment of chronic calcifying tendonitis of the rotatorcuff—a randomized controlled trial.JAMA(2003);290:2573-258

## **Radial epicondylopathy**

Sergej Thiele

### **Classification**

M77.1ICD10

### **Synonyms**

Radial: Tennis elbow / arm, epicondylitis, mouse elbow / arm

### **Aetiology**

Chronic overstrain / misstrain, training error

Irritation of the tendinous origin of the extensors at the epicondylus humeri radialis

Degenerative changes

Structural lesion

### **Symptoms**

Local pressure pain, functional pain

Positive provocation tests, changing intensity mostly one-sided

Typically localized at the common origin of extensors

Occasional radiation distally

### **Apparative diagnostics**

Ultrasound

X-Ray

MRT

### **Differential diagnosis**

Supinatorogen syndrome

Compartment syndrome

Systemic diseases

Osteomyelitis

Arthrosis

Cervicobrachialgia

Myofascial pain of the upper limb

### **Conservative therapy**

Physiotherapy and independent exercises

Orthoses

Infiltration

NSAID

Physical measures

Acupuncture

X-ray irradiation

Immobilization / relief

## **Surgical therapy**

Various surgical procedures (e. g. tendon notch denervation) (open / endoscopic)

## **Shock wave therapy**

**Indication:** Therapy-resistant symptoms, indication by the expert physician.

**Contraindication:** Focus on malignant tumor.

**Room requirements:** Certification criteria of a medical practice e. g. hygiene plan, emergency management available according to DIN standard.

**Preparation of the patient:** Differentiated and documented education and information (onset of effect after weeks).

**Doctor and assistant staff:** ESWT is a service to be provided personally by a doctor qualified by means of specialist knowledge.

**Implementation of the therapy:** No local anaesthesia, cryotherapy if necessary.

**Documentation:** Designation of the shock wave source and the parameters used.

**Localisation:** Patient-oriented focusing.

**Coupling medium:** Ultrasound gel.

### Electrohydraulic:

0.015 - 0.22 mJ / mm<sup>2</sup>, single session

1500 pulses / session

Frequency 4 Hz

### Electromagnetic:

0.09 / 0.14 - 1.2 mJ / mm<sup>2</sup>, 3 sessions

2000 pulses / session

Frequency 4 - 5 Hz

### Radial:

1.4 - 2.5 bar, 3 sessions

Frequency up to 8 Hz

2000 pulses / session

**After the therapy:** If necessary monitoring of the circulatory function.

**Complications:** Haematomas, pain enhancement, nerve irritation.

**Follow-up treatment:**

Avoidance of potential triggers

Sports leave for 4 weeks (individual sports adaptation)

Continuation of stretching exercises

Clinical success control after 8 - 12 weeks

**Literature:**

RompeJD, HopfC, KullmerK et al.(1996) Analgesic effects of extracorporeal shock wave therapy on chronic tennis elbow. *J BoneJointSurg*,78-B,233– 237.

CrowtherA, BannisterGC,HumaHetal.(2002) A prospective study to compare extracorporeal shockwave therapy and injection of steroid for the treatment of tennis elbow.*JBJS*,84-B,678–679.

Haake, M., Konig, I. R., Decker, T., Riedel, C., Buch, M., and Muller, H.-H. Extracorporeal shock wave therapy in the treatment of lateral epicondylitis: a randomized multicenter trial. *J Bone Joint Surg Am* 84-A, 11 (2002), 1982–1991.

SpeedC, NicholsD, RichardsCet al.(2002)Extracorporeal shockwave therapy for lateral epicondylitis: a double blind randomized controlled trial.*J OrthopRes*,20,895 898.

Mehra, A., Zaman, T., and Jenkin, A. I. R. The use of a mobile lithotripter in the treatment of tennis elbow and plantar fasciitis. *Surgeon* 1, 5 (Oct 2003), 290–2.

MelikyanEY, ShahinE, MilesK et al.(2003) Extracorporeal shockwave therapy for tenniselbow. A randomized double-blind study.*JBJS*,85-B,852–855.

RompeJD, DeckingJ, Schoellner C etal.(2004) Repetitive low energy shock wave treatment for chronic lateral epicondylitis in tennis players.*AmJSportsMed*,32,734 743.

Buchbinder, R., Green, S. E., Youd, J. M., Assendelft, W. J. J., Barnsley, L., and Smidt, N. Shock wave therapy for lateral elbow pain. *Cochrane Database Syst Rev*, 4 (2005), CD003524.

Lebrun, C. M. Low-dose extracorporeal shock wave therapy for previously untreated lateral epicondylitis. *Clin J Sport Med* 15, 5 (2005), 401–402.

Chung B, Wiley JP, Rose MS. (2005): Long-term effectiveness of extracorporeal shockwave therapy in the treatment of previously untreated lateral epicondylitis. *Clin J Sport Med.* 2005 Sep;15(5):305-1

Pettrone F, McCall B (2005) Extracorporeal shockwave therapy without local anaesthesia for chronic lateral epicondylitis. *JBS, 87-A, 1297–1304.*

Spacca G, Necozone S, Cacchio A (2005) Radial shockwave therapy for lateral epicondylitis: a prospective randomised controlled single-blind study. *Eur Med Phys, 41, 17–25.*

Radwan, Y., Elsobhi, G., Badawy, W., Reda, A., and Khalid, S. Resistant tennis elbow: shock-wave therapy versus percutaneous tenotomy. *Int Orthop 32, 5 (2008), 671–7.*

Staples MP, Forbes A, Ptasznik R, Gordon J, Buchbinder R (2008): A randomized controlled trial of extracorporeal shockwave therapy for lateral epicondylitis (tennis elbow). *J Rheumatology, 2008;35:10;2038-46*

Ozturan, K. E., Yucel, I., Cakici, H., Guven, M., and Sungur, I. Autologous blood and corticosteroid injection and extracorporeal shock wave therapy in the treatment of lateral epicondylitis. *Orthopedics 33, 2 (Feb 2010), 84–91.*

Vural M, Diracoglu D, Erhan B, Gunduz B, Ozhan G, Pekedis K. Efficacy of extracorporeal shock wave therapy and ultra-sound treatment in lateral epicondylitis: A prospective, randomized, controlled trial. *Annals of Physical and Rehabilitation Medicine.* 2014;57: e190.

Thiele S, Thiele R, Gerdesmeyer L. (2015): Lateral epicondylitis: This is still a main indication for extracorporeal shockwave therapy. *Int J Surg.* 2015 Dec;24(Pt B):165-70. doi: 10.1016/j.ijsu.2015.09.034. Epub 2015 Oct 9. Review.

Vulpiani MC, Nusca SM, Vetrano M, Serena Ovidi S, Baldini R, Piermattei C, Ferretti A, Saraceni VM (2015): Extracorporeal shock wave therapy vs cryoultrasound therapy in the treatment of chronic lateral epicondylitis. One year follow up study. *Muscles, Ligaments and Tendons Journal* 2015;5 (3):167-174

Taheri P, Emadi M, Poorghasemian J. (2017): Comparison the Effect of Extra Corporeal Shockwave Therapy with Low Dosage Versus High Dosage in Treatment of the Patients with Lateral Epicondylitis. *Adv Biomed Res.* 2017 May 29; 6:61. doi: 10.4103/2277-9175.207148. eCollection 2017

Wong CW, Ng EY, Fung PW, Mok KM, Yung PS, Chan KM (2016): Comparison of treatment effects on lateral epicondylitis between acupuncture and extracorporeal shockwave therapy. *Asia Pac J Sports Med Arthrosc Rehabil Technol.* 2016 Nov 24; 7:21-26. doi: 10.1016/j.asmart.2016.10.001. eCollection 2017 Jan.

## **Ulnare epicondylopathy**

Sergej Thiele

### **Classification**

M77.0ICD10

### **Synonyms**

Golf arm, golf elbow, epicondylitis humeri ulnaris

### **Aetiology**

Mechanical overstrain

Micro lesions of tendon insertions

Chronic overload / misstrain

Training error

Irritation of the tendon origin of the flexors at the epicondylus humeri ulnaris

Degenerative changes

Structural lesion

### **Symptoms**

Local pressure pain, functional pain at wrist flexion, fist closure and lifting

Positive provocation tests

Alternating intensity

Typically localized at the origin of the flexor tendons at the epicondylus humeri ulnaris

Occasional distal radiation

**Anamnesis** with inclusion of the treatment performed.

### **Apparative diagnostics**

Ultrasound

MRT

### **Differential diagnosis**

Sulcus ulnaris syndrome (if necessary accompanying)

Bursitis

Systemic diseases osteomyelitis

Osteoarthritis

Cervical spine syndrome

### **Conservative therapy**

Stretching, gymnastics, own training

Orthoses

Infiltrations

PRP

NSAR

Physical therapy

Immobilization, relief

### **Surgical therapy**

Various surgical procedures (tendon notch denervation)

### **Shock wave therapy:**

**Indication:** Therapy-resistant symptoms, indication by the expert physician.

**Contraindication:** Focus on malignant tumor.

**Room requirements:** Certification criteria of a medical practice e. g. hygiene plan, emergency management available according to DIN standard.

**Patient preparation:** Differentiated and documented education and information (onset of effect after weeks).

**Physician and assistant personnel:** ESWT is a service to be provided personally by a physician qualified by means of specialist knowledge.

**Implementation of the therapy:** No local anaesthesia, cryotherapy if necessary.

#### **Electrohydraulic:**

0.015 - 0.22 mJ / mm<sup>2</sup> single-session,

1500 pulses / session

Frequency 4 Hz

#### **Electromagnetic:**

0.09 / 0.14 - 1.2 mJ / mm<sup>2</sup>, 3 sessions,

2000 pulses / session

Frequency 5 Hz

#### **Radial:**

1.4 - 2.5 bar, 3 sessions,

2000 pulses / session

Frequency up to 8 Hz

**Documentation:** Naming of the shock wave source.

**Coupling medium:** Ultrasonic gel.

**Localisation:** Patient-oriented focusing.

**After the therapy:** If necessary monitoring of the circulatory function.

**Literature:**

Unfortunately, there is no sufficiently valid indication-specific literature and reference is therefore made to the literature on radial epicondylitis.



## **Dupuytren's disease**

Prof. Dr. Karsten Knobloch

### **Classification**

M72.0 M. Dupuytren according to ICD-10

If necessary M67.14 Contracture of tendons of the hand according to ICD-10

### **Synonyms**

Dupuytren's contracture, palmar fibromatosis

### **Aetiology**

Genetic component about altered single-nucleotide-peptides (SNPs) with autosomal dominant inheritance with variable penetrance

### **Symptoms**

Palmar fibromatosis with initial nodules, possibly followed by strands, which can lead to flexion contracture without or when overcoming a finger joint. The ring finger and the little finger are affected above average in the palm of the hand and in the thigh finger plane. These knots / strands can also cause pain, presumably due to the ingrowth of skin pain fibres into the fibrosis knots. In addition to clinical palpation findings, differential imaging can also help to exclude benign or malignant tumours.

### **Apparative diagnostics**

Sonographically, Dupuytren's nodes appear superficially subcutaneously, often hypoechogenic, but sometimes also isoechogenic to the surrounding subcutaneous fat (Knobloch 2012). The T2 signal of the MRI can possibly be used as a biomarker to indicate the activity of a Dupuytren's node and can be used prognostically for the success of irradiation (Banks et al., 2018).

### **Therapy**

Therapeutically, the node stage (Tubiana N (nodular)) can be distinguished from the strand stage with finger joint contracture.

In the node stage, the following therapy options can be offered for symptomatic painful Dupuytren's nodes and level of suffering:

- Focused high-energy ESWT (typically three sessions at intervals of 1 - 2 weeks, control after 6 months as refreshment, Knobloch et al. 2012)
- ESWT improves pain and patient satisfaction better than stretching or laser therapy after 1 / 2 / 3 months without side effects (Notarnicola 2017)
- Radiotherapy to stop Dupuytren's progress (Banks 2018, Rödel 2017, Seegenschmiedt 2015)

In the randomized DupuyShockStudy (Knobloch et al. 2012), 52 patients at the mean age of  $58 \pm 9$  years with painful Dupuytren node Tubiana N were included. The intervention group underwent three sessions of high-energy electromagnetic ESWT (Storz Ultra, 2000 impulses, 3 Hz, up to  $1.24 \text{ mJ} / \text{mm}^2$ ,  $49 \text{ mJ} / \text{mm}^2 / \text{hand}$ ) compared to the placebo group.

Pain was significantly reduced by 54 % in the intervention group after 3, 6 and 12 months. In the same way, the patient-oriented outcomes scores DASH, Michigan Hand Questionnaire and URAM Scale improved significantly in favor of the intervention group. Side effects were not observed.

Radiotherapy in the nodal stage of Dupuytren's disease was tested in a cohort study of 135 patients with 208 symptomatic hands and 30Gy Orthovolt radiation. With a long follow-up period of 13 years the nodes remained stable in 59 %, improved in 10 % and showed progress in 31 % of cases.

In the strand stage with  $> 20^\circ$  joint contracture, the following therapy procedures are classically available for Dupuytren's disease:

- Operation as selective fasciectomy
- Percutaneous needle fasciotomy (PNF)
- Enzymatic fasciotomy with collagenase (Xiapex)

The focused high-energy shock wave therapy can develop additional positive effects with regard to wound healing, swelling reduction and, if necessary, relapse prophylaxis before and immediately after the mentioned procedures.

### **Shock wave therapy with M. Dupuytren**

**Indication:** Indication by the expert physician.

**Contraindication:** Focus on malignant tumor.

**Room requirements:** Certification criteria of a medical practice e. g. hygiene plan, emergency management available according to DIN standard.

**Patient preparation:** Differentiated and documented education and information.

**Physician and assistant:** The ESWT is a service to be provided personally by the physician qualified by means of specialist knowledge.

**Implementation of the therapy:**

**Positioning:** Sitting or lying according to the patient's wishes

- Focused ESWT:

0.08 - 0.55 mJ / mm<sup>2</sup> (in individual cases up to 1.24 mJ / mm<sup>2</sup> electromagnetic),  
2000 impulses, 3 sessions at weekly intervals,  
after 6 months if necessary refreshing ESWT one time

**Documentation:** Naming the shock wave source and the parameters used.

## Literature

Banks JS, Wolfson AH, Subhawong TK. T2 signal intensity as an imaging biomarker for patients with superficial fibromatoses of the hands (Dupuytren's disease) and feet (Ledderhose disease) undergoing definitive electron beam irradiation. *Skeletal Radiol* 2018;47(2):243-51.

Knobloch K, Kühn M, Vogt PM. Eine fokussierte hochenergetische Stoßwellentherapie verbessert die Lebensqualität bei M. Dupuytren – eine randomisierte Studie (DupuyShock). 43. Jahrestagung der Deutschen Gesellschaft der Plastischen, rekonstruktiven und ästhetischen Chirurgie (DGPRÄC), 2012, Bremen. doi: 10.3205/12dgpraec191

Knobloch K, Kühn M, Vogt PM. Fokussierte hochenergetische Stoßwellentherapie bei palmarer Knotenbildung bei M. Dupuytren – eine randomisierte Studie (DupuyShock). 53. Kongress der Deutschen Gesellschaft für Handchirurgie 2012 Lübeck. doi: 10.3205/12dgh05

Knobloch K, Kühn M, Sorg H, Vogt PM. German version of the Unite rhumatologique des affections de la main (URAM) scale in Dupuytren's disease: the need for a uniform definition of recurrence. *Arthritis Care Res (Hoboken)* 2012;64(5):793.

Knobloch K, Kuehn M, Papst S, Kraemer R, Vogt PM. German standardized translation of the michigan hand outcomes questionnaire for patient-related outcome measurement in Dupuytren disease. *Plast Reconstr Surg.* 2011 Jul;128(1):39e-40e. doi: 10.1097/PRS.0b013e318218fd70.

Knobloch K, Kuehn M, Vogt PM. Focused extracorporeal shockwave therapy in Dupuytren's disease-- a hypothesis. *Med Hypotheses*. 2011 May;76(5):635-7. doi: 10.1016/j.mehy.2011.01.018. Epub 2011 Feb 1.

Knobloch K. From nodules to chords in Dupuytren's contracture. *MMW Fortsch Med* 2012;154(19):36.

Knobloch K, Redeker J, Vogt PM. Antifibrotic medication using a combination of Nacetyl-L-cystein (NAC) and ACE inhibitors can prevent the recurrence of Dupuytren's disease. *Med Hypotheses*. 2009 Nov;73(5):659-61. doi: 10.1016/j.mehy.2009.08.011. Epub 2009 Sep 1.

Notarnicola A, Maccagnano G, Rifino F, Pesce V, Gallone MF, Covelli I, Moretti B. Short-term effect of shockwave therapy, temperature controlled high energy adjustable multi-mode emission laser or stretching in Dupuytren's disease: a prospective randomized clinical trial. *J Biol Regul Homeost Agents* 2017;31(3):775-84.

Rödel F, Fournier C, Wiedemann J, Merz F, Gaipf US, Frey B, Keilholz L, Seegenschmiedt MH, Rödel C, Hehlhans S. Basis of radiation biology when treating hyperproliferative benign diseases. *Front Immunol* 2017;8:519.

Seegenschmiedt MH, Micke O, Niewald M, Mücke R, Eich HT, Kriz J, Heyd R, German Cooperative Group on Radiotherapy of benign diseases. DEGRO guidelines for the radiotherapy of non-malignant disorders: part III: hyperproliferative disorders. *Strahlenther Onkol* 2015;191(7):541-8.

## **Trochanteric pain syndrome**

PD Dr. Jörg Hausdorf

### **ICD Classification**

M70.6

### **Synonyms**

GTPS (Greater Trochanteric Pain Syndrome)

### **Aetiology**

Bursitis trochanterica, Gluteal tendon tendinitis, -partial rupture, myofascial trigger points  
Pelvic geometry, chronic friction loading with subsequential degeneration of the gluteal muscles and irritation of the tractus, if applicable true bursitis.

### **Symptoms**

Local pressure pain peritrochantary  
Functional pain (stance leg phase)  
Night pain, lying on affected side not possible  
Alternating intensity  
Adduction pain, pos. Trendelenburg

### **Apparative diagnostics**

Ultrasound  
X-Ray  
MRT

### **Differential diagnosis**

Hip impingement (FAI), labrum lesion,  
Coxarthrosis, femoral head necrosis, tumor, pathological/fatigue fracture,  
Piriformis syndrome  
Sciatica  
Fibromyalgia  
Systemic diseases (spondylarthritis, gout)  
Periarticular ossifications

### **Conservative therapy**

Acupuncture, dry needling  
Manual medicine, physiotherapy, self exercises  
Weight reduction  
Infiltration, NSAID  
Physical measures: Electrotherapy / ultrasound / thermotherapy

### **Operative therapy**

Open / endoscopic bursectomy,

Arthroscopic / open gluteal tendon refixation

Tractus notch / extension, stabbing of the tendon, trochanter reduction plasty

### **Shock wave therapy**

**Indication:** Indication by the expert physician.

**Contraindication:** Malignant tumor in focus, local osteomyelitis in focus.

#### **Before therapy:**

**Room requirements:** Certification criteria of a medical practice e. g. hygiene plan, emergency management available according to DIN standard.

**Patient preparation:** Differentiated (medical and economic) and documented education and information (onset of effect after weeks).

**Doctor and assistant staff:** ESWT is a service to be provided personally by a doctor qualified by means of specialist knowledge.

#### **Implementation of the therapy:**

Up to 5 treatments lateral position (with cushion positioning between the legs) no local anaesthesia, if necessary line anaesthesia, if necessary cryotherapy.

Coupling medium: Ultrasound gel.

Localisation: Patient-oriented focus / ultrasound.

Shock wave source

##### **- Focused:**

EFD: 0.10 - 0.35 mJ / mm<sup>2</sup> (pain-adapted dosing)

Interval: 1 - 2 weeks

Frequency up to 5Hz

Impulses: 1500 - 2000 / session

##### **- Radial:**

Pressure strength up to 4 bar (pain-adapted dosing)

Interval: 1 - 2 weeks

Frequency: up to 10 Hz

Impulses: 2000 - 3000 / session

**After therapy:**

Documentation of device, treatment parameters, if necessary monitoring of circulatory function.

**Complications / adverse effects:** Haematoma, pain enhancement, nerve irritation.

**Aftercare:**

Individual sports adaptation, continuation of stretching exercises.

Clinical success checks after 4 weeks.

**Literature**

Furia JP, Rompe JD, Maffulli N. Low-energy extracorporeal shock wave therapy as a treatment for greater trochanteric pain syndrome. *Am J Sports Med.* 2009;37:1806–1813

Mani-Babu S, Barton C, Morrissey D. The effectiveness and dose-response relationship of extracorporeal shock wave therapy in lower limb tendinopathy: a systematic review. *J Sci Med Sport.* 2012;15:133–134.

Reid D. The management of greater trochanteric pain syndrome: A systematic literature review. *J Orthop.* 2016 Mar; 13(1): 15–28.

Rompe JD, Segal NA, Cacchio A, Furia JP, Morral A, Maffulli N. Home training, local corticosteroid injection, or radial shock wave therapy for greater trochanter pain syndrome. *Am J Sports Med.* 2009;37:1981–1990.

## **Plantar fasciitis**

PD Dr. Jörg Hausdorf

### **Classification**

M77.3ICD10

### **Synonyms**

Heel spur, fasciitis plantaris, plantar heel pain, medial heel pain.

### **Aetiology**

Overweight, overburdening / incorrect loading,

Loss of longitudinal arch

Training error (increase in distance, duration, speed)

Standing professions

Bursitis / irritation at the base of plantar aponeurosis

Periosteal irritation

### **Symptoms**

Pain at start, changing intensity, mostly one-sided

20 - 30 % both sides

Typical pain localisation: Tub. med. calcanei

Occasional radiation laterally or distally

### **Apparative diagnostics**

Ultrasound

X-Ray

MRT

### **Differential diagnosis**

Tarsal tunnel syndrome, achillodynia, calcaneus fractures, compartment syndrome rupture of the plantar aponeurosis, plantar vein thrombosis

Systemic diseases (SLE, RA, spondylarthritis, gout), osteomyelitis

Radicular symptoms, foot deformity

### **Conservative therapy**

Physio therapy / own exercises (eccentric exercises)

Myofascial trigger point therapy

Infiltration

Insoles, relief

NSAIDs,

Physical therapy: Electrotherapy / ultrasound therapy / thermal therapy

X-ray stimulation radiation



## **Operative therapy**

Drilling

Calcaneus osteotomy

Neurolisis (N. plant.med.)

Neurectomy of the N. plant. med. / Rr. Calcanei

Osteotomy of the spur (open / endoscopic)

Plantar fascia release (open / endoscopic)

## **Shock wave therapy**

**Indication:** Symptomatics > 6 weeks, indication by the expert physician.

**Contraindication:** Malignant tumor in focus, local osteomyelitis in focus.

### **Before therapy:**

**Room requirements:** Certification criteria of a medical practice e. g. hygiene plan, emergency management available according to DIN standard.

**Preparation of the patient:** Differentiated and documented education and information (bony spur persists, onset of effect after weeks).

**Doctor and assistant staff:** ESWT is a service to be provided personally by a doctor qualified by means of specialist knowledge.

### **Implementation of the therapy:**

Up to 5 treatments

No local anaesthesia, if necessary cryotherapy

Coupling medium ultrasound gel

Localisation: Patient-oriented focusing

Shockwave source:

#### **- Focused:**

EFD: 0.08 - 0.35 mJ / mm<sup>2</sup> (pain-adapted dosing)

Interval 1 - 2 weeks

Frequency up to 5Hz

Impulses: 1500 - 2000 / session

#### **- Radial:**

Pressure strength: 2 - 4 bar (pain-adapted dosing)

Interval 1 - 2 weeks

Frequency up to max. 10 Hz  
Impulses: 2000 - 3000 per session

**After the therapy:** Documentation of the treatment parameters, monitoring of the circulatory function, if necessary.

**Complications / adverse effects:** Haematoma, pain enhancement, nerve irritation.

**Follow-up treatment:**

Individual sports adaptation  
Continuation of stretching exercises  
Clinical success control after 4-6 weeks

**Literature:**

Aqil A, Siddiqui MR, Solan M, et al. Extracorporeal shock wave therapy is effective in treating chronic plantar fasciitis: a meta-analysis of RCTs. *ClinOrthopRelat Res* 2013;471:3645–52

Chang KV et al. Comparative effectiveness of focused shock wave therapy of different intensity levels and radial shock wave therapy for treating plantar fasciitis: a systematic review and network meta-analysis. *Arch Phys Med Rehabil.* 2012 Jul;93(7):1259-68

Gerdesmeyer L, Frey C, Vester J, et al. Radial extracorporeal shock wave therapy is safe and effective in the treatment of chronic recalcitrant plantar fasciitis: results of a confirmatory randomized placebo-controlled multicenter study. *Am J Sports Med* 2008;36:2100–9.

Gollwitzer H et al. Clinically relevant effectiveness of focused extracorporeal shock wave therapy in the treatment of chronic plantar fasciitis: a randomized, controlled multicenter study. *J Bone Joint Surg Am.* 2015 May 6;97(9):701-8.

Haake M, Buch M, Schoellner C, et al. Extracorporeal shock wave therapy for plantar fasciitis: randomised controlled multicentre trial. *BMJ* 2003;327:75.

Ibrahim MI et al. Long-term results of radial extracorporeal shock wave treatment for chronic plantar fasciopathy: A prospective, randomized, placebo-controlled trial with two years follow-up. *J Orthop Res.* 2017 Jul;35(7):1532-1538

Njawaya MM et al. Ultrasound Guidance Does Not Improve the Results of Shock Wave for Plantar Fasciitis or Calcific Achilles Tendinopathy: A Randomized Control Trial. *Clin J Sport Med.* 2018 Jan;28(1):21-27

Roerdink RL et al. Complications of extracorporeal shockwave therapy in plantar fasciitis: Systematic review. *Int J Surg.* 2017 Oct;46:133-145

Rompe JD et al. Radial shock wave treatment alone is less efficient than radial shock wave treatment combined with tissue-specific plantar fascia-stretching in patients with chronic plantar heel pain. *Int J Surg*. 2015 Dec;24(Pt B):135-42

Rompe JD, Meurer A, Nafe B, Hofmann A, Gerdesmeyer L. Repetitive low-energy shock wave application without local anesthesia is more efficient than repetitive lowenergy shock wave application with local anesthesia in the treatment of chronic plantar fasciitis. *J Orthop Res* 2005; 23(4): 931-941

Saxena A et al. Treatment of Plantar Fasciitis With Radial Soundwave "Early" Is Better Than After 6 Months: A Pilot Study. *J Foot AnkleSurg*. 2017 Sep - Oct;56(5):950-953

Speed CA, Nichols D, Wies J, et al. Extracorporeal shock wave therapy for plantar fasciitis. A double blind randomised controlled trial. *JOrthop Res* 2003;21:937-40

Sun J et al. Extracorporeal shock wave therapy is effective in treating chronic plantar fasciitis: A meta-analysis of RCTs. *Medicine (Baltimore)*. 2017 Apr;96(15

## **Achilles tendinopathy - insertional and non-insertional**

Dr. Martin Ringeisen

### **ICD Classification**

M77.3ICD10

### **Synonyms**

Mid-portion tendinopathy, enthesiopathy, dorsal heel pain with / without posterior heel spur

### **Aetiology**

Overuse due to sport / everyday life  
Direct mechanical irritation of the Achilles tendon  
Degeneration of the tendon tissue  
Haglund exostosis  
Foot malpositions  
Overweight  
Reduced mobility OSG / USG and metatarsophalangeal joint

### **Symptoms**

Local pressure pain, functional pain  
Alternating intensity, initially pain only during exertion, later persistent pain and pain at rest  
Typically localised in the tendon and / or at the base  
Swelling of the tendon

### **Apparative diagnostics**

Ultrasound  
MRT  
X-Ray

### **Differential diagnosis**

Inflammatory rheumatic diseases - mainly SPA, Bechterew's disease, Reiter's disease, psoriatic arthritis  
Metabolic diseases - gout / hypercholesterolemia  
Drug-induced / creeping ruptures, in particular through gyrase inhibitors OSG / USG diseases  
Os-trigonum impingement / flexor-hallucis-longus syndrome  
Stress fractures  
Bursitides  
Spontaneous rupture

### **Conservative therapy (alphabetical order)**

Physiotherapy / excentric loading, electrotherapy / ultrasound  
Orthoses, buffer heel

Infiltration (peritendinous) without cortisone  
Platelet rich plasma (PRP)  
NSAR  
Acupuncture  
Immobilization / relief / kinesiotope

### **Operative therapy**

Debridement of the tendon  
Stabbing of the tendon  
Refixation (open)

### **Shock wave therapy**

**Indication:** Therapy-resistant symptoms, indication by the expert physician.

**Contraindication:** Focus on malignant tumor.

**Room requirements:** Certification criteria of a medical practice e. g. hygiene plan, emergency management available according to DIN standard.

**Patient preparation:** Differentiated and documented education and information (onset of effect after weeks).

**Doctor and assistant staff:** ESWT is a service to be provided personally by a doctor qualified by means of specialist knowledge.

### **Implementation of the therapy:**

No local anaesthesia, cryotherapy if necessary.

Naming the SW source

- Focused

Coupling medium (ultrasound gel)  
Single / multiple sessions (standard up to 3, max. 5 treatments)  
EFD: 0.10 - 0.25 mJ / mm<sup>2</sup> (pain-adapted dosing)  
Frequency: Up to max. 5 Hz  
Impulses: 1500 - 2500 / session  
Interval: 1 - 2 weeks

## - Radial

Coupling medium (ultrasound gel / cave air bubbles)

Multiple (standard up to 3, max. 5 treatments)

Pressure strength: 2 - 4 bar (pain-adapted dosing)

Frequency: Up to max. 10 Hz

Impulses: 2000 - 3000 / session

Interval: 1 - 2 weeks

Localisation: Patient-oriented focusing with regard to imaging.

**After the therapy:** If necessary monitoring of the circulatory function.

**Complications:** Hematoma, pain enhancement, nerve irritation.

### **Follow-up treatment:**

Adjustment of load, sport modification

Clinical success control after 8 - 12 weeks

## Literature:

Ludger Gerdesmeyer , Rainer Mittermayr, Martin Fuerst, Munjed Al Muderis , Richard Thiele, Amol Saxena, Hans Gollwitzer Current evidence of extracorporeal shockwave therapy in chronic Achilles tendinopathy, Review International Journal of Surgery 24 (2015) 154e159.

L. Gerdesmeyer, M. Maier, M. Haake, C. Schmitz, Physical-technical principles of extracorporeal shockwave therapy (ESWT), Orthopade 31 (2002) 610e617.

L. Gerdesmeyer, C. Frey, J. Vester, et al., Radial extracorporeal shockwave therapy is safe and effective in the treatment of chronic recalcitrant plantar fasciitis: results of a confirmatory randomized placebo-controlled multicenter study, Am. J. Sports Med. 36 (2008) 2100e2109.

P. Diehl, H. Gollwitzer, J. Schauwecker, T. Tischer, L. Gerdesmeyer, Conservative treatment of chronic tendinopathies, Orthopade 43 (2014) 183e193. [4] M.A. Childress, A. Beutler, Management of chronic tendon injuries, Am. Fam. Physician 87 (2013) 486e490.

J.A. Peters, J. Zwerver, R.L. Diercks, M.T. Elferink-Gemser, I. van dA-S, Preventive interventions for tendinopathy: a systematic review, J. Sci. Med. Sport (2015 Apr 1) 1440e2440.

R. Zwiers, J.I. Wiegerinck, C.N. van Dijk, Treatment of midportion Achilles tendinopathy: an evidence-based overview, Knee Surg. Sports Traumatol. Arthrosc. 22 (2014) 1433e7347.

- B. Magnan, M. Bondi, S. Pierantoni, E. Samaila, The pathogenesis of Achilles tendinopathy: a systematic review, *Foot Ankle Surg.* 20 (2014) 154e159.
- M.F. Joseph, K.R. Lillie, D.J. Bergeron, et al., Achilles tendon biomechanics in response to acute intense exercise, *J. Strength Cond. Res.* 28 (2014) 1181e1186.
- J.I. Wiegerinck, G.M. Kerkhoffs, M.N. van Sterkenburg, I.N. Sierevelt, C.N. van Dijk, Treatment for insertional Achilles tendinopathy: a systematic review, *Knee Surg. Sports Traumatol. Arthrosc.* 21 (2013) 1345e1355.
- V. Rowe, S. Hemmings, C. Barton, P. Malliaras, N. Maffulli, D. Morrissey, Conservative management of midportion Achilles tendinopathy: a mixed methods study, integrating systematic review and clinical reasoning, *Sports Med.* 42 (2012) 941e967.
- K. Knobloch, The role of tendon microcirculation in Achilles and patellar tendinopathy, *J. Orthop. Surg. Res.* 3 (2008) 18.
- P. Diehl, H. Gollwitzer, J. Schauwecker, T. Tischer, L. Gerdesmeyer, Conservative treatment of chronic tendinopathies, *Orthopade* 43 (2014) 183e193.
- R. Kearney, M.L. Costa, Insertional achilles tendinopathy management: a systematic review, *Foot Ankle Int.* 31 (2010) 689e694.
- J.P. Furia, Extracorporeal shockwave therapy in the treatment of chronic insertional Achilles tendinopathy, *Orthopade* 34 (2005) 571e578.
- U. Balasubramaniam, R. Dissanayake, L. Annabell, Efficacy of platelet-rich plasma injections in pain associated with chronic tendinopathy: a systematic review, *Phys. Sportsmed.* (2015) 1e9.
- R.S. Kearney, N. Parsons, D. Metcalfe, M.L. Costa, Injection therapies for Achilles tendinopathy, *Cochrane Database Syst. Rev.* 5 (2015). CD010960.
- N. Maffulli, R. Papalia, S. D'Adamio, B.L. Diaz, V. Denaro, Pharmacological interventions for the treatment of Achilles tendinopathy: a systematic review of randomized controlled trials, *Br. Med. Bull.* 113 (2015) 101e115.
- J.P. Furia, High-energy extracorporeal shockwave therapy as a treatment for insertional Achilles tendinopathy, *Am. J. Sports Med.* 34 (2006) 733e740.
- M.L. Costa, L. Shepstone, S.T. Donell, T.L. Thomas, Shock wave therapy for chronic Achilles tendon pain: a randomized placebo-controlled trial, *Clin. Orthop. Relat. Res.* 440 (2005) 199e204.
- J.P. Furia, High-energy extracorporeal shockwave therapy as a treatment for chronic non insertional Achilles tendinopathy, *Am. J. Sports Med.* 36 (2008) 502e508.
- S. Rasmussen, M. Christensen, I. Mathiesen, O. Simonson, Shock wave therapy for chronic Achilles tendinopathy: a double-blind, randomized clinical trial of efficacy, *Acta Orthop.* 79 (2008) 249e256.

J.D. Rompe, B. Nafe, J.P. Furla, N. Maffulli, Eccentric loading, shock-wave treatment, or a wait-and-see policy for tendinopathy of the main body of tendo Achillis: a randomized controlled trial, *Am. J. Sports Med.* 35 (2007) 374e383.

J.D. Rompe, J. Furla, N. Maffulli, Eccentric loading compared with shockwave treatment for chronic insertional Achilles tendinopathy. A randomized, controlled trial, *J. Bone Jt. Surg. Am.* 90



## **Patellar tip syndrome**

Dr. Martin Ring Iron

### **ICD Classification**

M77.3ICD10

### **Synonyms**

Tendinopathy of the patellar tendon, jumper's knee

### **Definition**

Functional overload of the patellar tendon origin by repetitive stress of the knee extensors, especially in sports such as volleyball, basketball, high jump, long jump

### **Aetiology**

Chronic overload / misstrain

Training error

Irritation of the origin of the patellar tendon at the tip of the patella

Degenerative changes

Morphological structural change of the tendon

Anatomical / static variances of the femuropatellar joint

### **Symptoms**

Local pressure pain, functional pain

Alternating intensity

Typically localized at the tip of the patella

### **Apparative diagnostics**

Ultrasound

X-Ray

MRT

### **Differential diagnoses**

Metabolic causes: Hyperlipidemia, gout, diabetes

Basic rheumatic disease

Gonarthrosis

Hoffaitis

Pharma-induced tendopathy (e. g. gyrase inhibitor)

Sinding-Larsson-Johansson's disease

### **Conservative therapy options**

Physiotherapy, stretching, eccentric training

Electrotherapy / ultrasound

Orthoses, buffer heel

Infiltration therapy

NSAID

Relief

### **Surgical therapy**

Debridement of the tendon, denervation of the tendon / refixation (open / endoscopic)

### **Shock wave therapy**

**Indication:** Therapy-resistant symptoms, indication by the expert physician.

**Contraindication:** Focus on malignant tumor.

**Room requirements:** Certification criteria of a medical practice e. g. hygiene plan, emergency management available according to DIN standard.

**Patient preparation:** Differentiated and documented education and information (onset of effect after weeks).

**Doctor and assistant staff:** ESWT is a service to be provided personally by a doctor qualified by means of specialist knowledge.

### **Implementation of the therapy:**

No local anaesthesia, cryotherapy if necessary.

Naming the shock wave source

- Focused

Coupling medium (ultrasound gel)

Single / multiple sessions (standard up to 3, max. 5 treatments)

EFD: 0.10 - 0.25 mJ / mm<sup>2</sup> (pain-adapted dosing)

Frequency: Up to max. 5 Hz

Impulses: 1500 - 2500 / session

Interval: 1 - 2 weeks

- Radial

Coupling medium (ultrasonic gel / cave air bubbles)

Multiple sessions (standard up to 3, max. 5 treatments)

Pressure strength: 2-4 bar (pain-adapted dosing)

Frequency: Up to max. 10 Hz

Impulses: 2000 - 3000 / session

Interval: 1 - 2 weeks

Localisation: Patient-oriented focusing.

**After the therapy:** If necessary monitoring of the circulatory function.

**Complications:** Haematoma, pain enhancement, nerve irritation.

**Follow-up treatment:**

Adjustment of load, sport modification

Clinical success control after 8 - 12 week

**Literature:**

Carlos Leal, Silvia Ramon, John Furia, Arnold Fernandez, Luis Romero, Leonor Hernandez-Sierra, Current concepts of shockwave therapy in chronic patellar Tendinopathy, Review International Journal of Surgery 24 (2015) 160e164

M.E. Blazina, R.K. Kerlan, F.W. Jobe, V.S. Carter, G.J. Carlson, Jumper's knee, Orthop. Clin. North Am. 4 (1973) 665e678

A. Ferretti, Epidemiology of jumper's knee, Sports Med. 3 (1986) 289e295. O.B. Lian, L. Engebretsen, R. Bahr, Prevalence of jumper's knee among elite athletes from different sports: a cross-sectional study, Am. J. Sports Med. 33(2005) 561e567

A. Ferretti, E. Ippolito, P. Mariani, G. Puddu, Jumper's knee, Am. J. Sports Med. 11 (1983) 58e62

K.M. Khan, J.L. Cook, F. Bonar, P. Harcourt, M. Astrom, Histopathology of common tendinopathies. Update and implications for clinical management, Sports Med. 27 (1999) 393e408

N. Maffulli, K.M. Khan, G. Puddu, Overuse tendon conditions: time to change a confusing terminology, *Arthroscopy* 14 (1998) 840e843

P.J. Visentini, K.M. Khan, J.L. Cook, Z.S. Kiss, P.R. Harcourt, J.D. Wark, The VISA score: an index of severity of symptoms in patients with jumper's knee (patellar tendinosis). Victorian Institute of Sport Tendon Study Group, *J. Sci. Med. Sport* 1 (1998) 22e28

M.C. Vulpiani, M. Vetrano, V. Savoia, E. Di Pangrazio, D. Trischitta, A. Ferretti, Jumper's knee treatment with extracorporeal shock wave therapy: a longterm follow-up observational study, *J. Sports Med. Phys. Fit.* 47 (2007)323e328

M. Vetrano, A. Castorina, M.C. Vulpiani, R. Baldini, A. Pavan, A. Ferretti, Platelet-rich plasma versus focused shock waves in the treatment of jumper's knee in athletes, *Am. J. Sports Med.* 41 (2013) 795e803

J.E. Gaida, J. Cook, Treatment options for patellar tendinopathy: critical review, *Curr. Sports Med. Rep.* 10 (2011) 255e270

C.J. Wang, J.Y. Ko, Y.S. Chan, L.H. Weng, S.L. Hsu, Extracorporeal shockwave for chronic patellar tendinopathy, *Am. J. Sports Med.* 35 (2007) 972e978

J. Zwerver, S.W. Bredeweg, I. Van den Akker-Scheek, Prevalence of jumper's knee among non elite athletes from different sports: a cross-sectional survey, *Am. J. Sports Med.* 39 (2011) 1984e1988

H. Van der Worp, M. Van Ark, S. Roerink, G.J. Pepping, I. Van den Akker-Scheek, J. Zwerver, Risk factors for patellar tendinopathy: a systematic review of the literature, *Br. J. Sports Med.* 45 (2011) 446e452

E. Witvrouw, J. Bellemans, R. Lysens, L. Danneels, D. Cambier, Intrinsic riskfactors for the development of patellar tendinitis in an athletic population. A two-year prospective study, *Am. J. Sports Med.* 29 (2001) 190e195.

U.M. Kujala, K. Osterman, M. Kvist, T. Aalto, O. Friberg, Factors predisposing to patellar chondropathy and patellar apicitis in athletes, *Int. Orthop.* 10 (1986) 195e200.

J.D. Rees, N. Maffulli, J. Cook, Management of tendinopathy, *Am. J. Sports Med.* 37 (2009) 1855e1867.

J.D. Rees, A.M. Wilson, R.L. Wolman, Current concepts in the management of tendon disorders, *Rheumatol. Oxf.* 45 (2006) 508e521.

K.M. Khan, N. Maffulli, B.D. Coleman, J.L. Cook, J.E. Taunton, Patellar tendinopathy: some aspects of basic science and clinical management, *Br. J. Sports Med.* 32 (1998) 346e355.

M.E. Larsson, I. K€all, K. Nilsson-Helander, Treatment of patellar tendinopathy a systematic review of randomized controlled trials, *Knee Surg. Sports Traumatol. Arthrosc.* 20 (2012) 1632e1646.

E.C. Rodriguez-Merchan, The treatment of patellar tendinopathy, *J. Orthop.Traumatol.* 14 (2013) 77e81.

H. Visnes, R. Bahr, The evolution of eccentric training as treatment for patellar tendinopathy (jumper's knee): a critical review of exercise programmes, *Br. J.Sports Med.* 41 (2007) 217e223.

H. Van der Worp, I. Van den Akker-Scheek, H. Van Schie, J. Zwerver, ESWT for tendinopathy: technology and clinical implications, *Knee Surg. Sports Traumatol.Arthrosc.* 21 (2013) 1451e1458

F. Ioppolo, J.D. Rompe, J.P. Furia, A. Cacchio, Clinical application of shock wave therapy (SWT) in musculoskeletal disorders, *Eur. J. Phys. Rehabil. Med.* 50(2014) 217e230.

C.J. Wang, Extracorporeal shockwave therapy in musculoskeletal disorders, *J. Orthop. Surg. Res.* 7 (2012) 11.

M.T. Van Leeuwen, J. Zwerver, I. Van den Akker-Scheek, Extracorporeal shockwave therapy for patellar tendinopathy: a review of the literature, *Br. J.Sports Med.* 43 (2009) 163e168.

F. Vara, N. Garzon, E. Ortega, G.J. Alarcon, E. Lopez, Treatment of the patellartendinitis with local application of extracorporeal shock waves, in: Abstract41 from the 3rd Congress of the International Society for Medical ShockwaveTreatment, 2000. Naples.

K.M. Taunton, J.E. Taunton, K.M. Khan, Treatment of patellar tendinopathywith extracorporeal shock wave therapy, *B. C. Med. J.* 45 (2003) 500e507.

K.H. Peers, Extracorporeal shock wave therapy in chronic patellar tendinopathy: a randomised double-blinded, placebo-controlled trial, *Proefschr. KULeuven* 1 (2003) 3e11.

K.H. Peers, R.J. Lysens, P. Brys, J. Bellemans, Cross-sectional outcome analysisof athletes with chronic patellar tendinopathy treated surgically and byextracorporeal shock wave therapy, *Clin. J. Sport Med.* 13 (2003) 79e83.

J. Zwerver, F. Dekker, G.J. Pepping, Patient guided piezo-electric extracorporeal shockwave therapy as treatment for chronic severe patellar tendinopathy: a pilot study, *J. Back Musculoskelet. Rehabil.* 23 (2010) 111e115.

H. Lohrer, J. Scholl, S. Arentz, Achilles tendinopathy and patellar tendinopathy. Results of radial shockwave therapy in patients with unsuccessfully treated tendinosis, *Sportsverletz Sportschaden* 16 (2002) 108e114

J.P. Furia, J.D. Rompe, A. Cacchio, A. Del Buono, N. Maffulli, A single applicationof low-energy radial extracorporeal shock wave therapy is effective for the management of chronic patellar tendinopathy, *Knee Surg. Sports Traumatol.Arthrosc.* 21 (2013) 346e350.

A. Notarnicola, B. Moretti, The biological effects of extracorporeal shock wave therapy (ESWT) on tendon tissue, *Muscles Ligaments Tendons* 2 (2012) 33.

N. Maffulli, U.G. Longo, V. Denaro, Novel approaches for the management of tendinopathy, *J. Bone Jt. Surg. Am.* 92 (2010) 2604e2613.

A. Pascarella, M. Alam, F. Pascarella, C. Latte, M.G. Di Salvatore, N. Maffulli, Arthroscopic management of chronic patellar tendinopathy, *Am. J. SportsMed.* 39 (2011) 1975e1983.

K. Kulig, R. Landel, Y.-J. Chang, N. Hannanvash, S.F. Reischl, P. Song, G.R. Bashford, Patellar tendon morphology in volleyball athletes with and without patellar tendinopathy, *Scand. J. Med. Sci. Sports* 23 (2013) e81ee88, <http://dx.doi.org/10.1111/sms.12021>.

J.A. Ogden, G.L. Cross, Atlanta, Georgia Electrohydraulic orthotripsy for chronic patellar tendinopathy, in: *Transactions of the 6th International Congress of the ISMST*, Feb 11e13, 2003, 2003.

C. Leal, J.C. Lopez, J.M. Herrera, O.E. Reyes, M. Cortes, Shockwave biosurgery and autologous growth factors combined therapy in severe patellar tendinopathies, in: *Transactions of the 9th International Congress of the ISMST*, Apr. 23, 2006, 2006.

J. Crupnik, Eccentric loading plus radial shock wave therapy in the treatment of chronic patellar tendinopathy, in: *Transactions of the 12th International Congress of the ISMST*, Jun 2009, 2009.

E. Serrano, J.C. Criado, ESWT therapy in patellar tendinopathy comparison of 2 protocols, in: *Transactions of the 17th International Congress of the ISMST*, Jun 2014, 2014.

C. Leal, O. Hernandez, M. Cardozo, M.C. Gallo, Shockwave therapy in patellar tendinopathies, in: *Transactions of the 15th International Congress of the ISMST*, Jun 2012, 2012.

C.J. Wang, J.Y. Ko, Y.S. Chan, L.H. Weng, S.L. Hsu, Extracorporeal shockwave for chronic patellar tendinopathy, in: *Transactions of the 10th International Congress of the ISMST*, Jun 9th, 2007, 2007.

P.R. Rockett, M. Lui, Effectiveness of ESWT in patients with chronic patellar tendinopathy, in: *Transactions of the 12th International Congress of the ISMST*, Jun 2009, 2009.

J. Zwerver, M. Van Leeuwen, I. Van Den Akker-Scheek, ESWT for patellar tendinopathy, in: *Transactions of the 12th International Congress of the ISMST*, Jun 2009, 2009.

H. Van der Worp, H. Zwerver, I. Van Den Akker-Scheek, ESWT treatment protocols for jumper's knee: a worldwide survey, in: *Transactions of the 13<sup>th</sup> International Congress of the ISMST*, Jun 2010, 2010.

R.W. Wu, C.J. Wang, J.Y. Ko, Shockwave treatment for chronic patellar tendinopathy of the knee, in: *Transactions of the 13th International Congress of the ISMST*, Jun 2010, 2010.

J.P. Furla, J.D. Rompe, A. Cacchio, N. Maffulli, Low energy extracorporeal shock therapy as a treatment for chronic patellar tendinopathy, in: Transactions of the 14th International Congress of the ISMST, Jun 2011, 2011.

C. Leal, D. Lemus, J. Juschten, Shockwave therapy for patellar tendinopathy in patients with total knee arthroplasties, in: Transactions of the 17th International Congress of the ISMST, Jun 2014, 2014

## **Tibial stress syndrome**

Dr. Martin Ringeisen

### **ICD Classification**

M76.8ICD10

### **Synonyms**

Shin splint

Periostitis / periostosis of the tibial crest

Medial tibial stress syndrome MTSS

### **Definition**

Loading dependent pain at the medial edge of the tibia in the middle and lower third due to overloading of the tibialis posterior and flexor hallucis longus muscles with irritation of the dorsomedial tibial periosteum.

### **Aetiology**

Chronic overload / misstrain

Usually caused by athletic strain, often endurance sport or sprinter / jumper

High force effect due to hard surfaces / asphalt

After renewal of the footwear

When using spike shoes

Pronation is increased in the case of kinking / lowering feet

### **Symptoms**

Increasing pain at the medial edge of the tibia in the middle and distal third

Commonly bilateral occurrence

Local pressure pain, functional pain

Alternating intensity

### **Apparative diagnostics**

MRT

X-Ray

### **Differential diagnosis**

Differentiation from the rare anterior compartment syndrome

Bone injuries of the middle / distal tibia

### **Conservative therapy options**

Physiotherapy, stretching, electrotherapy / ultrasonics

Orthoses, buffer heel

NSAID

Relief

Sports modification



## **Shock wave therapy**

**Indication:** Therapy-resistant symptoms, indication by the expert physician.

**Contraindication:** Focus on malignant tumor.

**Room requirements:** Certification criteria of a medical practice e. g. hygiene plan, emergency management available according to DIN standard.

**Patient preparation:** Differentiated and documented education and information (onset of effect after weeks).

**Doctor and assistant staff:** ESWT is a service to be provided personally by a doctor qualified by means of specialist knowledge.

### **Therapy:**

No local anaesthesia, cryotherapy if necessary.

Naming the SW source

#### **- Focused**

Coupling medium (ultrasound gel)

Single / multiple sessions (standard up to 3, max. 5 treatments)

EFD: 0.10 - 0.25 mJ / mm<sup>2</sup> (pain-adapted dosing)

Frequency: Up to max. 5 Hz

Impulses: 1500 - 2500 / session

Interval: 1 - 2 weeks

#### **- Radial**

Coupling medium (ultrasound gel / cave air bubbles)

Multiple (standard up to 3, max. 5 treatments)

Pressure strength: 2-4 bar (pain-adapted dosing)

Frequency: Up to max. 10 Hz

Impulses: 2000 - 3000 / session

Interval: 1 - 2 weeks

Localisation: Patient-oriented focusing.

**After the therapy:** If necessary monitoring of the circulatory function.

**Complications:** Haematoma, pain enhancement, nerve irritation.

**Follow-up treatment:**

Adjustment of load, sport modification  
Clinical success control after 8 - 12 weeks

**Literature:**

Korakakis V, Whiteley R, Tzavara A, Malliaropoulos N. The effectiveness of extracorporeal shockwave therapy in common lower limb conditions: a systematic review including quantification of patient-rated pain reduction. *Br J Sports Med.* 2017 Sep 27. pii: bjsports-2016-097347. doi: 10.1136/bjsports-2016-097347.

Gomez Garcia S, Ramon Rona S, Gomez Tinoco MC, Benet Rodriguez M, Chaustre Ruiz DM, Cardenas Letrado FP, Lopez-Illescas Ruiz Á, Alarcon Garcia JM. Shockwave treatment for medial tibial stress syndrome in military cadets: A single-blind randomized controlled trial. *Int J Surg.* 2017 Oct;46:102-109. doi: 10.1016/j.ijisu.2017.08.584. Epub 2017 Sep 5.

Winters M1, Eskes M, Weir A, Moen MH, Backx FJ, Bakker EW. Treatment of medial tibial stress syndrome: a systematic review. *Sports Med.* 2013 Dec;43(12):1315-33. doi: 10.1007/s40279-013-0087-0.

Moen MH1, Rayer S, Schipper M, Schmikli S, Weir A, Tol JL, Backx FJ. Shockwave treatment for medial tibial stress syndrome in athletes; a prospective controlled study. *Br J Sports Med.* 2012 Mar;46(4):253-7. doi: 10.1136/bjism.2010.081992. Epub 2011 Mar 9.

Reshef N1, Guelich DR. Medial tibial stress syndrome. *Clin Sports Med.* 2012 Apr;31(2):273-90. doi: 10.1016/j.csm.2011.09.008

## **Hamstring tendinopathy**

Dr. Martin Ringeisen

### **ICD Classification**

M76.9

**Synonyms:** Origin tendinopathy at tuber ischiadicum, proximal hamstring tendinosis / tendinopathy (PHT).

### **Definition "hamstrings":**

Origin of 3 tendons at the tuber ischiadicum:

M. bicepsfemoris (caput longum)

M. semitendinosus

M. semimembranosus

Function: Hip extension and knee flexion

### **Clinic**

Pain in the area of the ischium

Pain when sitting (driving a car)

Pain when climbing stairs and with inclination

"Deep" glutealgia

Often radiating dorsally up to the hollow of the knee

Distinction from ischialgia important

### **Genesis**

Mainly through sport traumata: Football / ski / sprinter / boxer / hurdlers

Repetitive overstrains / bending activities

Degenerative structural change of the tendon

### **Differential diagnoses**

Affections of the n. ischiadicus: NPP / neuroforaminale and / or recessale

Stenoses / spinal stenoses

Fractures of the ischium / stress reactions

Affections of the hip joint - centrocaudale arthroses

Inflammations / tumors in the pelvis

### **Diagnostics**

MRT Diagnostics

X-rays

### **Therapy**

Relief

Physiotherapy: Lymph drainage / manual therapy

Bandage

In acute stage analgesic medication  
In case of persistent / chronic complaints ESWT  
Operative: Debridement and reinsertion

### **Shock wave therapy**

**Indication:** Therapy-resistant symptoms, indication by the expert physician.

**Contraindication:** Malignant tumor in focus, osteomyelitis.

**Room requirements:** Certification criteria of a medical practice e. g. hygiene plan, emergency management available according to DIN standard.

**Patient preparation:** Differentiated and documented education and information (onset of effect after weeks).

**Doctor and assistant staff:** ESWT is a service to be provided personally by a doctor qualified by means of specialist knowledge.

#### **Therapy:**

No local anaesthesia, cryotherapy if necessary.

Naming the shock wave source

##### - Focused

Coupling medium (ultrasound gel)

Single / multiple sessions (standard up to 3, max. 5 treatments)

EFD: 0.10 - 0.25 mJ / mm<sup>2</sup> (pain-adapted dosing)

Frequency: Up to max. 5 Hz

Impulses: 1500 - 2500 / session

Interval: 1 - 2 weeks

##### - Radial

Coupling medium (ultrasound gel / cave air bubbles)

Multiple sessions (standard up to 3, max. 5 treatments)

Pressure strength: 2 - 4 bar (pain-adapted dosing)

Frequency: Up to max. 10 Hz

Impulses: 2000 - 3000 / session

Interval: 1 - 2 weeks

Localisation: Patient-oriented focusing.

**After the therapy:** If necessary monitoring of the circulatory function

**Complications:** Haematoma, pain enhancement, nerve irritation.

**Follow-up treatment:**

Adjustment of load, sport modification

Clinical success control after 8 - 12 weeks

**Literature:**

Korakakis V, Whiteley R, Tzavara A, Malliaropoulos N. The effectiveness of extracorporeal shockwave therapy in common lower limb conditions: a systematic review including quantification of patient-rated pain reduction. *Br J Sports Med.* 2017 Sep 27. pii: bjsports-2016-097347. doi: 10.1136/bjsports-2016-097347.

Startzman AN, Fowler O, Carreira D. Proximal Hamstring Tendinosis and Partial Ruptures. *Orthopedics.* 2017 Jul 1;40(4):e574-e582. doi: 10.3928/0147744720170208-05. Epub 2017 Feb 14

Cacchio A, Rompe JD, Furia JP, Susi P, Santilli V, De Paulis F. Shockwave therapy for the treatment of chronic proximal hamstring tendinopathy in professional athletes. *Am J Sports Med.* 2011 Jan;39(1):146-53. doi: 10.1177/0363546510379324. Epub 2010 Sep 20

## **Ledderhose disease as plantar fibromatosis**

Prof. Dr. Karsten Knobloch

### **Classification**

M72.2 Plantar fibromatosis / M. Ledderhose

### **Aetiology**

Genetic component on modified single-nucleotide-peptides (SNPs) with autosomal dominant inheritance with variable penetrance similar to M. Dupuytren of the hand as palmar fibromatosis

### **Symptoms**

Plantar fibromatosis exclusively with knot formation in the hollow foot area, typically located in a zone from the heel to the Lisfranc joint height and transversely in extension of the first to third metatarsal ray. In addition to the clinical findings of palpation, differential imaging can also help to exclude benign or malignant tumours (sarcoma).

### **Apparative diagnostics**

#### **Sonography**

Sonographically Ledderhose nodes appear similar to Dupuytren nodes of the hand superficially subcutaneously located above the plantar fascia often hypoechogenic, but sometimes also isoechogenic to the surrounding subcutaneous fat. Localisation below (deeper) the plantar fascia suggests another process (e. g. sarcoma, Motolese 2013; Toepfer 2017).

#### **MRI**

The T2 signal of the MRI can possibly indicate the activity of a Ledderhose node as a biomarker and be used prognostically for the irradiation success (Banks et al., 2018).

### **Therapy of the M. Ledderhose**

The therapy of the plantar M. Ledderhose is comparable to the knot-shaped stage of the M. Dupuytren of the hand as palmar fibromatosis.

In the node stage, the following therapy options can be offered for symptomatic painful Ledderhose nodes and suffering:

#### **- Focused**

High-energy ESWT (typically three sessions at intervals of 1 - 2 weeks, follow-up after 6 months as refreshment, Knobloch 2012).

- Plantar radiotherapy (Heyd 2010, Seegenschmiedt 2013 & 2015, Rödel 2017)

Surgical removal is associated with a recurrence rate > 50 %.

## **Shock wave therapy for M. Ledderhose (plantar fibromatosis)**

**Indication:** Indication by a qualified physician.

**Contraindication:** Focus on malignant tumor.

**Room requirements:** Certification criteria of a medical practice e. g. hygiene plan, emergency management available according to DIN standard.

**Patient preparation:** Differentiated and documented education and information.

### **Doctor and assistant staff:**

ESWT is a service to be provided personally by a doctor qualified by means of specialist knowledge.

### **Implementation of the therapy:**

Sitting or lying position according to the patient's wishes.

#### **- Focused:**

ESWT: 0.08 - 0.55 mJ / mm<sup>2</sup> (in individual cases up to 1.24 mJ / mm<sup>2</sup> electromagnetic), 2000 impulses, 3 sessions at weekly intervals, after 6 months if necessary refreshing ESWT once.

High-energy focused electromagnetic ESWT (2000 impulses, up to 1.24 mJ / mm<sup>2</sup>, 3 sessions) reduces pain on a visual analogue scale VAS by 50 % after six weeks and up to 75 % after three months (Knobloch et al. 2012).

### **Literature:**

Banks JS, Wolfson AH, Subhawong TK. T2 signal intensity as an imaging biomarker for patients with superficial fibromatoses of the hands (Dupuytren's disease) and feet (Ledderhose disease) undergoing definitive electron beam irradiation. *Skeletal Radiol* 2018;47(2):243-51.

Carroll P, Henshaw RM, Garwood C, Raspovic K, Kumar D. Plantar fibromatosis: pathophysiology, surgical and nonsurgical therapies: an evidence-based review. *Foot Ankle Spec* 2018 Jan 1.

Heyd R, Forn AP, Herkströter, Rödel C, Müller-Schimpfle M, Fraunholz I. Radiation therapy for early stages of Morbus Ledderhose. *Strahlenther Onkol* 2010;186(1):24-

Knobloch K. Ledderhose's disease – an update on therapeutic options. *MMW Fortschr Med* 2012;154(19):43-4.

Knobloch K, Vogt PM. High-energy focused ESWT reduces pain in plantar fibromatosis (Ledderhose's disease). *BMC Res Notes* 2012;5:542.

Motolese A, Mola F, Cherubino M, Giaccone M, Pellegatta I, Valdatta L. Squamous cell carcinoma and ledderhose disease: a case report. *Int J Low Extrem Wounds* 2013;12(4):297-300.

Rödel F, Fournier C, Wiedemann J, Merz F, Gaipf US, Frey B, Keilholz L, Seegenschmiedt MH, Rödel C, Hehlhans S. Basis of radiation biology when treating hyperproliferative benign diseases. *Front Immunol* 2017;8:519.

Seegenschmiedt MH, Micke O, Niewald M, Mücke R, Eich HT, Kriz J, Heyd R, German Cooperative Group on Radiotherapy of benign diseases. DEGRO guidelines for the radiotherapy of non-malignant disorders: part III: hyperproliferative disorders. *Strahlenther Onkol* 2015;191(7):541-8.

Seegenschmiedt MH, Attassi M. Radiation therapy for Morbus Ledderhose-indication and clinical results. *Strahlenther Onkol* 2013;179(12):847-53.

Toepfer A, Harrasser N, Dreyer F, Mogler C, Walther M, von Eisenhart-Rothe R. Epitheloid sarcoma of the plantar fascia mimicking Morbus Ledderhose – a severe pitfall for clinical and histopathological misinterpretation. *Foot Ankle Surg* 2017;23(4):e25-30.



## **Arthrosis**

Sergej Thiele

M15-M19 n. ICD-10

### **Synonym**

Osteoarthritis

### **Definition**

Degenerative joint disease associated with wear, tear and age and involving the musculoskeletal system. Characterised by degenerative destruction of cartilage and damage to adjacent structures such as bones, muscles, capsules, and ligaments.

### **Aetiology**

Damage to the joint cartilage with preserved mobility, "wear and tear", with an imbalance of load and resilience.

### **Pathogenesis**

Overuse with subsequent matrix degradation (first reversible, then irreversible) accompanying synovialitis, incipient joint mismatch and loss of cartilage substance.

### **Classification**

Kellgren and Lawrence

OARSI

Classification according to Altmann - Differentiation between primary and secondary arthroses

### **Anamnesis**

Insidious onset

Pain and loss of function

Stress pain

### **Diagnostics**

X-ray

MRT

Laboratory diagnostics

### **Differential diagnoses**

Arthritides of the rheumatic group

Infectarthritides

### **Therapy**

Physiotherapy and physical applications

NSAI

Infiltrations

## **Surgical therapies**

Endoprosthesis

Arthroplasty

## **Shock wave therapy**

### **Hypothesis and treatment strategy**

The aim of the treatment is to reduce pain and improve function for individual relief and, if necessary, delay the endoprosthesis treatment. Lee and Han report about an improvement of function and reduction of pain. Wang et al. describe the prevention and treatment of arthrosis in the animal model of the rat knee. Chen et al. have achieved pain reduction in the ESWT group and improvement of the ROM and the Lequesne score in a comparative study of ESWT and ultrasound in patients with knee joint arthrosis. Lee et al. show a positive effect in ESWT treatment on pain and function. Symptoms of discomfort and range of motion can be positively influenced by reduction of NO, increased expression of growth factors such as vWF, VEGF, BMP-2 and osteocalcin, and suppression of metalloproteinases (MMP-1 and MMP-3).

### **Implementation of the therapy:**

- Focused

2000 - 4000 pulses, with 0.25 - 0.6 mJ / mm<sup>2</sup>, at femoral condyle and tibial plateau.

**Localisation:** Palpatory.

### **After the therapy:**

Free movement, avoidance of overstraining stress.

ESWT is a service to be provided personally by a qualified, competent physician.

At present, ESWT cannot be included in the treatment recommendations for osteoarthritis because sufficient data are not yet available. Nevertheless, a recommendation for ESWT in early stages of osteoarthritis, especially for rhizarthrosis and gonarthrosis, can be seen.

Treatment is dependent on the symptoms on the bone / cartilage or on the synovia and capsule and the accompanying structures.

## **Literature:**

Thiele, R., Marx, S. Fallvorstellung der arthroskopisch kontrollierten Therapie der Osteochondrosis dissecans mittels ESWT. *Arthroskopie* 16 (7 2003), 266–271

Dahlberg J1, Fitch G, Evans RB, McClure SR, Conzemius M.; The evaluation of extracorporeal shockwave therapy in naturally occurring osteoarthritis of the stifle joint in dogs. *Vet Comp OrthopTraumatol.* 2005;18(3):147-52.

Ochiai N1, Ohtori S, Sasho T, Nakagawa K, Takahashi K, Takahashi N, Murata R, Takahashi K, Moriya H, Wada Y, Saisu T.; Extracorporeal shock wave therapy improves motor dysfunction and pain originating from knee osteoarthritis in rats. *Osteoarthritis Cartilage.* 2007 Sep;15(9):1093-6. Epub 2007 Apr 26.

Mayer-Wagner S1, Ernst J, Maier M, Chiquet M, Joos H, Müller PE, Jansson V, Sievers B, Hausdorf J. The effect of high-energy extracorporeal shock waves on hyaline cartilage of adult rats in vivo. *J Orthop Res.* 2010 Aug;28(8):1050-6. doi: 10.1002/jor.21074.

Kawcak CE1, Frisbie DD, McIlwraith CW. Effects of extracorporeal shock wave therapy and polysulfated glycosaminoglycan treatment on subchondral bone, serum biomarkers, and synovial fluid biomarkers in horses with induced osteoarthritis. *Am J Vet Res.* 2011 Jun;72(6):772-9. doi: 10.2460/ajvr.72.6.772.

Wang CJ, Sun YC, Wong T, et al.: Extracorporeal shockwave therapy shows time dependent chondroprotective effects in osteoarthritis of the knee in rats. *J Surg Res*, 2012, 178: 196–205.

Zhao Z1, Ji H, Jing R, Liu C, Wang M, Zhai L, Bai X, Xing G. Extracorporeal shockwave therapy reduces progression of knee osteoarthritis in rabbits by reducing nitric oxide level and chondrocyte apoptosis. *Arch Orthop Trauma Surg.* 2012 Nov;132(11):1547-53. doi: 10.1007/s00402-012-1586-4. Epub 2012 Jul 24.

Lee YH, Han EY: A comparison of the effects of PNF, ESWT, and TPI on pain and function of patients with myofascial pain syndrome. *J Phys TherSci*, 2013, 25: 341– 344.

Wang CJ1, Hsu SL, Weng LH, Sun YC, Wang FS. Extracorporeal shockwave therapy shows a number of treatment related chondroprotective effect in osteoarthritis of the knee in rats. *BMC MusculoskeletDisord.* 2013 Jan 28;14:44. doi: 10.1186/1471-247414-44.

Zhao Z1, Jing R, Shi Z, Zhao B, Ai Q, Xing G. Efficacy of extracorporeal shockwave therapy for knee osteoarthritis: a randomized controlled trial. *J Surg Res.* 2013 Dec;185(2):661-6. doi: 10.1016/j.jss.2013.07.004. Epub 2013 Jul 30.

Chen TW1, Lin CW1, Lee CL2, Chen CH2, Chen YJ1, Lin TY1, Huang MH3. The efficacy of shock wave therapy in patients with knee osteoarthritis and popliteal cyst. *Kaohsiung J Med Sci.* 2014 Jul;30(7):362-70. doi: 10.1016/j.kjms.2014.03.006. Epub 2014 Apr 18.

Wang P, Liu C, Yang XT, Wei XF, Zhou YJ, Yang L, He CQ. [Effect of extracorporeal shock wave therapy on cartilage and subchondral bone remodeling in rabbits with ACLT-induced osteoarthritis]. [Article in Chinese]Sichuan Da Xue Xue Bao Yi Xue Ban. 2014 Jan;45(1):120-5.

## **Osteochondrosis dissecans**

Sergej Thiele

M93.2- n. ICD 10

### **Synonyms**

Osteochondrosis dissecans, OD, OCD, subchondral osteonecrosis, dissociating osteochondrosis, joint mouse.

### **Definition**

Osteochondrosis dissecans is a localized disease of joints that usually develops during growth and is classified in the group of aseptic bone necrosis. Segmental infestation of subchondral bone and cartilage above it can lead to the formation of free joint bodies. Mostly convex joint partners, especially femoral condyles and talus shoulder are affected.

### **Aetiology**

Unknown, trauma consequences and perfusion disorders of unknown genesis are discussed. Constitutional factors such as axial misalignments and ligament instabilities must be taken into account.

### **Pathogenesis**

Subchondral necrosis: Initial stage, possibly with induction of reparative processes from surrounding tissue.

Sclerosing or demarcation: Continued stress or other disturbances of the remodelling lead to bone compaction in the border region.

Dissect formation: Demarcation of a chondral - osteochondral fragment with initially still fibrous fixation (dissectate in situ), possibly later solution from the mouse bed (free joint body).

The pathogenetic process can come to a standstill in any phase.

### **Classifications**

Combined classification according to Bruns with arthroscopic, MRT-diagnostic and radiological evaluation.

Radiological classification according to Berndt and Harty.

Criteria for question stability or solution in MRI:

- Greater than 1 cm

- Hyperintensity of surrounding margin greater than 3 mm

- Hypertense fluid signal in fast scan or T2 between lesion and overlying femur

### **Anamnesis**

Pain, swelling tendency, blockage, restricted movement, Givingway

Special anamnesis: physical exertion, previous joint injury, haematological disease, steroid medication.

### **Diagnostics**

Clinical diagnostics, often still unspecific

Apparative diagnostics: X-ray, CT, MRT with KM (Gd)

### **Differential diagnoses**

Osteonecrosis: Perthes's disease, Köhler I and II, femoral head necrosis

Secondary osteonecrosis according to Träume, cortisone injection, meniscus lesion

Osteochondral fractures

Arthrosis

### **Therapy**

Relief, sports leave

Gait training

Movement exercises, especially abduction and internal rotation

Analgesics

NSAIDs

Physiotherapy

Orthotic care for relief

HBO therapy

### **Objective**

Revitalisation of the osteochondral district

Avoidance of progression (dissecondation)

Prevention of arthrosis

### **Shock wave therapy**

**Indication:** Indication by an expert physician. The therapy should be carried out as early as possible, but absolutely before the dissecat is resolved.

**Room requirements:** Certification criteria of a medical practice e. g. hygiene plan, emergency management available in accordance with DIN standard.

**Patient preparation:** Differentiated and documented education and information.

**Physician and assistant staff:** ESWT is a service to be provided personally by a physician qualified by means of specialist knowledge.

**Implementation of the therapy:**

**Documentation:**

Naming the shock wave source and the parameters used.

- High energy, focused

2500 - 3500 pulses, with 0.35 - 0.6 mJ / mm<sup>2</sup>, if possible, at necrosis edge.

**Localisation:** Either arthroscopically or after MRI with anatomical orientation by means of X-ray image converter.

**Anesthesia:** Conduction or general anesthesia.

**Follow-up treatment:**

Relief for 2 - 6 weeks, possibly orthograde loading in orthosis possible.

Follow-up: Magnetic resonance check recommended after 6 and 12 months.

**Literature:**

Lauber S, Ludwig J, Lauber H-J, Hötzing H, Dreisilker U, Rädcl R, Platzek P (2000) MRI after Shockwave Treatment for Osteonecrosis of the Femoral Head In: Coombs R, Schaden W, Zhou S (2000) Musculoskeletal Shockwave Therapy. Greenwich Medical Media Ltd.

Lauber S, Ludwig J, Lauber J, Hötzing J (2001) Die ESWT-Behandlung der Hüftkopfnekrose und Osteochondrosisdissecans. In: Extrakorporale Stoßwellentherapie in der Orthopädie (Siebert W, Buch M [Hrsg.]). ecomed

Thiele, R., Marx, S. Fallvorstellung der arthroskopisch kontrollierten Therapie der Osteochondrosis dissecans mittels ESWT. Arthroskopie 16 (7 2003), 266–271

Thiele, R., Marx, S. Die Behandlung von osteochondralen Läsionen durch ESWT. Orthopädische Praxis 42, 4 (4 2006), 55–59

Moretti, B., Notarnicola, A., Moretti, L., Giordano, P., and Patella, V. A volleyball player with bilateral knee osteochondritis dissecans treated with extracorporeal shock wave therapy. Musculoskeletal Surg 93, 1 (May 2009), 37–41

C.J. Wang, Y.C. Sun, T. Wong, S.L. Hsu, W.Y. Chou, H.W. Chang, Extracorporeal shockwave therapy shows time-dependent chondroprotective effects in osteoarthritis of the knee in rats, J. Surg. Res. 178 (1) (2012 Nov) 196e205.

Lyon R, Liu XC, Kubin M, Schwab J. Does Extracorporeal Shock Wave Therapy Enhance Healing of Osteochondritis Dissecans of the Rabbit Knee, Clin. OrthopRelat Pres (2013) 471:1159-1165

Thiele S., Thiele R, Gerdesmeyer L; Adult Osteochondrotitis dissecans and focused ESWT: A successful treatment option, International Journal of Surgery 24 (2015); 191194



## **Bone marrow edema syndrome**

Sergej Thiele / Dr. Wolfgang Schaden

### **Designation / synonyms:**

Acute bone marrow edema syndrome, bone bruise, transient osteoporosis, transient bone marrow edema, transient marrow edema, bone marrow lesion, migrating bone marrow edema (knee joint).

### **Aetiology, pathogenesis, pathophysiology**

Bone marrow edema is a pathological increase of the interstitial fluid in the bone. Three groups are distinguished and considered for the therapy. A traumatic-ischemic, traumatic-mechanical and atraumatic-reactive bone marrow edema are differentiated according to their cause. Here, the distinction between primary bone marrow edema and secondary bone marrow edema is made as a result of or concomitant to a mechanical disorder, for example. The exact etiology of bone marrow edema remains unclear. It also remains unclear whether it can be understood as an early, potentially reversible stage of osteonecrosis and whether a bone marrow edema results in a stress fracture. First described as hyper-intense regions in T2-weighted MRI images in patients with hip and knee joint pain by Wilson et al. (1988).

Transitory bone marrow edema must first be distinguished from osteonecrosis. Transient osteoporosis is a self-limiting disease that recedes after 6 - 9 months. If the bone continues to be under strain, subchondral insufficiency fractures occur as a result of local osteoporosis, resulting in disruption of microcirculation and localized necrosis as a late consequence of transient bone marrow edema. In the region of the femoral head, the BME shows a transition rate to femoral head necrosis of 1:300.

The disease mostly affects adults of young or middle age (30 - 50 years). Men are affected 3 times more often.

A connection with traumas or inflammations is discussed.

Typical localisation is the femoral head, the femoral condyle and the hindfoot.

In the last trimester, transient osteoporosis occurs more frequently.

In addition to pressure-increasing intraosseous fluid accumulation, cytokines such as prostaglandins, Interleukin1 and TNF- $\alpha$  are secreted by active osteoclasts that create an acidic environment. This exposes and irritates adjacent nerve fiber endings in the bone tissue with characteristic pain triggering.

## **Medical Classification**

Primary idiopathic BMEs: Without evidence of joint damage and transitory bone marrow edema syndrome occurring during pregnancy.

Mechanical BME: After contusions, repetitive overloading with micro- and stress fractures, in traumatic cases also referred to as bone bruise special form: iatrogen-postoperative bone marrow edema after arthroscopic meniscus treatment.

Reactive bone marrow edema: as an accompanying symptom in arthrosis and arthritis, inflammatory genesis in rheumatoid arthritis, tumorous (e. g. multiple myeloma), trophic vasomotor bone marrow edema in CRPS with disorder of vegetative innervation.

Transitory bone marrow edema is considered a special form of ARCO stage 0. In contrast to the ARCO classification, no joint destruction.

## **Anamnesis**

Patients report severe pain and limited mobility. A typical symptom is an intense pain under stress accompanied by a dull continuous pain even at rest.

## **Diagnostics**

### **Apparative diagnostics**

MRI for the safe visualisation of interstitial fluid accumulation with hyper-intense signal in T2-weighted sequences and hypo-intense regions in T1-weighted sequences. Especially the fat suppressing STIR sequences show the typical contrast caused by the increased extracellular fluid. In contrast to necrosis, the lack of a "double line sign" as a demarcation between necrotic and healthy bone.

In BMEs diffuse epiphyseal signal alteration with transition to the metaphysis and blurred limitation. Frequently accompanied by joint effusion and synovial proliferation.

X-ray examination may show localized demineralization after several weeks of clinical symptoms.

Basic laboratory with BB, CRP, blood sedimentation, immune electrophoresis and vitamin D levels recommended.

### **Differential diagnostics**

Osteonecrosis, femoral head necrosis, BME due to tumors.

## **Therapy**

**Targets:** Freedom from pain, restitutio ad integrum.

### **Conservative therapy**

Consistent mechanical relief

Iloprost infusion therapy (to improve perfusion), analgesics, NSAID

Reduction of overweight, improvement of lifestyle (smoking cessation)

Off-label observation studies report positive effects of modern, intravenously administered bisphosphonates (to inhibit osteoclasts)

Physiotherapy, gait training, movement exercises, orthotic care to relieve strain

### **Operative therapy**

Relief drilling / core decompression

### **Shock wave therapy**

**Indication:** Indication by the expert physician after clarification of differential diagnoses and exclusion of contraindications, in particular tumor-associated bone marrow edema.

### **Before therapy:**

**Room requirements:** Certification criteria of a medical practice e. g. hygiene plan, emergency management available according to DIN standard.

**Patient preparation:** Differentiated and documented education and information.

**Doctor and assistant staff:** ESWT is a service to be provided personally by a doctor qualified by means of specialist knowledge.

### **Implementation of the therapy:**

Treatment under general anaesthesia or conduction anaesthesia, positioning of the patient with exposure of the findings, presentation of the area previously localised in the magnetic resonance imaging by X-ray image converter. Localisation of the vascular nerve bundles.

Positioning of the high-energy transducer, 2000 - 4000 impulses, high-energy 0.3 - 0.6 mJ / mm<sup>2</sup> energy flow density, 1 - 5 Hz, 1 - 3 treatments with 1 - 2 weeks interval.

### **Postoperative follow-up:**

Relief for 4 - 6 weeks on crutches, physiotherapeutic mobilization and movement exercises immediately. After 4 - 6 weeks then increasing load up to full load and sport up to pain threshold.

After 12 weeks up to competition sport with no symptoms.

MRI control immediately in case of deterioration otherwise at the earliest after 6 to 12 months, as the MRI remains positive for a long time, even in the absence of symptoms.

## **Documentation:**

Documentation of the treatment parameters. Physician responsible for ESWT.  
For treatments under general or conduction anaesthesia: OP report.

## **Literature:**

Notarnicola, A., Moretti, L., Tafuri, S., Panella, A., Filipponi, M., Casalino, A., Panella, M., Moretti, B. 2010 Shockwave Therapy in the Management of Complex Regional Pain Syndrome of Medial Femoral Condyle of the Knee. *Ultrasound Med Biol.* 2010 Jun;36(6):874-9.

D'Agostino, C., Romeo, P., Lavanga, V., Pisani, S., Sansone, V. (2014) Effectiveness of Extracorporeal Shock Wave Therapy in Bone Marrow Edema Syndrome of the Hip. *Rheumatol Int.* 2014 Mar 23.

Gao, F., Sun, W., Li, Z., Guo, W., Kush, N., Ozaki, K. (2015). Intractable bone marrow edema syndrome of the hip. *Orthopedica.* 2015 Apr;38(4):e263-70

Gao, F., Sun, W., Li, Z., Guo, W., Wang, W., Cheng, L., Yue, D., Zhang, N., Savarin, A. (2015). Extracorporeal shock wave therapy in the treatment of primary bone marrow edema syndrome of the knee: a prospective randomized controlled study. *BMC MusculoskeletDisord.* 2015 Dec 5;16:379.

Gao, F., Sun, W., Li, Z., Guo, W., Wang, W., Cheng, L., Wang, B. (2015) Highenergy Extracorporeal Shock Wave for Early Stage Osteonecrosis of the Femoral Head: A Single-Center Case Series. *Evid Based Complement Alternat Med.* 2015;2015:468090.

Vitali, M., Naim Rodriguez, N., Pedretti, A., Drossinos, A., Pironti, P., Di Carlo, G., and Frascini, G. (2017). Bone marrow edema syndrome of the medial femoral condyle treated with extracorporeal shock wave therapy: A clinical and mri retrospective comparative study. *Arch Phys Med Rehabil.*[Wang et al., 2016] Wang, C.-J., Huang, C.-C., Yip, H.-K., and Yang, Y.-J. (2016). Dosage effects of extra-corporeal shockwave therapy in early hip necrosis. *Int J Surg,* 35:179–186.

Sansone, V., Romeo, P., and Lavanga, V. (2017). Extracorporeal shock wave therapy is effective in the treatment of bone marrow edema of the medial compartment of the knee: A comparative study. *Med PrincPract,* 26(1):23–29.

Gao, F., Chen, N., Sun, W., Wang, B., Shi, Z., Cheng, L., Li, Z., and Guo, W. (2017). Combined therapy with shock wave and retrograde bone marrow-derived cell transplantation for osteochondral lesions of the talus. *Sci Rep,* 7(1):2106.

Kang, S., Gao, F., Han, J., Mao, T., Sun, W., Wang, B., Guo, W., Cheng, L., and Li, Z. (2018). Extracorporeal shock wave treatment can normalize painful bone marrow edema in knee osteoarthritis: A comparative historical cohort study. *Medicine (Baltimore),* 97(5):e9796.

Sansone, V., Maiorano, E., Pascale, V., and Romeo, P. (2018). Bone marrow lesions of the knee: longitudinal correlation between lesion size changes and pain before and after conservative treatment by extracorporeal shockwave therapy. *Eur J PhysRehabil Med*

## **Pseudarthrosis & Delayed healing bone fractures**

Dr. Wolfgang Schaden

ICD-10 (version 2011): M-84.1, M-84.2

### **Classification**

Pseudarthrosis: No bone healing > 6 to 9 months

Delayed fracture healing: No bone healing 3 - 6 months after fracture / OP

### **Synonyms**

False joint, non-union, delayed union.

### **Aetiology**

Interposition of soft tissues in the fracture gap

Dislocation or distraction (insufficient contact of the fragments), inadequate immobilization or early mobilization, insufficient blood supply, infection

Systemic diseases (diabetes mellitus, arterial occlusive disease, cortisone, smoking, etc.).

### **Symptoms**

Pain due to bending and compression, pain due to strain and relief, swelling, redness, overheating, (abnormal mobility).

### **Apparative diagnostics**

(Combination of imaging procedures) X-ray, CT, (MRT).

### **Differential Diagnosis**

Osteomyelitis, pathological fracture, congenital anomalies, stress fracture.

### **Shock wave therapy**

**Indication:** Non-connected fracture without significant dislocation as defined above, without progression in the course of X-ray control, persistent fracture gap. In the case of long tubular bones, the success rate decreases with a fracture gap > 5 mm.

Indication by a qualified physician.

### **Contraindication:**

Epiphyseal joint in focus

Brain tissue or spinal cord in focus

Tumor tissue in focus

Lung tissue in focus

Significant coagulopathy (check coagulation status)

**Room requirements:** Possibility of regional or general anaesthesia X-ray location.

Certification criteria of a medical practice e. g. hygiene plan, emergency management available according to DIN standard.

**Patient preparation:** Differentiated and documented education and information.

**Documentation:** Naming the shock wave source and the parameters used.

**Doctors and assistants:** ESWT is a service to be provided personally by a qualified doctor.

**Implementation of the therapy:**

Conduction anaesthesia / general anaesthesia, stable positioning of the patient / extreme.

Coupling medium: Ultrasonic gel if necessary vaseline / castor oil.

Positioning: Radiological, (ultrasound).

Avoidance of large vessels / nerves in focus.

Electrohydraulic:

Single treatment, after 3 to 6 months second or third treatment possible

Frequency 1 - 4 Hz

3000 (2000 - 4000) pulses

EFD: 0.3 - 0.4 mJ / mm<sup>2</sup>

Electromagnetic:

3 to 4 treatments; in 3 to 7 days interval

Frequency 1 - 4 Hz

4000 pulses

EFD: 0.4 - 0.7 mJ / mm<sup>2</sup> (long tubular bones); 0.1 mJ / mm<sup>2</sup> (navicular bone)

Piezoelectric:

No reference literature available (according to preamble).

Radial:

No reference literature available (according to preamble).

**Complications:**

Temporary hematoma discoloration, pain intensification, nerve irritation, absence of bony connectedness.

**After therapy:**

After ESWT, the pseudarthrosis should be immobilised exactly between 3 and 5 weeks, depending on the localisation, in order not to endanger the newly sprouted in capillaries (this can result in relief for this period, especially in the area of the lower extremity).

In the case of lying osteosynthesis material without clinical and / or radiological signs of loosening, no further measures are necessary apart from protection.

For loosened implants and conservatively pre-treated fractures, fixation should be applied in accordance with the guidelines for conservative bone fracture treatment. In the case of particularly mobile pseudarthrosis, especially in the lower leg area, an external fixator must also be applied in individual cases. In the case of fractures that are not at risk of dislocation,

X-ray examinations every four weeks are sufficient (otherwise at correspondingly shorter intervals).

### **Literature:**

Publications with evidence levels from Ib to IIb (Pubmed27.04.2018):

Cacchio, A., Giordano, L., Colafarina, O., Rompe, J. D., Tavernese, E., Ioppolo, F., Flamini, S., Spacca, G., and Santilli, V. Extracorporeal shock-wave therapy compared with surgery for hypertrophic long-bone nonunions. *J Bone Joint Surg Am* 91, 11 (Nov 2009), 2589–97.

Furia, J. P., Juliano, P. J., Wade, A. M., Schaden, W., and Mittermayr, R. Shock wave therapy compared with intramedullary screw fixation for nonunion of proximal fifth metatarsal metaphyseal-diaphyseal fractures. *J Bone Joint Surg Am* 92, 4 (Apr 2010), 846–54.

Stojadinovic, A., Kyle Potter, B., Eberhardt, J., Shawen, S. B., Andersen, R. C., Forsberg, J. A., Shwery, C., Ester, E. A., and Schaden, W. Development of a prognostic naive bayesian classifier for successful treatment of nonunions. *J Bone Joint Surg Am* 93, 2 (Jan 2011), 187–94.

Notarnicola, A., Moretti, L., Tafuri, S., Gigliotti, S., Russo, S., Musci, L., and Moretti, B. Extracorporeal shockwaves versus surgery in the treatment of pseudoarthrosis of the carpal scaphoid. *Ultrasound Med Biol* 36, 8 (Aug 2010), 1306–13.

Other publications:

Haupt, G., et al.: Enhancement of fracture healing with extracorporeal shock waves. AUA Annual Meeting, New Orleans 1990.

Valchanov, V. D. and Michailov, P.: High energy shock waves in the treatment of delayed and non-union of fractures. *IntOrthop* 15, 3 (1991), 181–184.

Beutler S, Regel G, Pape HC, Machtens S, Weinberg AM, Kremeike I, Jonas U, Tscherne H.: Extracorporeal shock wave therapy for delayed union of long bone fractures - preliminary results of a prospective cohort study. *Unfallchirurg*. 1999 Nov;102(11):839-47

Ikeda K, Tomita K, Takayama K.: Application of extracorporeal shock wave on bone: preliminary report. *J Trauma*. 1999 Nov;47(5):946-50.

Rompe JD, Rosendahl T, Schvöllner C, Theis C. High-energy extracorporeal shock wave treatment of non-unions. *ClinOrthopRelat Res*. 2001 Jun;(387):102-11

Wang CJ, Chen HS, Chen CE, Yang KD.: Treatment of non-unions of long bone fractures with shock waves. *ClinOrthopRelat Res*. 2001 Jun;(387):95-101.

Schaden W, Fischer A, Sailler A.: Extracorporeal shock wave therapy of non-union or delayed osseous union. *ClinOrthopRelat Res*. 2001 Jun;(387):90-4.

Wang FS, Yang KD, Wang CJ, Huang HC, Chio CC, Hsu TY, et al. Shockwave stimulates oxygen radical-mediated osteogenesis of the mesenchymal cells from human umbilical cord blood. *J Bone Miner Res* 2004 Jun;19(6):973-82.

Chen YJ, Kuo YR, Yang KD, Wang CJ, Sheen Chen SM, Huang HC, et al. Activation of extracellular signal-regulated kinase (ERK) and p38 kinase in shock wavepromoted bone formation of segmental defect in rats. *Bone* 2004 Mar;34(3):466-77.

Wang CJ, Liu HC, Fu TH.: The effects of extracorporeal shockwave on acute highenergy long bone fractures of the lower extremity. *Arch Orthop Trauma Surg.* 2007 Feb;127(2):137-42

Bara T, Synder M.: Nine-years experience with the use of shock waves for treatment of bone union disturbances. *OrtopTraumatolRehabil.* 2007 May-Jun;9(3):254-8.

Wang CJ, Wang FS, Yang KD: Biological effects of extracorporeal shockwave in bone healing: a study in rabbits. *Archives of orthopaedic and trauma surgery* 2008, 128:879-884

Xu ZH, Jiang Q, Chen DY, Xiong J, Shi DQ, Yuan T, et al. Extracorporeal shock wave treatment in nonunions of long bone fractures. *IntOrthop* 2009 Jun;33(3):78993.

Xu ZH, Jiang Q, Chen DY, Xiong J, Shi DQ, Yuan T, Zhu XL.: Extracorporeal shock wave treatment in non-unions of long bone fractures. *IntOrthop.* 2009 Jun;33(3):78993.

Wang CJ, Yang KD, Ko JY, Huang CC, Huang HY, Wang FS.: The effects of shockwave on bone healing and systemic concentrations of nitric oxide (NO),TGFbeta1, VEGF and BMP-2 in long bone non-unions. *Nitric Oxide.* 2009 Jun;20(4):298303.

Elster EA, Stojadinovic A, Forsberg J, Shawen S, Andersen RC, Schaden W.: Extracorporeal shock wave therapy for non-union of the tibia. *J Orthop Trauma.* 2010 Mar;24(3):133-41.

Zelle B A, Gollwitzer H, Zlowodzki M, Buhren V: Extracorporeal Shock Wave Therapy: Current Evidence.*J Orthop Trauma* 2010;24:S66–S70

Furia, J. P., Rompe, J. D., Cacchio, A., and Maffulli, N. Shock wave therapy as a treatment of non-unions, avascular necrosis, and delayed healing of stress fractures. *Foot Ankle Clin* 15, 4 (Dec 2010), 651–62.

Cacchio A, Giordano L, Colafarina O, Rompe JD, Tavernese E, Ioppolo F, Flamini S, Spacca G, Santilli V. Extracorporeal shock-wave therapy compared with surgery for hypertrophic long-bone non-unions. *J Bone Joint Surg Am.* 2010 May;92(5)

Ayeni OR, Busse JW, Bhandari M.: Using extracorporeal shock-wave therapy for healing long-bone non-unions. *Clin J Sport Med.* 2011 Jan;21(1):74-5.

Stojadinovic A, Kyle Potter B, Eberhardt J, Shawen SB, Andersen RC, Forsberg JA, Shwery C, Ester EA, Schaden W.: Development of a prognostic naive Bayesian classifier for successful treatment of non-unions. *J Bone Joint Surg Am.* 2011 Jan;93(2):187-94.



Xu JK, Chen HJ, Li XD, Huang ZL, Xu H, Yang HL, et al. Optimal intensity shock wave promotes the adhesion and migration of rat osteoblasts via integrin beta1 mediated expression of phosphorylated focal adhesion kinase. *J BiolChem* 2012 Jul 27;287(31):26200-12.

Sun D, Junger WG, Yuan C, Zhang W, Bao Y, Qin D, et al. Shockwaves induce osteogenic differentiation of human mesenchymal stem cells through ATP release and activation of P2X7 receptors. *Stem Cells* 2013 Jun;31(6):1170-80

Schaden W, Mittermayr R, Haffner N, Smolen D, Gerdesmeyer L, Wang C-J, Extracorporeal shockwave therapy (ESWT) e First choice treatment of fracture nonunions? *International Journal of Surgery* 24 (2015) 179 – 183

Alkhashki H M I, Shock wave therapy of fracture nonunion. (2015). *Injury*, 46(11):2248–52  
Kertzman P, Lenza M, Pedrinelli A, Ejnisman B, Shockwave treatment for musculoskeletal diseases and bone consolidation: qualitative analysis of the literature. (2015). *Rev Bras Ortop*, 50(1):3–8.

Kuo S-J, Su I-C, Wang C-J, Ko J-Y, Extracorporeal shockwave therapy (eswt) in the treatment of atrophic non-unions of femoral shaft fractures. (2015). *Int J Surg*, 24(Pt B):131–134.

Everding J, Freistühler M, Stolberg-Stolberg J, Raschke M J, Garcia P, Extracorporeal shock wave therapy for the treatment of pseudarthrosis: New experiences with an old technology. *Der Unfallchirurg*. (2016).

Zhai L, Ma X-L, Jiang C, Zhang B, Liu S.-T, Xing G-Y, Human autologous mesenchymal stem cells with extracorporeal shock wave therapy for nonunion of long bones. *Indian J Orthop*, 2016 50(5):543–550.

Haffner N, Antonic V, Smolen D, Slezak P, Schaden W, Mittermayr R, Stojadinovic A, Extracorporeal shockwave therapy (eswt) ameliorates healing of tibial fracture nonunion unresponsive to conventional therapy. (2016) *Injury*, 47(7):1506–13.

## **Stress fractures**

Dr. Wolfgang Schaden

ICD-10: M-84.3

### **Synonyms**

Fatigue fractures, march fractures.

### **Aetiology**

Local overuse of the bony structures due to unusual external stress factors.

### **Symptoms**

Local pressure pain, redness, swelling, bending and exertion pain.

### **Apparative diagnostics**

(combination of imaging procedures)

X-ray

CT

MRT

### **Differential diagnosis**

Osteomyelitis

Pathological fracture

Congenital anomalies

Bone marrow edema

### **Conservative therapy**

Immobilization

Relief

Pulsating ultrasound

Magnetically induced electrotherapy

### **Operative therapy**

Debridement of the fracture (spongiosaplasty)

Osteosynthesis

## **Shock wave therapy**

**Indication:** Indication by a physician.

### **Contraindication:**

Epiphyseal joint in focus

Tumor tissue in focus

Significant coagulopathy (control coagulation status)

**Room requirements:** Possibility of regional or general anaesthesia, X-ray localisation.

Certification criteria of a medical practice, e.g. hygiene plan, emergency management available according to DIN standard.

**Patient preparation:** Differentiated and documented education and information.

### **Implementation of the therapy:**

The ESWT is a service to be provided by the qualified physician in the form of anesthesia of the line or general anesthesia.

Stable positioning of the patient / the extremity.

Naming of the SW source.

Coupling medium ultrasound gel if necessary vaseline / castor oil.

**Localisation:** Radiological.

#### Electrohydraulic:

Single treatment, after 3 to 6 months second or third treatment possible

Frequency 1- 4 Hz

3000 (2000 - 4000) pulses

EFD: 0.3 - 0.4 mJ / mm<sup>2</sup>

#### Electromagnetic:

2 to 4 treatments; in 3 to 7 days interval

Frequency 1- 4 Hz

4000 pulses EFD: 0.4 - 0.7 mJ / mm<sup>2</sup>

#### Piezoelectric:

No reference literature available (according to preamble)

#### Radial:

No reference literature available (according to preamble)

### **Complications:**

Temporary haematoma discoloration, temporary pain enhancement, nerve irritation, absence of bony connection.

Pseudarthrosis.

### **After therapy:**

After ESWT, the stress fracture should be relieved between 4 and 6 weeks, depending on localisation. Active movement exercises without stress can be started immediately.

In patients with questionable compliance, fixation in plaster or plastic dressings is indicated. Since the patients with stress fractures are often top athletes who immediately resume their full training program when their symptoms decrease, which often occurs immediately after ESWT, special attention must be paid to compliance.

The healing process is primarily assessed by clinical development, but can be proven somewhat delayed in appropriate imaging procedures.

### **Literature:**

Saunier J, Chapurlat R, Stress fracture in athletes. 2017 May 13. pii: S 1297-319 Joint Bone Spine.

Leal C, D'Agostino C, Garcia S G, Fernandez A, Current concepts of shockwave therapy in stress fractures, International Journal of Surgery 24 (2015) 1 – 6

Audain R, Alvarez Y, Perez N, Barrios G, Focused shockwaves in the treatment and prevention of tibial stress fractures in athletes, in: Transactions of the ISMST 15th International ISMST Congress, Cartagena, 2012.

Abello S, Leal C, ESWT in foot navicular stress fracture of a high performance athlete, in: Transactions of the ISMST 14th International ISMST Congress Kiel, 2011.

Furia, J. P., Rompe, J. D., Cacchio, A., and Maffulli, N. Shock wave therapy as a treatment of non-unions, avascular necrosis, and delayed healing of stress fractures. Foot Ankle Clin 15, 4 (Dec 2010), 651–62.

Moretti B, Notarnicola A, Garofalo R, Shock waves in the treatment of stress fractures, Ultrasound Med. Biol. 35 (2009) 1042 - 1049.

Moretti B, Notarnicola A, Marlinghaus E, Garofalo R, Moretti L, Patella S, Patella V, ESWT in stress fractures, in: Transactions of the 12th International ISMST Congress, June 2009

Knobloch K, Schreibmueller L, Jagodzinski M, Zeichen J, Krettek C, Rapid rehabilitation program following sacral stress fracture in a long-distance running female athlete, Arch. Orthop. Trauma Surg. 127 (9) (2007) 809 - 813.

Taki M, Iwata O, Shiono M, Extracorporeal shock wave therapy for resistant stress fractures in athletes, Am. J. Sports Med. 35 (2007) 1188 - 1192.

Leal C, Shockwave biosurgery for stress fractures, in: Transactions of the ISMST 9th International ISMST Congress, Rio de Janeiro, 2006.

Herrera J M, Leal C, Murillo M, Duran R, Lopez J C, Reyes O E, Treatment of tibial stress fractures in high performance athletes with extracorporeal shockwave lithotripsy, Rev. la Soc. Colomb. CirugiaOrtop. Traumatol. SCCOT 19 (1) (2005) (in Spanish).

Leal C, Herrera J M, Murillo M, Duran R, Reyes O E, Lopez J C, Extracorporeal shockwave therapy in tibial stress fractures, in: Abstracts of the International Society of Arthroscopy Knee Surgery and Orthopedic Sports Medicine ISAKOS Biennial Congress, Hollywood USA, Apr 2005.

Audain R, Maggiore G, Herrera J, Almao M, A clinical case of treating stress fractures with ESWT, in: Transactions of the ISMST 6th International ISMST Congress, Orlando, 2003.

Gordon R, Lynagh L, ESWT treatment of stress fractures, in: Transactions of the ISMST 5th International ISMST Congress, Winterthur, 2002.

Leal C, Herrera J M, Murillo M, Duran R, Reyes O E, Lopez J C, ESWT in high performance athletes with tibial stress fractures, in: Transactions of the ISMST 5th International ISMST Congress, Winterthur, 2002.

Hotzinger A, Radelberger L, Lauber U S, Lauber H, Platzekc P, Ludwig J, MRI guided SWT of multiple stress fractures of the tibia, in: Transactions of the ISMST 2nd International ISMST Congress, London, 1999.

Audain Roberto, Maggiore Giovanni, Herrera Jesus, Almao Miguel, Clinical Case of Treating Stress Fractures with ESWT, Presentation 6th Congress of the ISMST, Orlando, USA,

## **Aseptic femoral head necrosis**

Dr. Wolfgang Schaden

ICD-10: M97.0

### **Aetiology, pathogenesis, pathophysiology**

The etiology has not yet been clarified, a vascular risk due to a subcritical vascular supply at predilection age, constitutional influences, possible multiple bone infarctions are discussed.

The disease occurs particularly in humans and domestic dogs. The exact causes have not been fully clarified, but hip head necrosis is common in diabetes mellitus and alcoholism. Longer treatment with anticoagulants can also result in necrosis of the femoral head. Head necrosis can occur after injury to the femoral head. This is referred to as post-traumatic femoral head necrosis. Typical is the necrosis of the femoral head after shearing of the femoral head with traumatic dislocation of the hip.

Without any obvious cause, such as an accident, a hip suddenly begins to hurt. The mobility of the joint is limited, mostly the internal rotation and stretching is inhibited. The normal X-ray image often cannot show any pathological changes in the first stage, only the examination with the MRI (also with contrast medium) shows the change of the metabolic position in the diseased bone in the early stage.

### **Medical Classification**

#### **Stadium classification according to ARCO**

##### Stage A0:

Pain in the hip without verifiable signs in X-ray, CT, scintigram or MRI.

##### Stage A1:

X-rays and CT are normal, MRI shows a change in the medial femoral head below 15 % of surface area.

##### Stage A2:

No sickle sign, sclerosing, osteolysis and focal porosis in X-rays, area 15 - 30 %.

##### Stage A3:

Sickle sign on X-ray, in nuclear spin and CT more than 30 % surface affected.

##### Stage A4:

Osteoarthritis, signs of arthrosis in X-rays, narrowing of the joint space, alteration of the acetabula, destruction of the joint.

### **Anamnesis**

Special anamnesis: Knee pain, limping, running laziness, fatigue, pain intervals, alcohol consumption, metabolic pathologies, medication anamnesis, sickle cell anemia.

General anamnesis: Family history, hip dysplasia, infection.

### **Diagnostics**

**Apparative diagnostics:** See above.

**Differential diagnosis:** Bacterial coxitis, tumor diseases, coxarthrosis.

### **Therapy**

**Objectives:** Preservation of the femoral head, freedom from pain and mobility.

#### **Conservative therapy:**

Iloprost infusion therapy, analgesics, NSAIDs, physical therapy, gait training, movement exercises, especially abduction and internal rotation, stress reduction, orthosis treatment for relief, HBO therapy, electromagnetic transduction therapy (EMTT).

#### **Surgical therapy:**

In stage I and II drilling for decompression, in stage III and IV joint replacement, hip endoprosthesis.

### **Shock wave therapy**

**Indication:** Indication by the expert physician.

#### **Before therapy:**

**Room requirements:** Certification criteria of a medical practice e. g. hygiene plan, emergency management available according to DIN standard.

**Patient preparation:** Differentiated and documented education and information.

**Doctor and assistant staff:** ESWT is a service to be provided personally by a doctor qualified by means of specialist knowledge.

#### **Implementation of the therapy:**

Treatment under general anaesthesia or conduction anaesthesia, positioning of the patient with exposure of the findings (external rotation and extension), presentation of the area previously localised in the magnetic resonance imaging with gadolinium using X-ray image converters. Localisation of the vascular nerve bundles.

Shock wave source:

- High-energy, focused

Positioning of the high-energy transducer

4000 - 6000 pulses, high-energy 0.35 - 0.6 mJ / mm<sup>2</sup> energy flux density

1 - 3 treatments at 12 weeks intervals

**Postoperative follow-up:**

Relief for 6 weeks on crutches, physiotherapeutic mobilisation and movement exercises, then increasing stress up to competitive sport with no complaints. MRI control immediately upon deterioration, otherwise at the earliest after 6 to 12 months, as the MRI remains positive for a long time, even in the absence of symptoms.

**Documentation:**

Documentation of shock wave source and treatment parameters: Physician responsible for ESWT.

For treatments under general or conduction anaesthesia: OP report.

**Literature:**

D.S. Hungerford, [Role of core decompression as treatment method for ischemic femur head necrosis], *Orthopade* 19 (1990) 219 – 223

J. Ludwig, S. Lauber, H.J. Lauber, U. Dreisilker, R. Raedel, H. Hotzinger, Highenergy shock wave treatment of femoral head necrosis in adults, *Clin. Orthop. Relat. Res.* (2001) 119 - 126.

C.J. Wang, F.S. Wang, C.C. Huang, K.D. Yang, L.H. Weng, H.Y. Huang, Treatment for osteonecrosis of the femoral head: comparison of extracorporeal shock waves with core decompression and bone-grafting, *J. Bone Jt. Surg. Am.* 87 (2005) 2380 - 2387.

M.C. Vulpiani, M. Vetrano, D. Trischitta, L. Scarcello, F. Chizzi, G. Argento, V.M. Saraceni, N. Maffulli, A. Ferretti, Extracorporeal shock wave therapy in early osteonecrosis of the femoral head: prospective clinical study with longterm follow-up, *Archives Orthop. Trauma. Surg.* 132 (2012) 499 - 508.

C.J. Wang, F.S. Wang, J.Y. Ko, H.Y. Huang, C.J. Chen, Y.C. Sun, Y.J. Yang, Extracorporeal shockwave therapy shows regeneration in hip necrosis, *Rheumatology*, 47 (2008) 542 - 546.

J.M. Chen, S.L. Hsu, T. Wong, W.Y. Chou, C.J. Wang, F.S. Wang, Functional outcomes of bilateral hip necrosis: total hip arthroplasty versus extracorporeal shockwave, *Archives Orthop. Trauma. Surg.* 129 (2009) 837 - 841.



D. Kusz, A. Franek, R. Wilk, P. Dolibog, E. Blaszcak, P. Wojciechowski, P. Krol, B. Kusz, The effects of treatment the avascular necrosis of the femoral head with extracorporeal focused shockwave therapy, *Ortop. Traumatol. Rehabil.* 14 (2012) 435 - 442.

C.J. Wang, C.C. Huang, J.W. Wang, T. Wong, Y.J. Yang, Long-term results of extracorporeal shockwave therapy and core decompression in osteonecrosis of the femoral head with eight- to nine- year follow-up, *Biomed. J.* 35 (2012) 481 - 485.

C.J. Wang, F.S. Wang, K.D. Yang, C.C. Huang, M.S. Lee, Y.S. Chan, J.W. Wang, J.Y. Ko, Treatment of osteonecrosis of the hip: comparison of extracorporeal shockwave with shockwave and alendronate, *Archives Orthop. Trauma. Surg.* 128 (2008) 901 - 908.

P.C. Lin, C.J. Wang, K.D. Yang, F.S. Wang, J.Y. Ko, C.C. Huang, Extracorporeal shockwave treatment of osteonecrosis of the femoral head in systemic lupus erythematosus, *J. Arthroplasty* 21 (2006) 911 - 915.

C.-J. Wang, J-H Cheng, C.-C. Huang, H.-K. Yip, S. Russo, Extracorporeal shockwave therapy for avascular necrosis of femoral head, *International Journal of Surgery* 24 (2015) 113 - 119

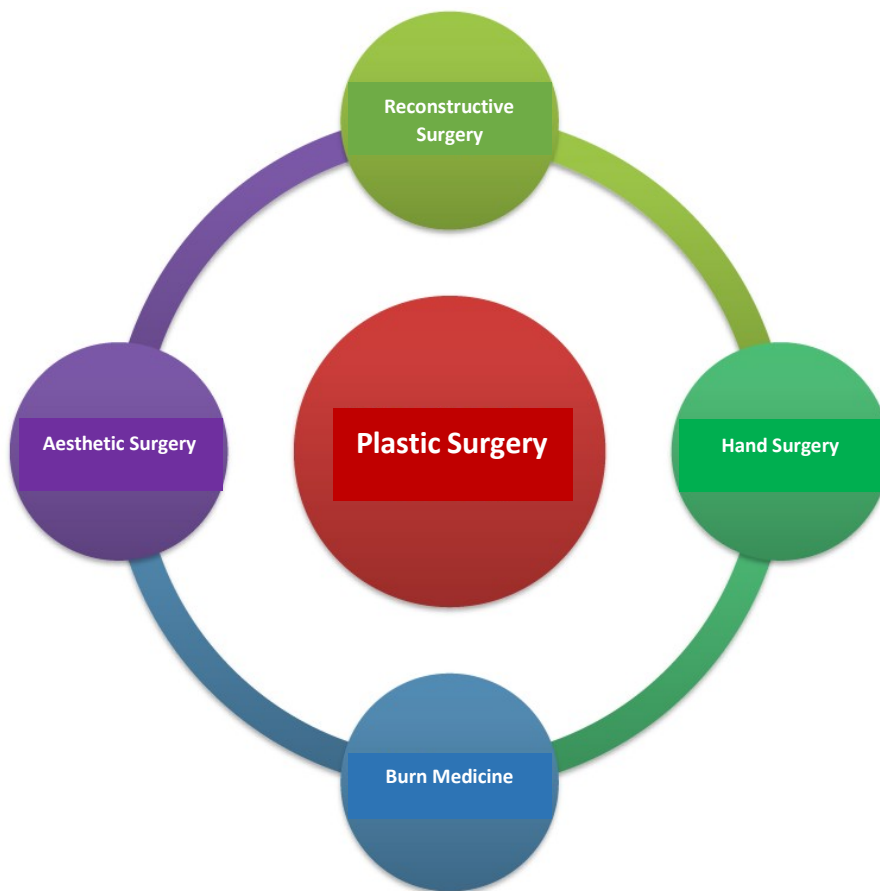
## **ESWT on the skin**

Prof. Dr. Karsten Knobloch

### **Introduction**

The application of ESWT to the skin has been published both clinically and experimentally for different indications. The skin is also an excellent model for investigating the multiple effects that ESWT can trigger.

Plastic surgery is based on the following four pillars:



For all four aforementioned pillars of plastic surgery, both experimental and clinical data are now available, some of which are randomized controlled studies.

The detailed analysis of these reports greatly enhances our understanding of the potential effects of ESWT. For example, burn medicine is a focus in this context, where skin healing after a burn injury heals significantly faster under ESWT if it is a dermal 2a° burn. The healing of a defined surgical wound is also positively influenced by ESWT, which was excellently demonstrated by Ottomann's randomized controlled study of split skin sites.

## **ESWT for burn injuries & scars**

The German Association for Combustion Medicine (DAV) has published an AWMF Guideline on Combustion Medicine, which is reproduced here in part.

### **Definition burn injury of the skin**

Thermal or chemical influences cause damage to the skin to varying depths, which leads to partial or complete death of the skin.

### **Burn-in depths of the skin**

<b>Classification</b>	<b>Clinical picture</b>	<b>Burning depth</b>
First-degree	Reddening	Superficial epithelial damage without cell death
Second-degree b	Blistering red ground very painful	Damage to the epidermis and superficial parts of the dermis with sequestration
Second-degree b	Blistering light ground painful	Extensive damage to the dermis while preserving the hair follicles and glandular appendages
Third-degree	Epidermis fragments tissue White after cleansing No pain	Complete destruction of epidermis and dermis
Fourth-degree	Carbonization lysis (in case of chemical damage)	Destruction of extensive layers with subcutaneous fat tissue, possibly muscles, tendons, bones and joints

### **Assessment of burning depth**

The severity of a burn injury is determined by the extent and depth of the burnt surface. Accompanying injuries further intensify the trauma.

- a) Calculation of the burnt surface according to the rule of nine and / or palm rule
- b) Depth of the injury
- c) Further internal burns / chemical burns / toxic damage (e. g. inhalation trauma (frequent), acid / alkaline injection)
- d) Accompanying injuries (fractures)

### **Transfer into fire injury centres**

- All patients with burns on face / neck, hands, feet, ano-genital region, armpits, areas above large joints or other complicated localization
- Patients with more than 15 % second-degree burnt body surface
- Patients with more than 10 % third-degree burnt body surface
- Patients with accompanying mechanical injuries
- All patients with inhalation damage
- Patients with pre-existing conditions or age under 8 years or over 60 years
- All patients with electrical injuries

### **Wound treatment**

- First-degree and 2a-degree burns are treated conservatively
- 2b-degree and deeper burns should be treated surgically as early as possible, depending on the overall condition of the injured person (necrosis removal, rapid skin transplantation)

For the ESWT, the following experimental and clinical data are available, in particular for split skin removal site healing and 2a° burn as well as burn scars.

### **Experimental data ESWT for burns**

- Second degree burns re-epithelialize significantly faster in the rat model after single focused ESWT (0.11 mJ / mm<sup>2</sup>, 500 impulses, 4 Hz, Djedovic et al., 2014)
- TGFβ1, alpha-smooth muscle actin, collagen-I, fibronectin and twist-1 are re-epithelialized significantly faster in the rat model after focalization. ESWT (0.03 - 0.3 mJ / mm<sup>2</sup>, 1000 impulses) in dermal fibrocytes reduced in hypertrophic scar tissue (Cui et al., 2018)
- The early proinflammatory immune response 1 h of severe cutaneous burn is reduced by ESWT (Davis et al., 2009)
- (de)focused ESWT improves tissue necrosis of skin flaps by improved angiogenesis (Mittermayr et al., 2011)
- Cutaneous tissue oxygen saturation is significantly increased after high-energy focused ESWT in the rat animal model (Kraemer et al., 2016)
- Cutaneous skin perfusion is significantly increased after high-energy focused ESWT in the rat animal model (Kraemer et al., 2016)
- Cutaneous skin perfusion is significantly increased after high-energy focused ESWT in rat animal model (Kraemer et al., 2016)
- Contralateral tissue oxygen saturation is significantly increased in the rat animal model (Kisch et al., 2015) after unilateral high energy focused ESWT on the opposite leg (remote)
- The contralateral cutaneous skin perfusion is significantly increased after unilateral high energy focused ESWT on the opposite leg (remote) in the rat animal model (Kisch et al., 2015)
- Repeated ESWT sessions improve angiogenesis in full-layer skin burns more than a single ESWT session (Goertz et al., 2012, Goertz et al., 2014)

## Clinical data ESWT for burns

The ESWT is applied so far in clinical published studies on the following aspects:

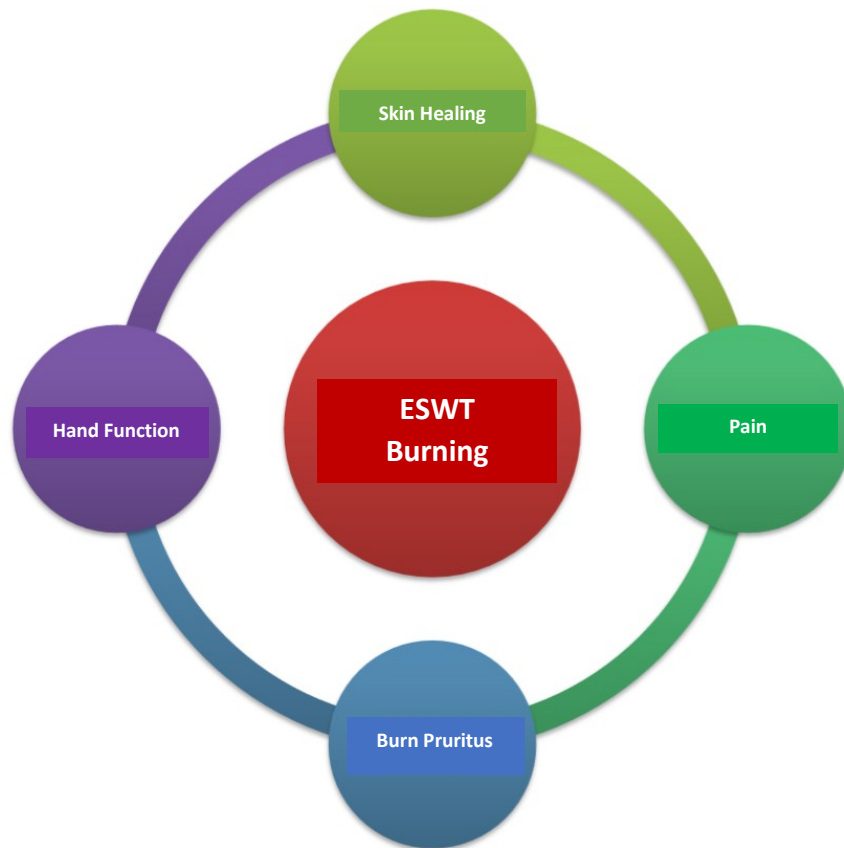


Figure: Primary target parameters of clinical studies on ESWT in burn injuries.

### **Burn scars healing**

- (De)focused ESWT can significantly accelerate wound healing in 2a° burns (superficial dermal) (LoE 1b, Ottomann et al., 2012)
- ESWT improves wound healing in 2° burns with improved perfusion measured with LaserDoppler (LoE 3, Arno et al. 2010)
- Split skin removal sites heal significantly faster after single preventive (de)focused ESWT before surgery (LoE 1b, Ottomann et al, 2010)
- The burn scar image can be improved by the (de)focused ESWT
- Die Narbenkeloidhöhe wie auch die Narbenfunktion kann durch die dreimalige Stosswellentherapie signifikant verbessert werden (Wang et al. 2018)

### **Burn scars pain**

- Burn scar pain can be significantly reduced from  $7.8 \pm 1.5$  to  $3.8 \pm 2.4$  by triple focused ESWT (electromagnetic  $0.05 - 0.15 \text{ mJ} / \text{mm}^2$ , 2000 impulses, three sessions, 4 Hz) (RCT, n = 40, Cho et al., 2016)

## **Burn scars pruritus**

- Burn scar itching can be significantly reduced by triple focused ESWT (0.05 - 0.2 mJ / mm<sup>2</sup>, 2000 pulses, electromagnetic) ( $6.3 \pm 1.3$  to  $3.6 \pm 2$ ,  $p < 0.001$ , Yoo et al., 2017)

## **Burn scars hand function**

- Hand function with retracting burn scars improved by (de)focused ESWT (Vancouver Scar Scale, Saggini et al. 2016)

## **Literature:**

### **Experimental:**

Cui HS, Hong AR et al. ESWT alters the expression of fibrosis-related molecules in fibroblast derived from human hypertrophic scar. *Int J Mol Sci* 2018 Jan 2;19(1):e124.

Davis TA, Stojadinovic A, Anam K, Amare K, Amare M, Naik S, Peoples GE, Tadaki D, Elster EA. Extracorporeal shock wave therapy suppresses the early proinflammatory immune response to a severe cutaneous burn injury. *Int Wound J* 2009;66(1):11-21.

Djedovic G, Kamelger FS, Jeschke J, Piza-Katzer H. Effect of ESWT on deep partial thickness burn injury in rats: a pilot study. *Plast Surg Int* 2014;2014:495967.

Goertz O, Lauer H, Hirsch T, Ring A, Lehnhardt M, Langer S, Steinau HU, Hauser J. Extracorporeal shock waves improve angiogenesis after full thickness burn. *Burns* 2012;38(7):1010-8.

Goertz O, von der Lohe L, Lauer H, Khosrawipour T, Ring A, Daigeler A, Lehnhardt M, Kolbenschlag J. Repetitive extracorporeal shockwave applications are superior in inducing angiogenesis after full thickness burn compared to single application. *Burns* 2014;40(7):1365-74.

Kraemer R, Sorg H, Forstmeier V, Knobloch K, et al. Immediate-dose-response effect of high-energy versus low-energy ESWT on cutaneous microcirculation. *Ultrasound Med Biol* 2016;42(12):2975-82.

Kisch E, Sorg H, Forstmeier V, Knobloch K et al. Remote effects of ESWT on cutaneous microcirculation. *J Tissue Viability* 2015;24(4) :140-5.

Mittermayr R, Hartinger J, Antonic V, Meinel A, Pfeifer S, Stojadinovic A, Schaden W, Redl H. Extracorporeal shock wave therapy (ESWT) minimizes ischemic tissue necrosis irrespective of application time and promotes tissue revascularization by stimulating angiogenesis. *Ann Surg* 2011;253(5):1024-32.

## **Clinical:**

AWMF-S1-Guideline for thermal-chemical injuries

Arno A, Garcia O, Hernan I, Sancho J, Acosta A, Barret JP. Extracorporeal shock wave, a new non-surgical method to treat severe burns. *Burns* 2010;37(6):844-9.

Cho YS, Joo SY, Cui H et al. Effect of ESWT on scar pain in burn patients: a prospective, randomized, single-blind, placebo-controlled study. *Medicine (Baltimore)* 2016;95(32).e4575.

Fioramonti P et al., ESWT for the management of burn scars. *Dermatol Surg* 2012;38:778-82.

Joo SY, Cho YS, Seo CH. The clinical utility of ESWT for burn pruritus: a prospective, randomized, single-blind study. *Burns* 2017 Oct 10.

Ottomann C, Hartmann B, Tyler J, Maier H, Thiele R, Schaden W, Stojadinovic A. Prospective randomized trial of accelerated re-epithelization of skin graft: donor sites using extracorporeal shock wave therapy. *J Am Coll Surg* 2010;211(3):361-7.

Ottomann C, Stojadinovic A, Lavin PT, Gannon FH, Heggeness MH, Thiele R, Schaden W, Hartmann B. Prospective randomized phase II trial of accelerated reepithelization of superficial second-degree burn wounds using extracorporeal shock wave therapy. *Ann Surg* 2012;255(1):23-9.

Saggini R, Saggini A, Spagnoli AM et al. ESWT: an emerging treatment modality for retracting scars of the hands. *Ultrasound Med Biol* 2016;42(1):185-95.

Wang CJ, Ko JY, Chou WY, Cheng JK, Kuo YR. Extracorporeal shockwave therapy for treatment of keloid scars. *Wound Repair Regen* 2018;Jan 13.



## **ESWT for cellulite**

Prof. Dr. Karsten Knobloch

### **Synonyms**

Orange peel, peau d'orange.

### **Aetiology**

Female sex with differentiated subcutaneous fat formation with fibrosated connective tissue.

Potential concomitant lymphoedema.

### **Symptoms**

Denting of the skin mainly gluteal and dorsal in the upper third of the back thigh. Not infrequently, the dent formation is combined with lymphoedema. The quality of life can be influenced in the long term independently of the clinical objectifiable findings. This psychological dimension can be assessed with validated questionnaires, e. g. according to Doris Hexsel.

### **Examination**

- Digital standardized photographs in dorsal and 90° side view with relaxed gluteal muscles are recommended
- The dents can also be marked standing with an eyeliner pencil
- Girth measurements in lateral comparison at defined localisations
- Body weight
- Quality of life with QoL score after Hexsel, translated by Knobloch

### **Imaging**

- Digital standardized photographs in dorsal and 90° lateral view with relaxed gluteal muscles are recommended
- The dents can also be marked standing with an eyeliner pencil
- Girth measurements
- If necessary, 3D photography with e. g. Vectra system (Canfield)

### **Therapy**

Strengthening the gluteal muscle

Fat-burning endurance sport (mountain hiking, stepper)

Weight reduction

Possible textile compression therapy

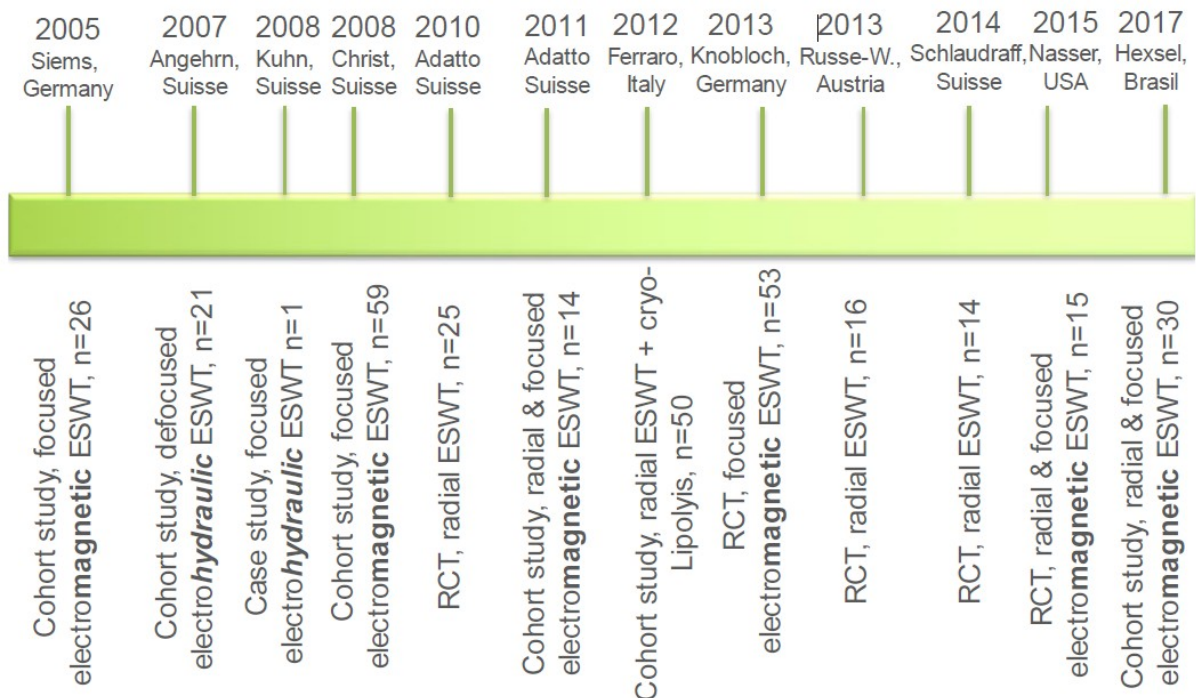
Low level laser therapy

ESWT

Aesthetic surgery e. g. ultrasound-supported liposuction or surgical subcision techniques.

## Shock wave therapy for cellulite

# Timeline of ESWT in cellulite



### **Indication:**

Indication by the expert physician.

**Contraindication:** Malignant tumor in focus, pregnancy.

**Room requirements:** Certification criteria of a medical practice e. g. hygiene plan, emergency management available according to DIN standard.

**Patient preparation:** Differentiated and documented education and information.

**Doctor and assistant staff:** ESWT is a service to be provided personally by a doctor qualified by means of specialist knowledge.

## Implementation of the therapy:

Marking while standing, positioning for ESWT in prone position.

### - Radial ESWT:

1.5 - 4 bar, 3000 pulses, 6 - 8 sessions

### - Focused ESWT:

0.08 - 0.35 mJ / mm<sup>2</sup>, 2000 pulses, 6 - 8 sessions

As of January 2018, twelve clinical studies on the use of ESWT have been published since the first published report by Siems in 2005. A total of 327 patients were included, 123 in randomised trials alone.

- Both radial and focused ESWT is effective in the treatment of cellulite in the present clinical trials with a follow-up period of 3 to 12 months.
  - Radial ESWT:
    - 5 published studies with 3 RCTs & 2 cohort studies
  - Focused ESWT:
    - 5 published studies with 1 RCT & 4 cohort studies
  - Combination radial and focused ESWT:
    - 3 published studies with 1 RCT & 2 cohort studies
- Generator type of the focused ESWT:
  - Focused electromagnetic ESWT
    - In 5 studies (2 RCT, 3 cohort studies)
  - Focused electrohydraulic ESWT
    - In 2 studies (1 cohort study, 1 case report)
  - No piezoelectric ESWT clinical studies on cellulite so far
- Typically, one to two sessions per week and between six to eight sessions ESWT in cellulite were performed in clinical trials.

## **Literature:**

Christ C, Brenke G, Sattler G, et al. Steigerung der Hautelastizität und Revitalisierung der Dermis bei Cellulite und Bindegewebschwäche durch die extrakorporeale Acoustic Wave Therapy (AWT). *Ästhetische Dermatologie* 2008;1:2-10.

Sattler G, Pohl U, Raegener K. Pilotstudie akustische Wellentherapie (AWT) bei Cellulite. *Ästhetische Dermatologie* 2008;2:16-25.

Downs SH, Black N. The feasibility of creating a checklist for the assessment of the methodological quality both of randomised and non-randomised studies of health care interventions. *J Epidemiol Community Health*. 1998;52(6):377-84.

Adatto M, Adatto-Neilson R, Servant JJ, Vester J, Novak P, Krotz A. Controlled, randomized study evaluating the effects of treating cellulite with AWT®/EPAT®. *J Cosmet Laser Ther* 2010;12:176-182.

Knobloch K, Joest B, Krämer R, Vogt PM. Cellulite and focused extracorporeal shockwave therapy for non-invasive body contouring: a randomized trial. *Dermatol Ther (Heidelb)* 2013;3(2):143-55.

Russe-Wilflingseder K, Russe E, Vester JC, Haller G, Novak P, Krotz A. Placebo controlled, prospectively randomized, double-blinded study for the investigation of the effectiveness and safety of the acoustic wave therapy (AWT) for cellulite treatment. *J Cosmet Laser Ther* 2013;15(3):155-62.

Schlaudraff KU, Kiessling MC, Csaszar NB, Schmitz C. Predictability of the individual clinical outcome of extracorporeal shock wave therapy for cellulite. *Clin Cosmet Investig Dermatol* 2014;7:171-83.

Nasser AH, Dorizas AS, Shafai A, Sadick NS. A randomized, controlled clinical study to investigate the safety and efficacy of acoustic wave therapy in body contouring. *Dermatol Surg* 2015;41(3):366-70.

Siems W, Grune T, Voss P, Brenke R. Anti-fibrosclerotic effects of shock wave therapy in lipedema and cellulite. *Biofactors* 2005;24(1-4):275-82.

Angehrn F, Kuhn C, Voss A. Can cellulite be treated with low-energy extracorporeal shock wave therapy? *Clin Interv Aging* 2007;2(4):623-30.

Christ C, Brenke R, Sattler G, Siems W, Novak P, Daser A. Improvement in skin elasticity in the treatment of cellulite and connective tissue weakness by means of extracorporeal pulse activation therapy. *Asthet Surg J* 2008;28(5):538-44.

Adatto MA, Adatto-Neilson R, Novak P, Krotz A, Haller G. Body shaping with acoustic wave therapy AWT/EPAT: randomized, controlled study on 14 subjects. *J Cosmet Laser Ther* 2011;13(6):291-6.

Ferraro GA, De Franceso F, Cataldo C, Rossano F, Nicoletti G, D'Andrea F. Synergistic effects of cryolipolysis and shock waves for noninvasive contouring. *Aesthet Plast Surg* 2012;36(3):666-79.

Hexsel D, Camozzato FO, Silva AF, Siega C. Acoustic wave therapy for cellulite, body shaping and fat reduction. *J Cosmet Laser Ther* 2017;19(3):165-73.

Kuhn C, Angehrn F, Sonnabend O, Voss A. Impact of extracorporeal shock waves on the human skin with cellulite: a case study of an unique instance. *Clin Interv Aging* 2008;3(1):201-10.

## **Myofascial syndrome and myofascial trigger points, diseases of muscle and fascia tissue and dysfunctions of the musculoskeletal system**

Dr. Hannes Müller-Ehrenberg

### **Introduction:**

Muscles and fasciae are well innervated and often cause acute and chronic pain. Accordingly, myofascial tissue should also be specifically examined for complaints of the musculoskeletal system and included in the classification (according to ICD-10). A myofascial trigger point (MTrP) is a circumscribed structure in muscle or connective tissue that triggers pain and is involved in musculo-skeletal pain.

Thanks to their exact application, focused shock waves are also used in deeper tissue layers, both in diagnostics and in the therapy of myofascial complaints and trigger points.

Muscles and fasciae form an anatomical and functional unit which is also treated together.

ESWT is also indicated for connective tissue diseases.

### **Classification**

ICD 10: M79.1 for myofascial pain syndrome and local pain e. g. lumboschialgia M54.4.

### **Synonyms**

Myofascial pain syndrome, myogelosis, muscle tension, muscular trigger points, myofascial trigger points, fascial shortening, fascia dysfunction.

### **Aetiology**

Acute and chronic injury of skeletal muscles.

Acute and chronic overload, overstretching, direct trauma, unphysiological strain on the musculoskeletal system.

In combination with enthesiopathy, incorrect loading (e. g. false statics, muscular dysbalances) radiculopathies, arthrogenic dysfunctions and irritations, diseases of internal organs, endocrine diseases, psychosomatically reactive changes.

### **Symptoms**

Local pain with localization on the musculoskeletal system, increased pressure pain (local), transmission pain (frequent pseudoradicular spread), dysesthesia, tension and stretching pain, joint pain, tendon pain, regional pain (e. g. headache), muscle shortening, muscle hardening, loss of strength, coordination disorder, vegetative symptoms.

## **Diagnostics**

Basic diagnostics: Clinical neurological-orthopaedic examination

Clinical examination (mobility, senso-motoric, specific stretching test). Palpation is the gold standard of clinical examination of muscles and fascia including trigger point diagnostics.

Diagnostic ESWT: With feedback (= feedback) and according to diagnostic criteria (e.g. "recognition", "transmission pain").

## **Apparative diagnostics**

If necessary, orienting ultrasound examination at the place of treatment for local diagnostics.

Elastographic ultrasound diagnostics possible (in clinical use so far without relevance), high-resolution MRT (in scientific studies, in clinical use so far without relevance).

## **Differential diagnosis**

Differential diagnosis of myalgia and joint pain.

Muscle and soft tissue tumors, primary and secondary myopathies, neurological systemic diseases, neurogenic deficits, rheumatic diseases, hormonal disorders (e. g. hyperparathyroidism, hypothyroidism), side effects of drugs (e. g. lipid-lowering drugs).

## **Conservative therapies**

Dry Needling, ischemic compression, acupuncture, stretching, electrotherapy, fascial dissolution techniques, fascial therapies, infiltrations, muscle relaxation techniques, physiotherapy according to IMTT standard, thermotherapy ("stretch and spray").

## **Shock wave therapy**

**Indication:** Indication by the expert physician.

**Before therapy:**

**Room requirements:** Certification criteria of a medical practice e. g. hygiene plan, emergency management available according to DIN.

**Preparation of the patient:** Positioning in a painless position, structures to be treated easily accessible.

Information: Therapy pain also after treatment (approx. 20 - 30 %, usually similar to "sore muscles"), NSAID medication if necessary, vegetative reaction possible (e. g. sweating, circulatory reaction).

**Physician and assistant staff:** ESWT is a service to be provided personally by a physician qualified by means of specialist knowledge.

**Contraindication:** Focus on malignant tumor.

### **Implementation of the therapy:**

Principle: Precise trigger point treatment without movement of the therapy source, with triggering of a "therapy pain" (diagnostic criteria) with pain-adapted intensity (energy).

#### **- Focused ESWT:**

Localisation: After previous palpation, application patient-oriented (feedback)

EFD: 0.05 - 0.35 mJ / mm<sup>2</sup>

Interval: 1-2 x week

Frequency: 4-5 Hz

2000 - 4000 pulses per session, 300 - 400 pulses per MTrP

3 - 8 treatments

Coupling medium: Ultrasound gel

No local anesthesia

#### **- Radial ESWT:**

Localisation: After previous palpation, application patient-oriented (feedback)

Energy up to 2.5 bar

Interval: 1-2 x week

Frequency: Up to 10 Hz

2000 - 4000 pulses per session

3 - 8 treatments

Coupling medium: Ultrasound gel

No local anesthesia



**Documentation:** See preamble.

Designation of the exact ESW application with anatomical localisation (e. g. treated muscle).

Identification of the diagnostic criteria triggered by shock wave therapy: local pain, "recognition", "transmission pain" (feedback) and, if necessary, a muscular twitching reaction.

Naming of the shock wave source, number of SW pulses and intensity (EFD).

**After therapy:** Monitoring of circulatory function if necessary (rarely necessary).

**Complications:** Very rare hematoma (in case of radial SW).

**Side effects:** Transient increase in pain.

**Aftercare:**

Individual stress adjustment, continuation of conservative therapies, independent stretching exercises and fascial treatment, myofascial physiotherapy (if necessary).

### **Literature:**

Amelio E, Manganotti P: Effect of shock wave stimulation on hypertonic plantar flexor muscles in patients with cerebral palsy: a placebo-controlled study. *J Rehabil Med*, 2010

Hausdorf J, Lemmens MA, Heck KD, et al. Selective loss of unmyelinated nerve fibers after extracorporeal shock wave application to the musculoskeletal system. *Neuroscience*. 2008 Jul 31; 155(1):138-144.

Hong JO<sup>1</sup>, Park JS<sup>1</sup>, Jeon DG<sup>1</sup>, Yoon WH<sup>1</sup>, Park JH<sup>1</sup>. Extracorporeal Shock Wave Therapy Versus Trigger Point Injection in the Treatment of Myofascial Pain Syndrome in the Quadratus Lumborum. *Ann Rehabil Med*. 2017 Aug;41(4):582-588. doi: 10.5535/arm.2017.41.4.582. Epub 2017 Aug 31.

Jeon JH<sup>1</sup>, Jung YJ, Lee JY, Choi JS, Mun JH, Park WY, Seo CH, Jang KU. The effect of extracorporeal shock wave therapy on myofascial pain syndrome. *Ann Rehabil Med*. 2012 Oct;36(5):665-74. doi: 10.5535/arm.2012.36.5.665. Epub 2012 Oct 31.

Ji HM, Kim HJ, Han SJ. Extracorporeal shock wave therapy in myofascial pain syndrome of upper trapezius. *Ann Rehabil Med*. 2012;36:675–80.

- M. Gleitz, K. Hornig, Triggerpunkte – Diagnose und Behandlungskonzepte unter besonderer Berücksichtigung extrakorporaler Stoßwellen Orthopade 41 (2012)
- Kraus M, Reinhart E, Krause H, Reuther J. [Low energy extracorporeal shock wave therapy (ESWT) for treatment of myogelosis of the masseter muscle]. Mund Kiefer Gesichtschir. 1999; 3(1):20-3.
- Lee JY, Kim SN, Lee IS, Jung H, Lee KS, Koh SE Effects of Extracorporeal Shock Wave Therapy on Spasticity in Patients after Brain Injury: A Meta-analysis J PhysTherSci. 2014 Oct;26(10):1641-7
- Lohse-Busch H, Kraemer M, Reime U. [A pilot investigation into the effects of extracorporeal shock waves on muscular dysfunction in children with spastic movement disorders]. Schmerz. 1997 Apr 18;11(2):108-12
- Maier M, Averbeck B, Milz S, Refior HJ, Schmitz C. Substance P and prostaglandin E2 release after shock wave application to the rabbit femur. ClinOrthopRelat Res. 2003 Jan 2003(406):237-245.
- Manganotti P, Amelio E: Long-term effect of shock wave therapy on upper limb hypertonia in patients affected by stroke. Stroke, 2005
- Mariotto S, Cavalieri E, Amelio E, et al.: Extracorporeal shock waves: from lithotripsy to anti-inflammatory action by NO production. Nitric Oxide, 2005
- Mense S, Simons DG. Muscle pain : Understanding ist nature, diagnosis, and treatment. Philadelphia: Lippincott Williams & Wilkins; 2001.
- Moghtaderi A., Khosrawi S., Dehghan F. Extracorporeal shock wave therapy of gastroc-soleus trigger points in patients with plantar fasciitis: A randomized, placebo-controlled trial AdvBiomed Res. 2014; 3: 99
- Müller-Ehrenberg H, Licht G. Diagnose und Therapie des Myofaszialen Schmerz Syndroms mit fokussierten Stoßwellen (ESWT), Medizinisch Orthopädische Technik. 2005;5:1–6.
- Müller-Ehrenberg H, Thorwesten L, Pottebaum M, Epping H, Gries L, Völker K: Veränderung statischer und dynamischer Kraftfähigkeiten nach Behandlung myofaszialer Triggerpunkte mittels fokussierter ESWT beim Schulterschmerz im Sport, Sportärztekongress 2012 Frankfurt
- Schenk I, Vesper M, Nam VC. [Initial results using extracorporeal low energy shock wave therapy ESWT in muscle reflexinduced lock jaw]. Mund Kiefer Gesichtschir. 2002 Sep 2002; 6(5):351-355.
- Ramon S, Gleitz M, Hernandez L, Romero LD Update on the efficacy of extracorporeal shockwave treatment for myofascial pain syndrome and fibromyalgia International Journal of Surgery 24 (2015)
- Shah JP, Danoff JV, Desai MJ, et al. Biochemicals associated with pain and inflammation are elevated in sites near to and remote from active myofascial trigger points. ArchPhysMedRehabil. 2008 Jan 2008; 89(1):16-23.
- Travell J, D.G. S. Handbuch der Muskel-Triggerpunkte. Obere Extremitäten, Kopf und Thorax. 1 ed. Stuttgart: Gustav Fischer Verlag; 1998.

Travell J, D.G. S. Handbuch der Muskel-Triggerpunkte. Untere Extremitäten und Becken. 1ed.  
München: Urban & Fischer Verlag; 2000.

Wall PD, Cronly-Dillon JR. Pain, itch, and vibration. ArchNeurol. 1960 Apr 1960;

## **Shock wave therapy for urological diseases (without lithotripsy)**

Dr. Hannes Müller-Ehrenberg

### **Erectile dysfunction**

#### **Introduction**

Erectile dysfunction (ED) refers to the lack of limb stiffness during sexual intercourse to perform a successful coitus.

ED is a worldwide disease affecting approximately 50 % of all men between the ages of 40 and 70 with varying degrees of severity. Organic factors are the main cause (60 - 80 %) of ED, and the main focus here is on circulatory disorders of the erectile tissue at the base of an often generalized vascular disease.

In the interdisciplinary treatment concept of ED, low-dose focused ESWT has played an important role since 2010.

Previous clinical studies have shown that ESWT is also effective for PDE-5 inhibitors - ineffectiveness and intolerance and a good long-term effect.

Since 2015, the European Association of Urology (EAU) has been using ESWT as a method of first choice for the treatment of erectile dysfunction in addition to PDE-5 inhibitors.

#### **Classification**

ICD 10: N48.4 erectile dysfunction of organic origin.

#### **Aetiology**

70 % organic factors especially arterial circulatory disorders, damage to the corpora cavernosa (e. g. "venous leak", veno-occlusive dysfunction) nerve dysfunction (e. g. after prostatectomy surgery) also multifactorial with psychological factors ICD-10 F52.2 (e. g. fear of failure).

#### **Symptoms**

Lack of erectile function or stiffness of the limb for the duration of sexual intercourse.

#### **Diagnostics**

Andrological-urological examinations

Clarification of psychological causes of erectile dysfunction

Standard questionnaire IIEF (before and after therapy)

## **Therapies**

Medicinal e. g. PDE-5 inhibitors.

Mechanical: Vacuum pumps etc., less significant since introduction of PDE-5 inhibitors.

Operative: After exhaustion of all conservative therapies e. g. vascular operations, penis prostheses (penis implants).

## **Shock wave therapy**

### **Indication:**

Vascular erectile dysfunction caused by endothelial dysfunction, cavernosal erectile dysfunction (cavernose insufficiency = "venous leak"), increased blood outflow in the cavernous body caused by a dysfunction or damage to the smooth swelling muscles (insufficient erection), neurogenic dysfunction caused by a defect in the periprostatic nerve tracts.

Indication by a physician.

**Contraindication:** Focus on malignant tumor.

### **Before therapy:**

**Room requirements:** Certification criteria of a medical practice e. g. hygiene plan, emergency management available according to DIN.

**Patient preparation:** Differentiated (medical and economic) and documented education and information.

**Positioning:** Structures to be treated easily accessible if necessary support bracket.

**Physician and assistant staff:** ESWT is a service to be provided personally by a physician qualified by means of specialist knowledge.

### **Implementation of the therapy:**

#### **- Focused**

Principle: While most ESWT indications focus on local focused therapy, the treatment of ED requires the application along the entire erectile tissue.

Application: Extensive treatment of the entire penis shaft and the crura.

Localisation: By anatomy

EFD: 0.05 - 0.30 mJ / mm<sup>2</sup>

Interval: 1 - 2 x / week

Frequency: 2 - 8 Hz

2000 - 4000 pulses per session

4 - 12 treatments

Coupling medium: Ultrasound gel

No local anesthesia

Documentation: See preamble.

After ESW therapy: No further immediate measure, if necessary continuation of medication (e. g. PDE-5 inhibitor).

**Complications:** None known.

**Follow-up treatment:**

Continuation of conservative therapies, control of endothelial dysfunction (e. g. arteriosclerosis) is useful.

**References ED and ESWT**

Abe Y, Ito K, Hao K, Shindo T, Ogata T, et al. (2014) Extracorporeal low-energy shock-wave therapy exerts anti-inflammatory effects in a rat model of acute myocardial infarction. *Circ J* 78(12): 2915-2925.

Abu-Ghanem Y, Kitrey ND, Gruenwald I, Appel B, Vardi Y (2014) Penile low-intensity shock wave therapy: a promising novel modality for erectile dysfunction. *Korean J Urol*.55(5): 295-299.

Bechara A, Casabé A, De Bonis W, Nazar J (2015) Effectiveness of low-intensity extracorporeal shock wave therapy on patients with erectile dysfunction (ED) who have failed to respond to PDE5i therapy. A pilot study. *Arch EspUrol* 68(2): 152-160.

Becker M, Goetzenich A, Roehl AB, Huebel C, de la Fuente M, et al. (2014) Myocardial effects of local shock wave therapy in a Langendorff model. *Ultrasonics* 54(1): 131-136.

Chitale S, Morse M, Swift L, Sethia K (2010) Limited shock wave therapy vs sham treatment in men with Peyronie's disease: results of a prospective randomized controlled double-blind trial. *BJU Int* 106(9): 1352-1356.

Chung E, Cartmill R (2015) Evaluation of clinical efficacy, safety and patient satisfaction rate after low-intensity extracorporeal shockwave therapy for the treatment of male erectile dysfunction: an Australian first open-label single-arm prospective clinical trial. *BJU Int* 115(Suppl 5): 46-49.

Frey A, Sønksen J, Fode M (2016) Low-intensity extracorporeal shockwave therapy in the treatment of post prostatectomy erectile dysfunction: a pilot study. *Scand J Urol* 50(2): 123-127.

Goertz O, Lauer H, Hirsch T, Ring A, Lehnhardt M, et al. (2012) Extracorporeal shock waves improve angiogenesis after full thickness burn. *Burns* 38(7): 1010-1018.

Ilan Gruenwalda, Ofer Shenfeldb, Juza Chenc, Gil Ravivd, Santiago Richtere, et al. (2006) Positive effect of counseling and dose adjustment in patients with erectile dysfunction who failed treatment with sildenafil. *EurUrol* 50(1): 134-140.

Hatzichristou D, d'Anzeo G, Porst H, Buvat J, Hennes C, et al. (2015) Tadalafil 5 mg once daily for the treatment of erectile dysfunction during a 6-month observational study (EDATE): impact of patient characteristics and comorbidities. *BMC Urol* 15: 111.

Hausner T, Nógrádi A. The use of shock waves in peripheral nerve regeneration: new perspectives? *Int Rev Neurobiol.* 2013;109:85–98.

Hayashi D, Kawakami K, Ito K, Ishii K, Tanno H, et al. (2012) Low-energy extracorporeal shock wave therapy enhances skin wound healing in diabetic mice: a critical role of endothelial nitric oxide synthase. *Wound Repair Regen* 20(6): 887-895.

Hazan-Molina H, Reznick AZ, Kaufman H, Aizenbud D (2015) Periodontal cytokines profile under orthodontic force and extracorporeal shock wave stimuli in a rat model. *J Periodontal Res* 50(3): 389-396.

Ioppolo F, Rompe JD, Furia JP, Cacchio A (2014) Clinical application of shock wave therapy (SWT) in musculoskeletal disorders. *Eur J PhysRehabil Med* 50(2): 217-230.

Kim JH, Kim JY, Choi CM, Lee JK, Kee HS, et al. (2015) The dose-related effects of extracorporeal shock wave therapy for knee osteoarthritis. *Ann Rehabil Med* 39(4): 616-623.

Li H, Matheu MP, Sun F, Wang L, Sanford MT, et al. (2016) Low-energy shock wave therapy ameliorates erectile dysfunction in a pelvic neurovascular injuries rat model. *J Sex Med* 13(1): 22-32.

Liu J, Zhou F, Li GY, Wang L, Li HX, et al. (2013) Evaluation of the effect of different doses of low energy shock wave therapy on the erectile function of streptozotocin (STZ)-induced diabetic rats. *Int J MolSci* 14(5): 10661-10673.

Lu Z., et al. Low-intensity Extracorporeal Shock Wave Treatment Improves Erectile Function: A Systematic Review and Meta-analysis. *EurUrol* (2016)

Mense S, Hoheisel U (2013) Shock wave treatment improves nerve regeneration in the rat. *Muscle Nerve* 47(5): 702-710.

Olsen AB, Persiani M, Boie S, Hanna M, Lund L (2015) Can low-intensity extracorporeal shockwave therapy improve erectile dysfunction? A prospective, randomized, double-blind, placebo-controlled study. *Scand J Urol* 49(4): 329-333.

Palmieri A, Imbimbo C, Creta M, Verze P, Fusco F, et al. (2012) Tadalafil once daily and extracorporeal shock wave therapy in the management of patients with Peyronie's disease and erectile dysfunction: results from a prospective randomized trial. *Int J Androl* 35(2): 190-195.

Pelayo-Nieto M, Linden-Castro E, Alias-Melgar A, Espinosa-Pérez Grovas D, Carreño-de la Rosa F, et al. (2015) Linear shock wave therapy in the treatment of erectile dysfunction. *ActasUroEsp* 39(7): 456-459.

Poulakis V, Skriapas K, de Vries R, Dillenburg W, Ferakis N, et al. (2006) Extracorporeal shockwave therapy for Peyronie's disease: an alternative treatment?. *Asian J Androl* 8(3): 361-366.

Qiu X, Lin G, Xin Z, Ferretti L, Zhang H, et al. (2013) Effects of low-energy shockwave therapy on the erectile function and tissue of a diabetic rat model. *J Sex Med* 10(3): 738-746.

Rassweiler JJ, Knoll T, Köhrmann KU, McAteer JA, Lingeman JE, et al. (2011) Shock wave technology and application: an update. *EurUrol* 59(5): 784-796. Rosen RC, Allen KR, Ni X, Araujo AB (2011) Minimal clinically important differences in the erectile function domain of the International Index of Erectile Function scale. *EurUrol* 60(5): 1010-1016.

Skolarikos A, Alargof E, Rigas A, Deliveliotis Ch, Konstantinidis E (2005) Shockwave therapy as first-line treatment for Peyronie's disease: a prospective study. *J Endourol* 19(1): 11-14.

Srini VS, Reddy RK, Shultz T, Denes B (2015) Low intensity extracorporeal shockwave therapy for erectile dysfunction: a study in an Indian population. *Can J Urol* 22(1): 7614-7622.

Tara S, Miyamoto M, Takagi G, Kirinoki-Ichikawa S, Tezuka A, et al. (2014) Low energy extracorporeal shock wave therapy improves microcirculation blood flow of ischemic limbs in patients with peripheral arterial disease: pilot study. *J Nippon Med Sch* 81(1): 19-27.

Vardi Y, Appel B, Kilchevsky A, Gruenwald I (2012) Does low intensity extracorporeal shock wave therapy have a physiological effect on erectile function? Short-term results of a randomized, double-blind, sham controlled study. *J Urol* 187: 1769-1775.

Yee CH, Chan ES, Hou SS, Ng CF (2014) Extracorporeal shockwave therapy in the treatment of erectile dysfunction: a prospective, randomized, double-blinded, placebo controlled study. *Int J Urol* 21(10): 1041-1045.

Zimmermann R, Cumpanas A, Miclea F, Janetschek G (2009) Extracorporeal shock wave therapy for the treatment of chronic pelvic pain syndrome in males: a randomised, double-blind, placebo-controlled study. *EurUrol* 56(3): 418-424.