

# Veterinary Wound Care

Wounds from Canine Attack on Foal  
Treated with TRT/MTS VetGold 140



# MSMW would like to thank the following individuals and organizations:

Without the support of the following individuals the treatment of this foal would not have been possible. The owners of the foal were not in a financial position to absorb the burden of the cost to properly care for her. MSMW donated the treatments, but the greatest cost were related to bandages, and boarding and daily care of her and her mother. Again, thank you for your help and kind donations.

Drs. Kevin Beam & Chris Tarwater – Alvarado Vet Clinic

Melissa Dorman

The Calvert Family – Jim, Stacy, Max, & Lily

Mick & Erin Turley

Bobby & Lisa Hammond

Dr. Wolfgang Schaden

Tissue Regeneration Technologies, LLC

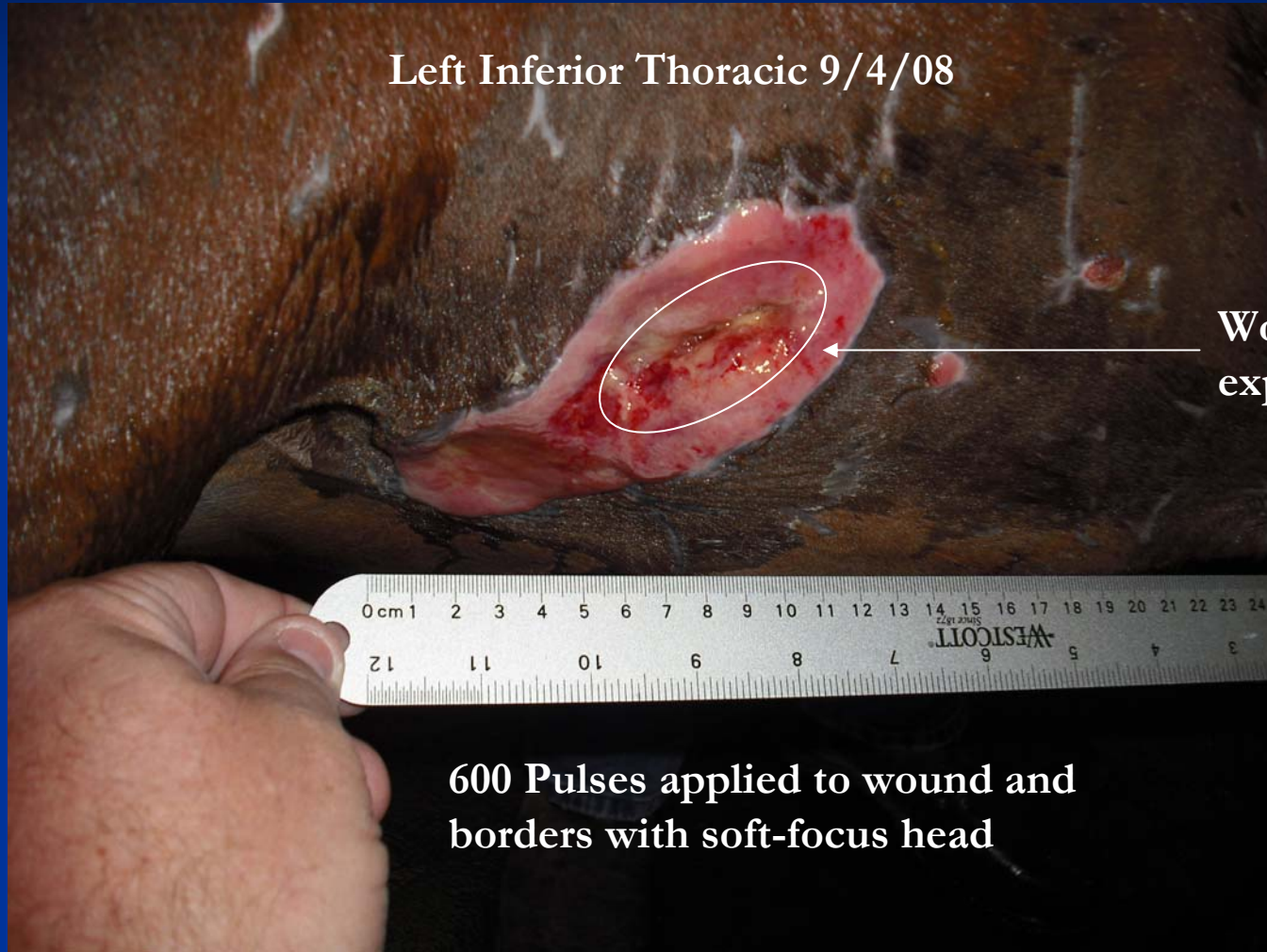# Case History

The following images are of dog bites wounds sustained by a foal approximately one week after birth. She had been in veterinary care, receiving hydrotherapy and daily dressing changes for approximately 13 days prior to Baseline images were taken and the first TRT Multi-wave™ treated applied.

- Estimated date of injury – 8/21/08
- Baseline Images and First Multi-wave™ Treatment – 9/4/08
- Adjunctive therapy – Hydrotherapy

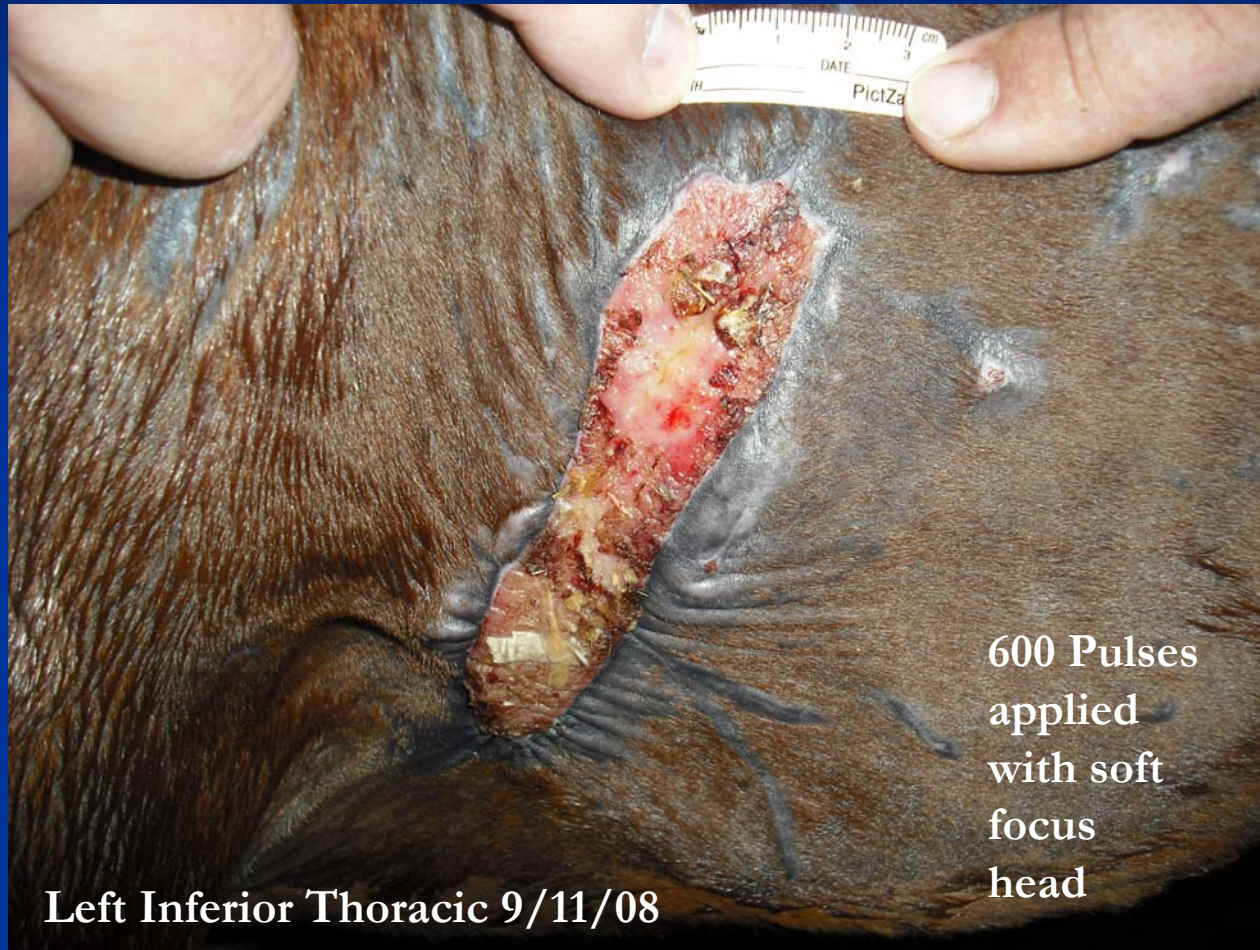Treatments were applied at 7 day intervals, and are ongoing for some of the larger wounds. Images will be updated as follow-up visits are performed

# Baseline

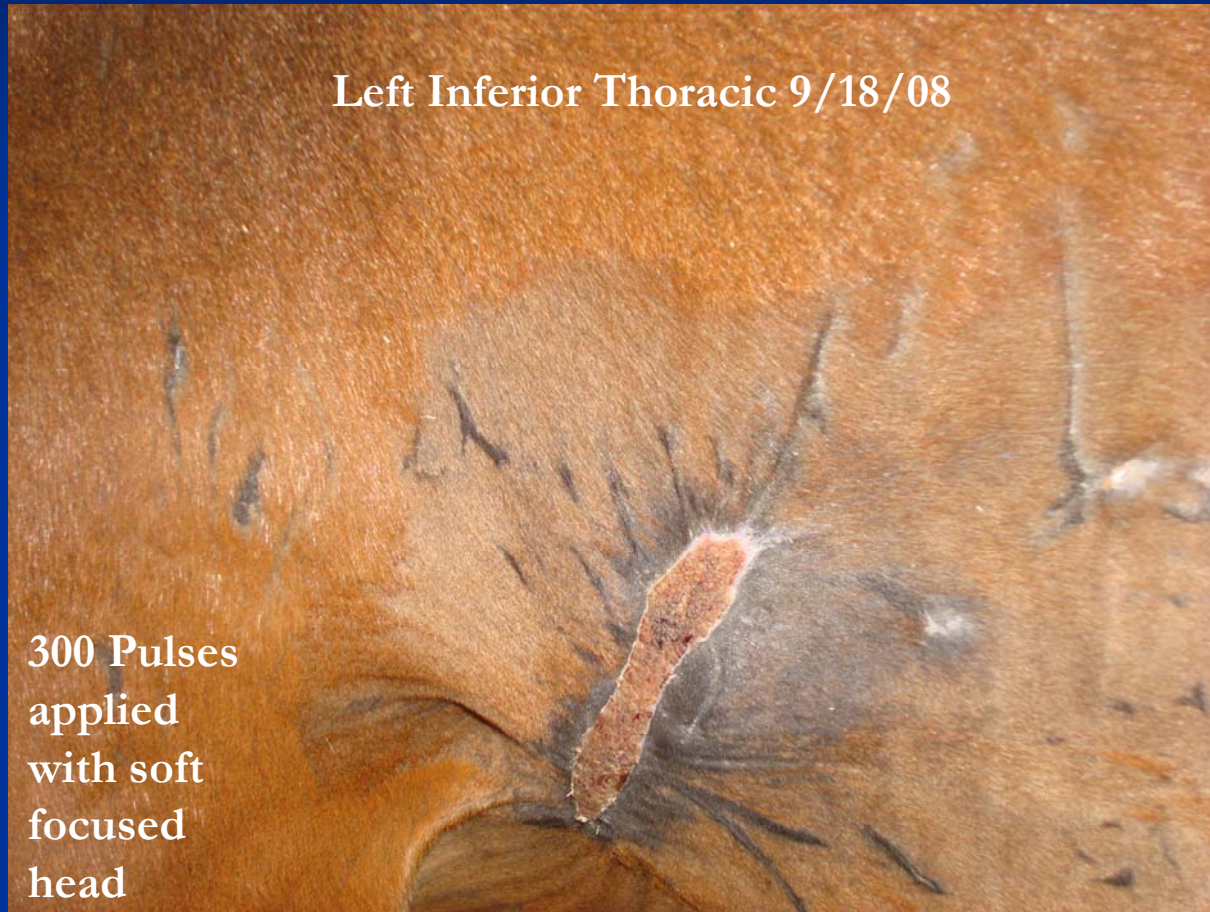



# 7 Days Post 1<sup>st</sup> Treatment

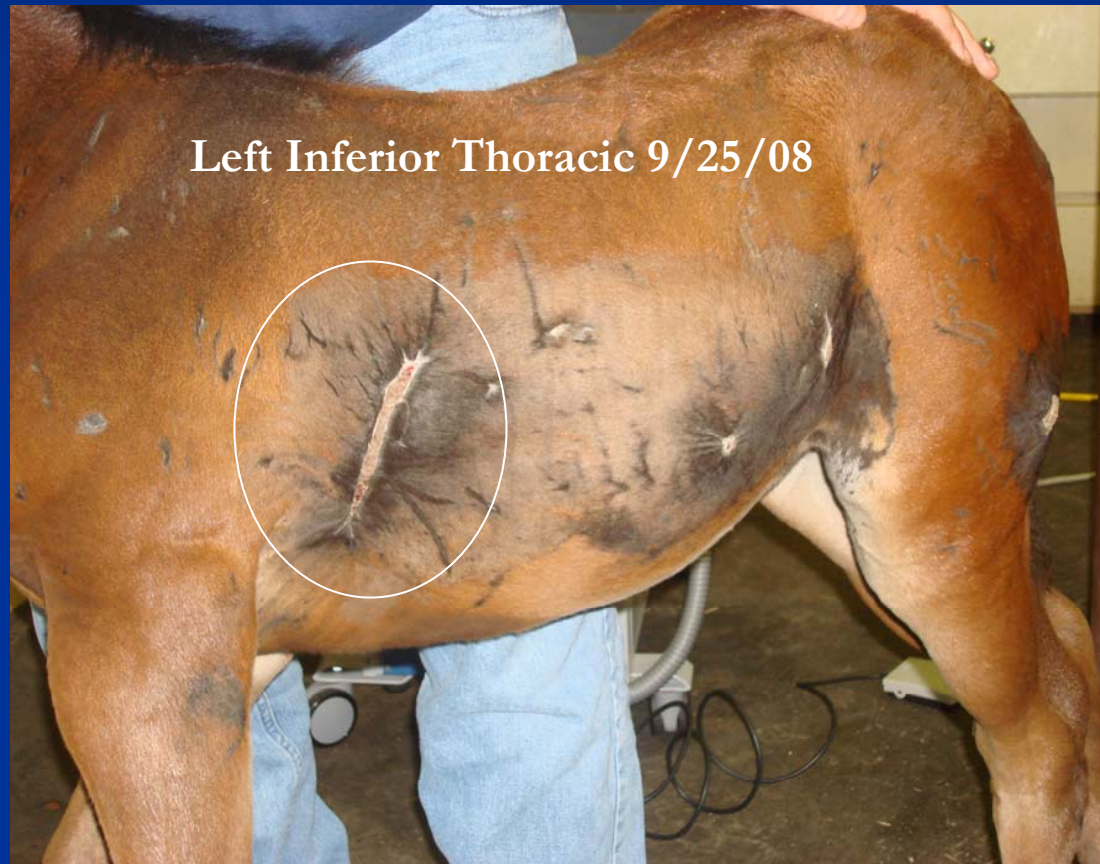

# 14 day follow-up (7 days post 2<sup>nd</sup> Tx)



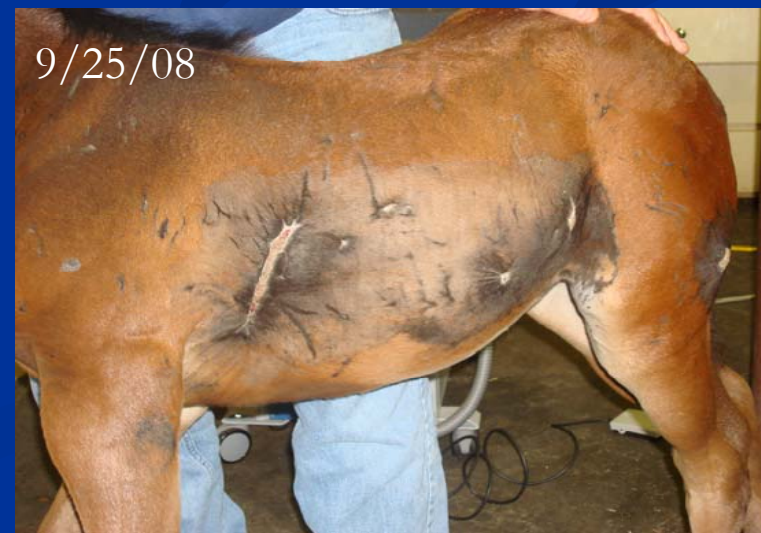
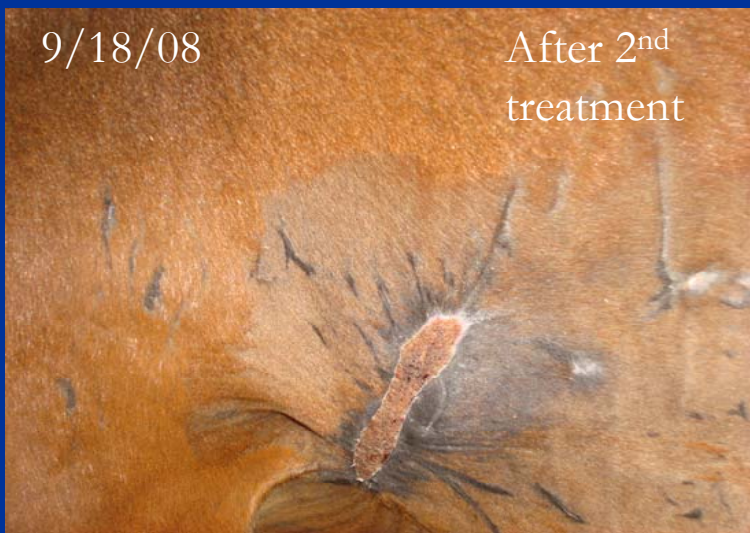
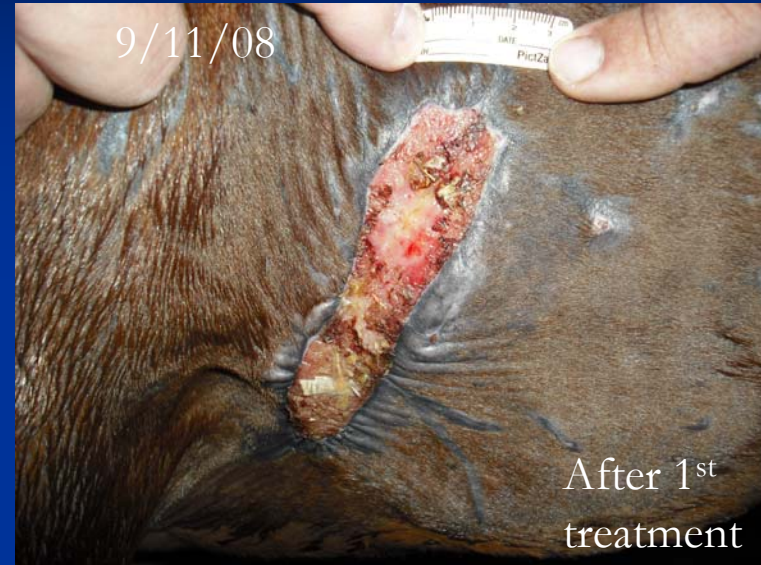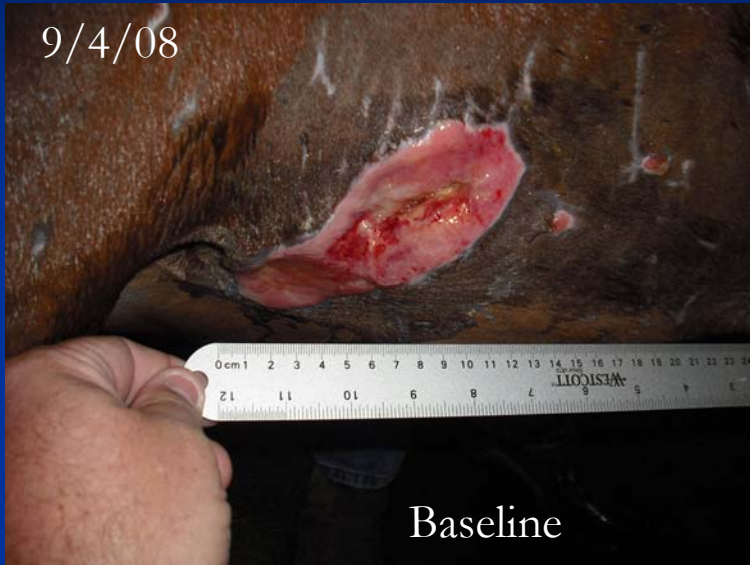# 21 Day Follow-up



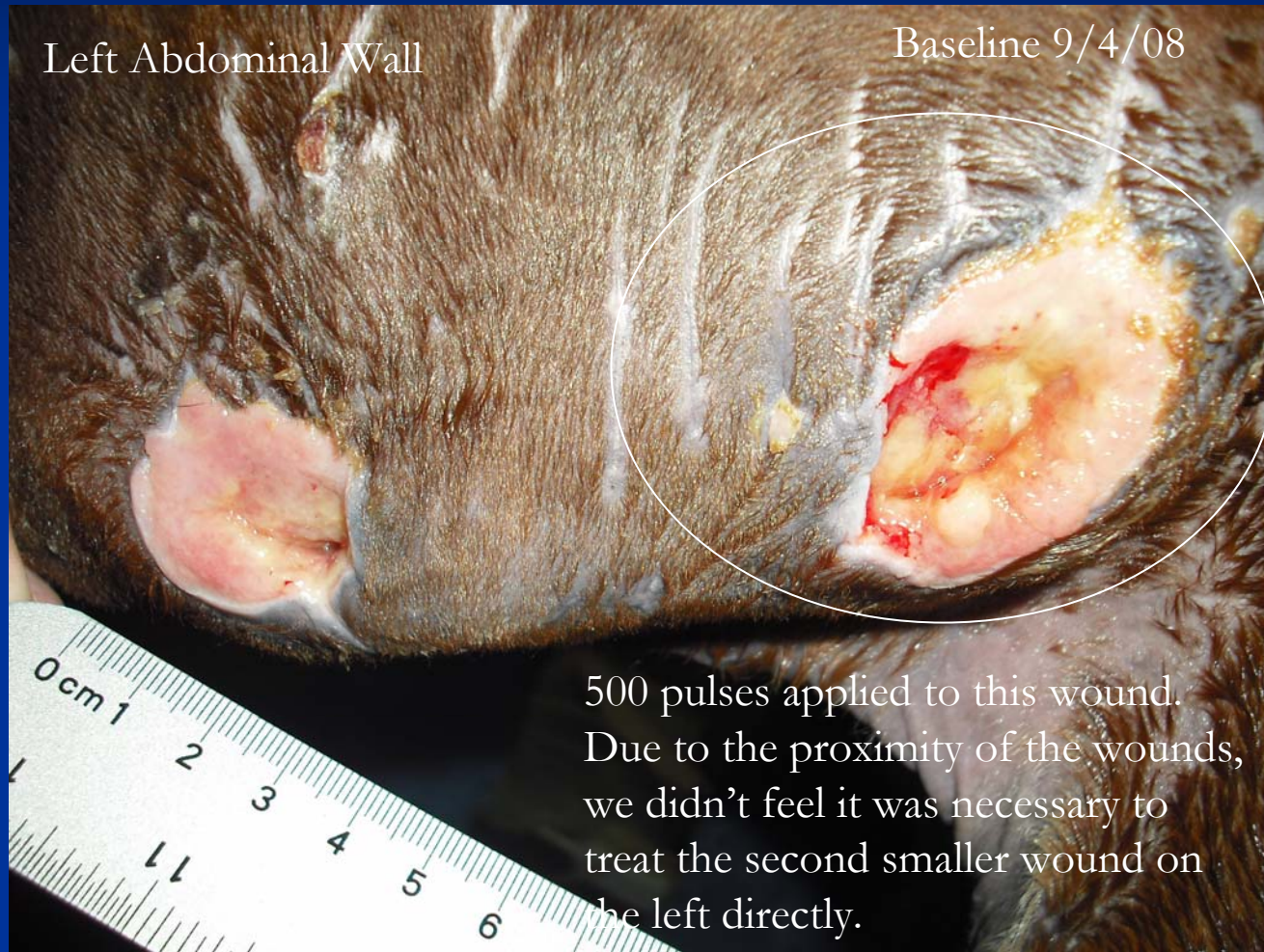Last treatment 9-11-08

# Progress Summary

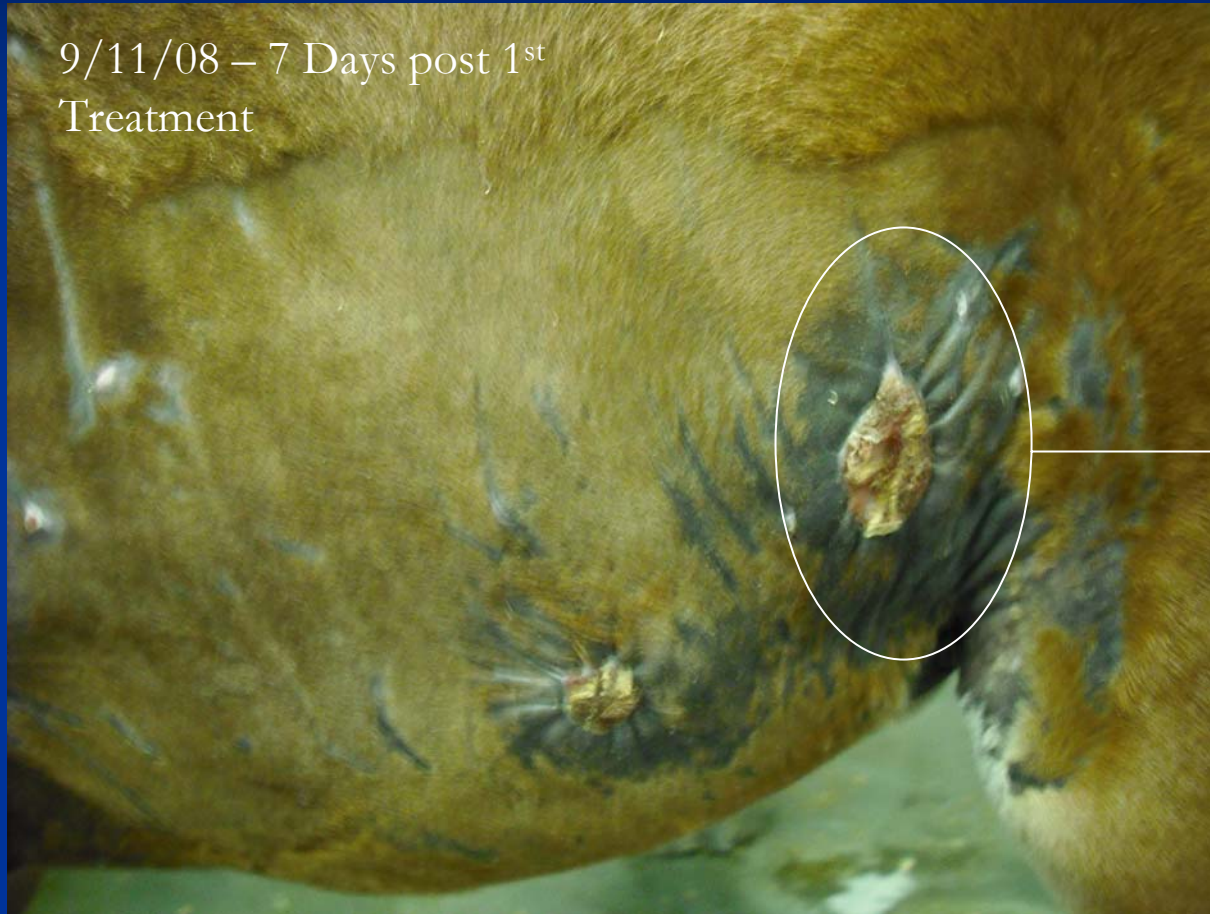



# Left Abdominal Wall Wounds



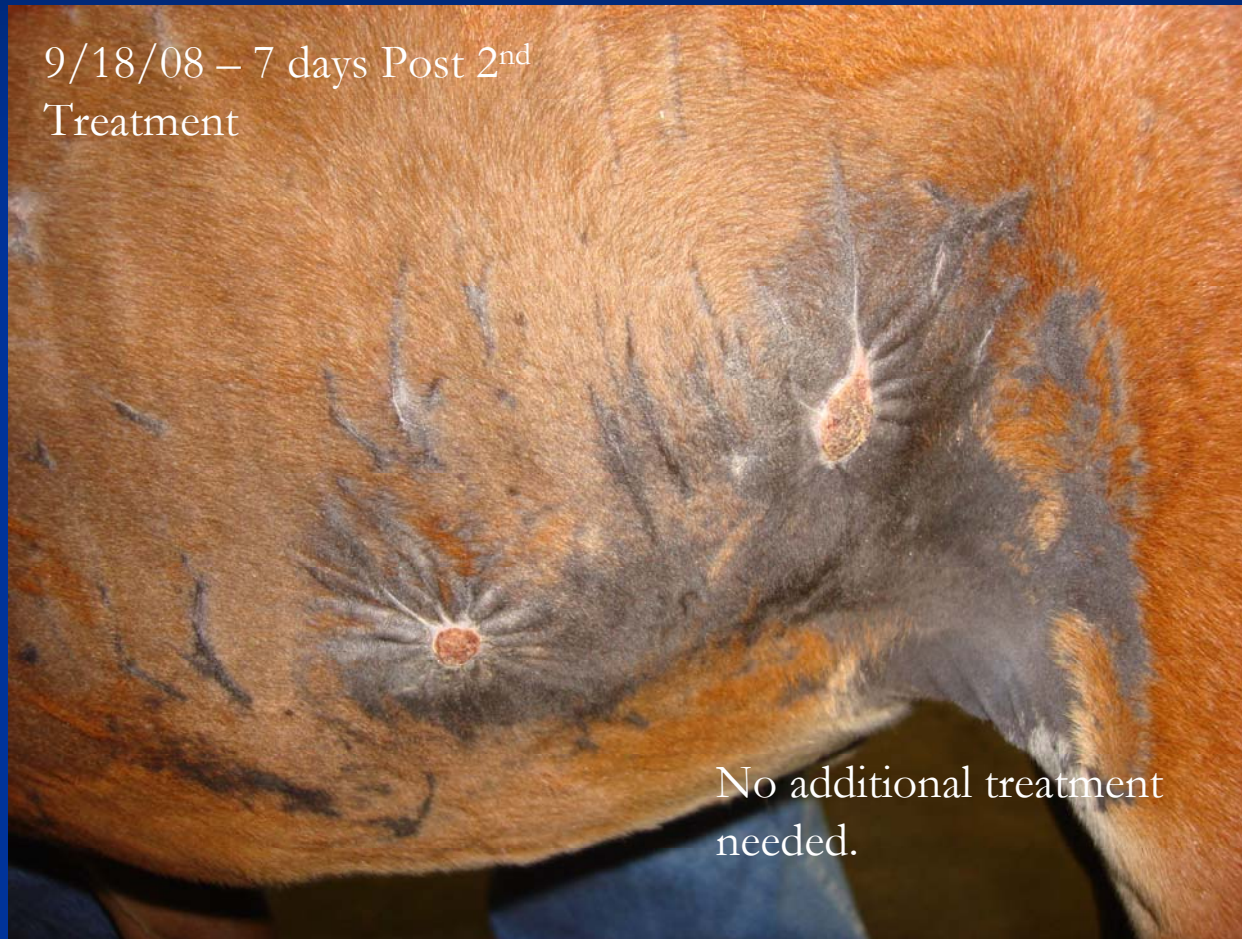# Left Abdominal Wall Wounds



300 Pulses  
applied with  
Soft Focus  
Head

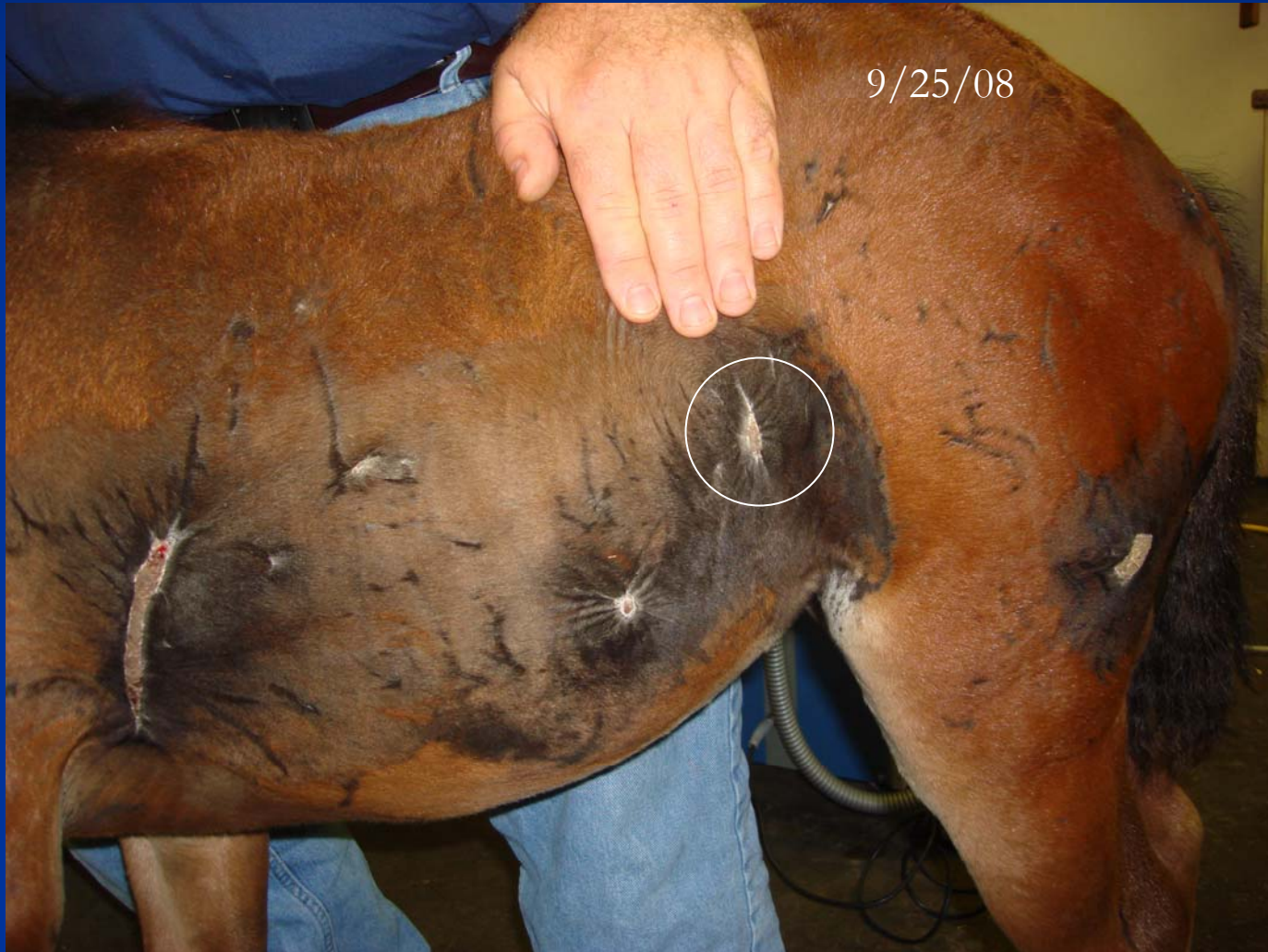

# Left Abdominal Wall Wounds

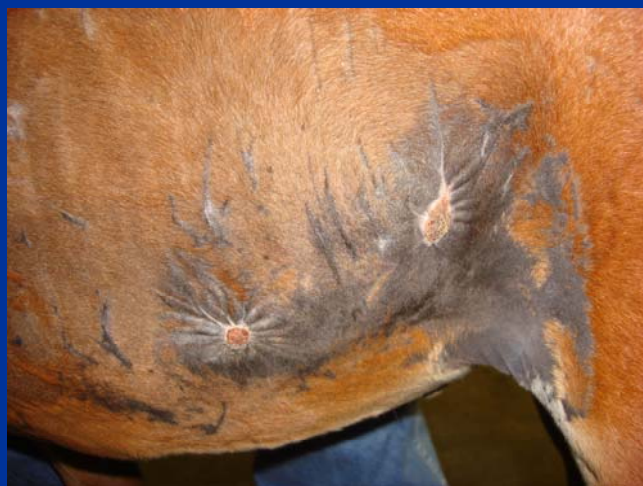
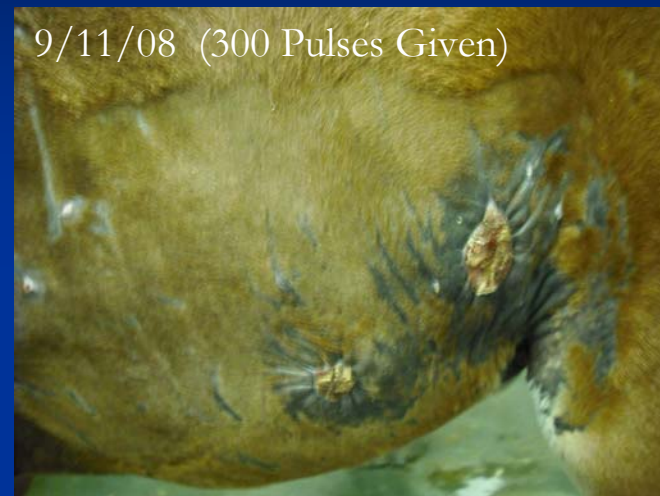
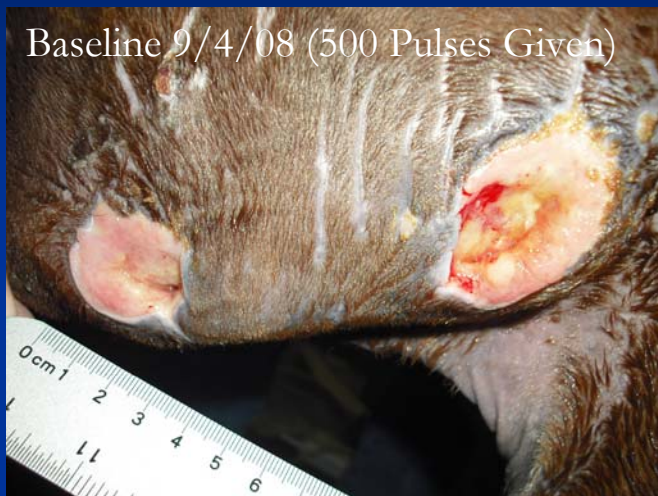

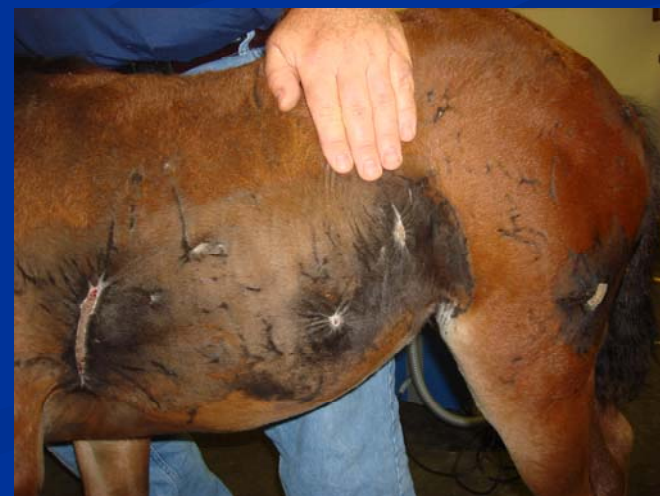# Left Abdominal Wall Wound



# Left Abdominal Wall Wounds - Summary



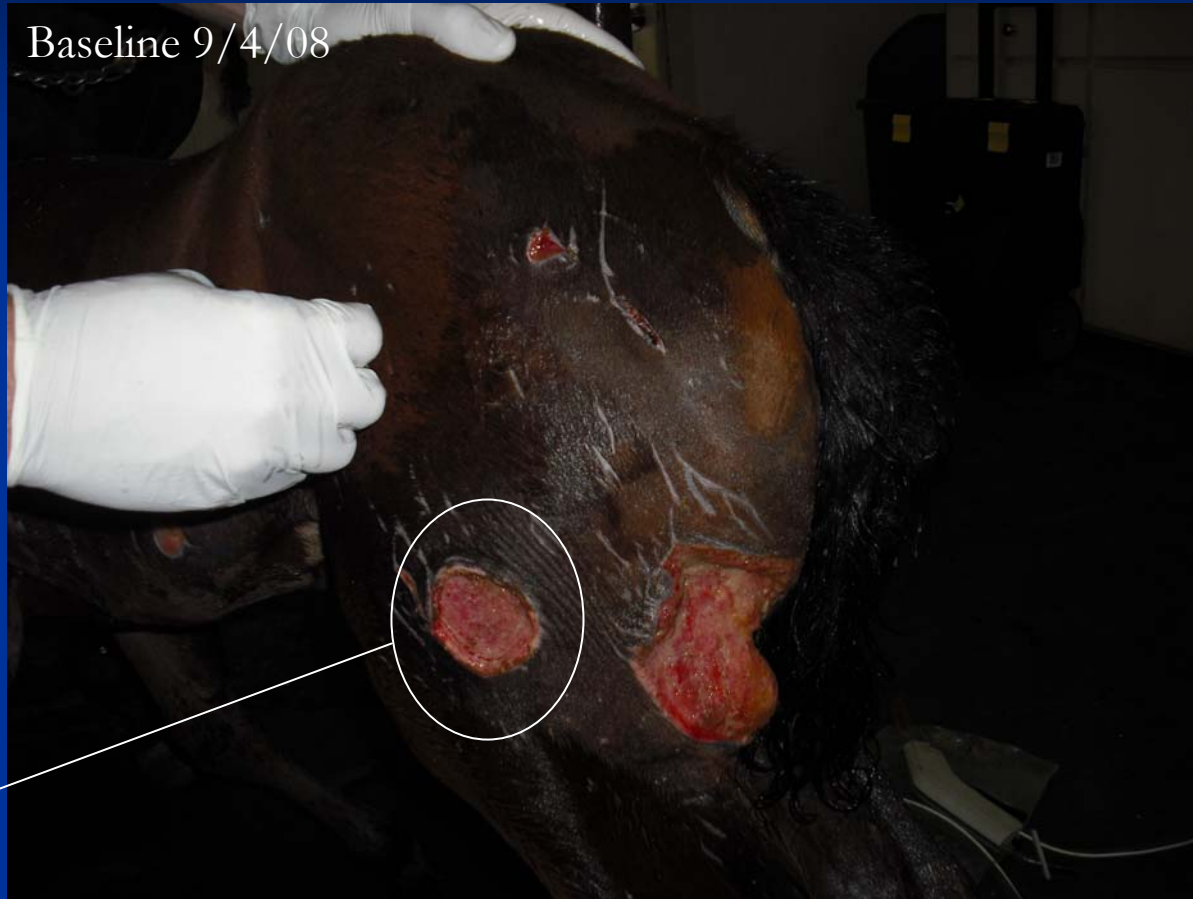9/18/08 No additional treatment needed



9/25/08



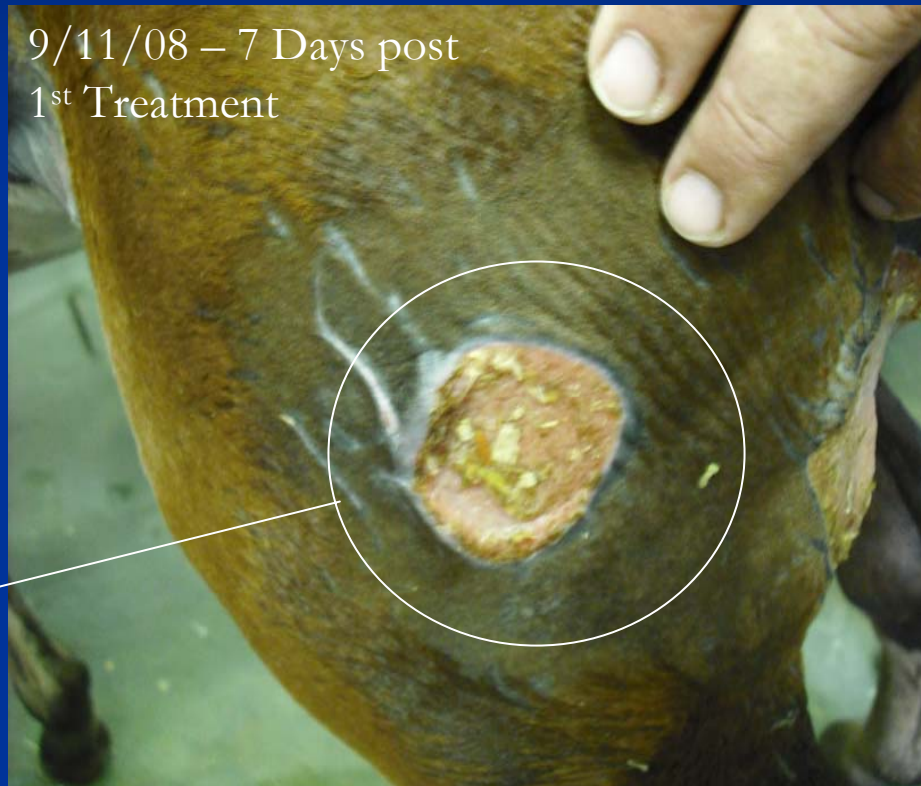# Left Hip



600 Pulses  
applied  
w/ SF  
Head

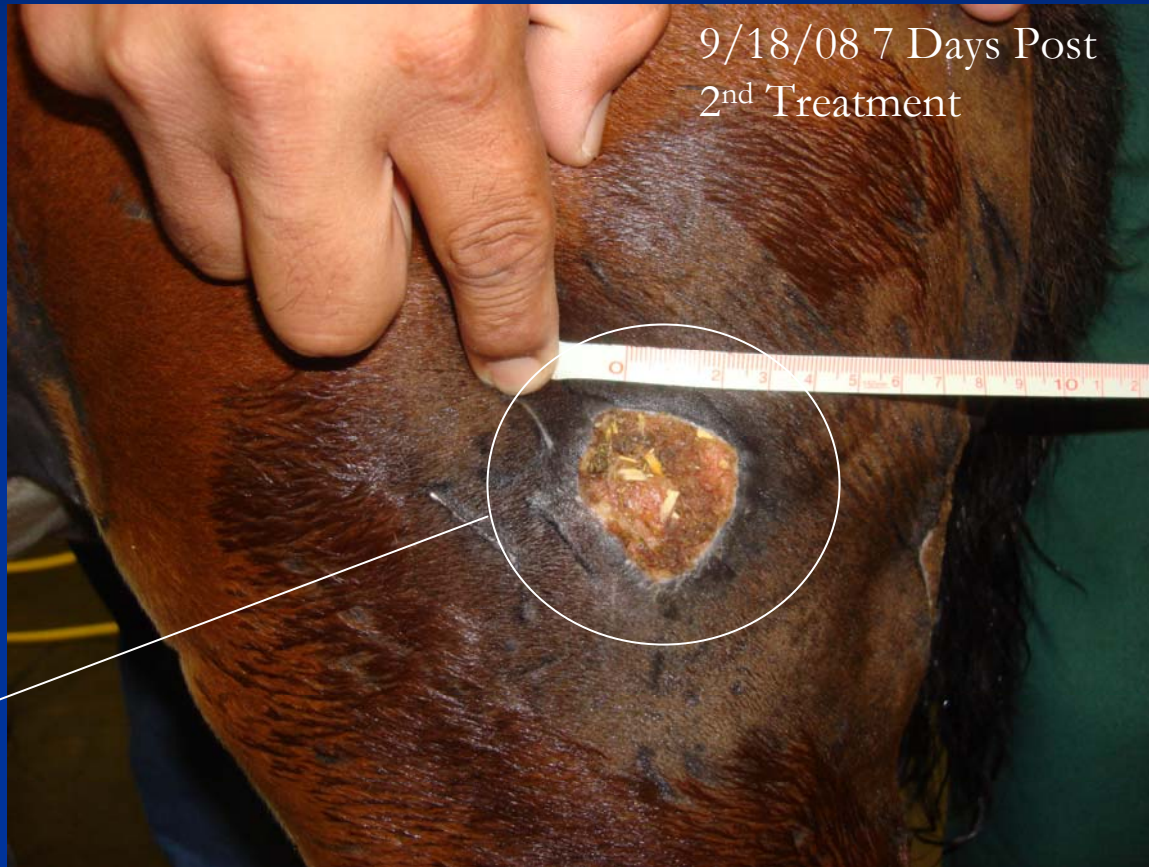

# Left Hip



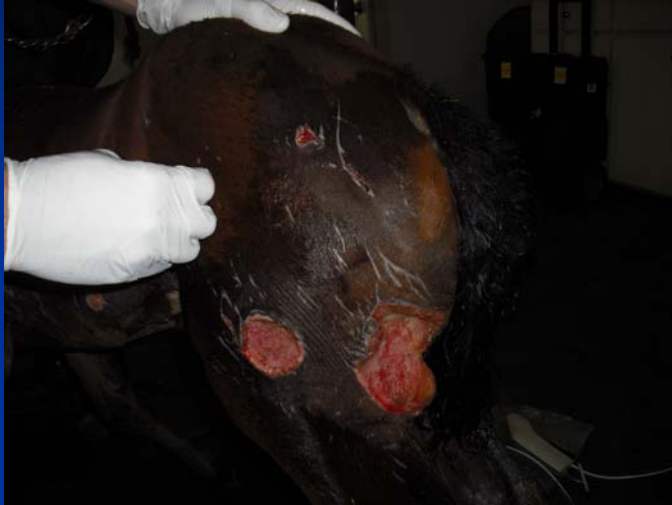600 Pulses  
applied w/  
SF Head

# Left Hip

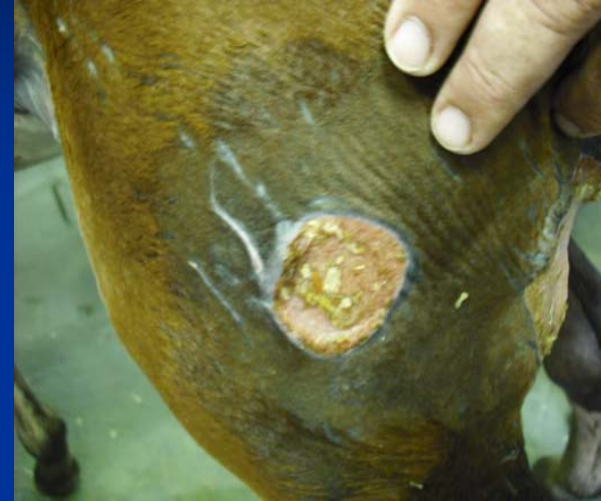

300 Pulses  
Applied  
w/ SF  
Head

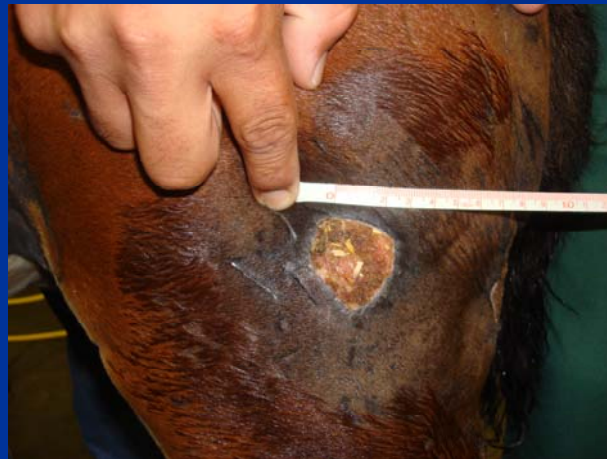# Left Hip – Progress Summary



Baseline 9/4/08 – 600 Pulses



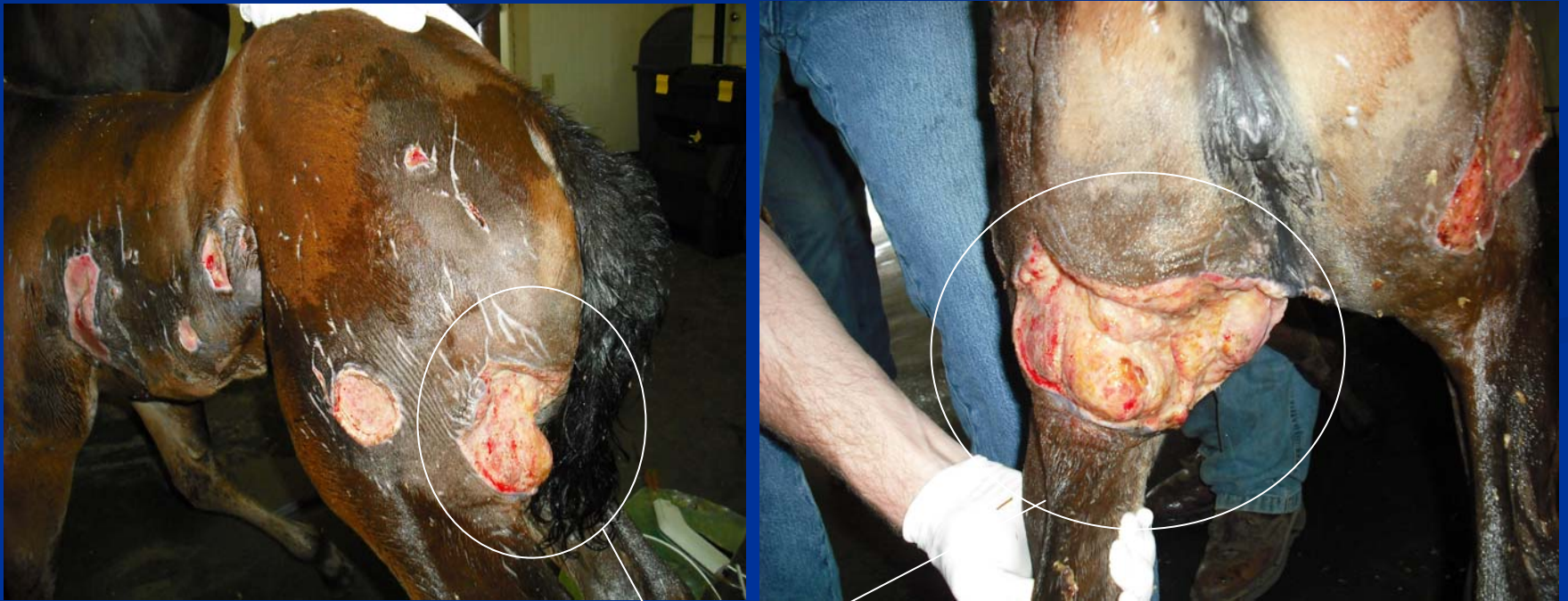9/11/08 – 600 Pulses



9/18/08 – 300 Pulses

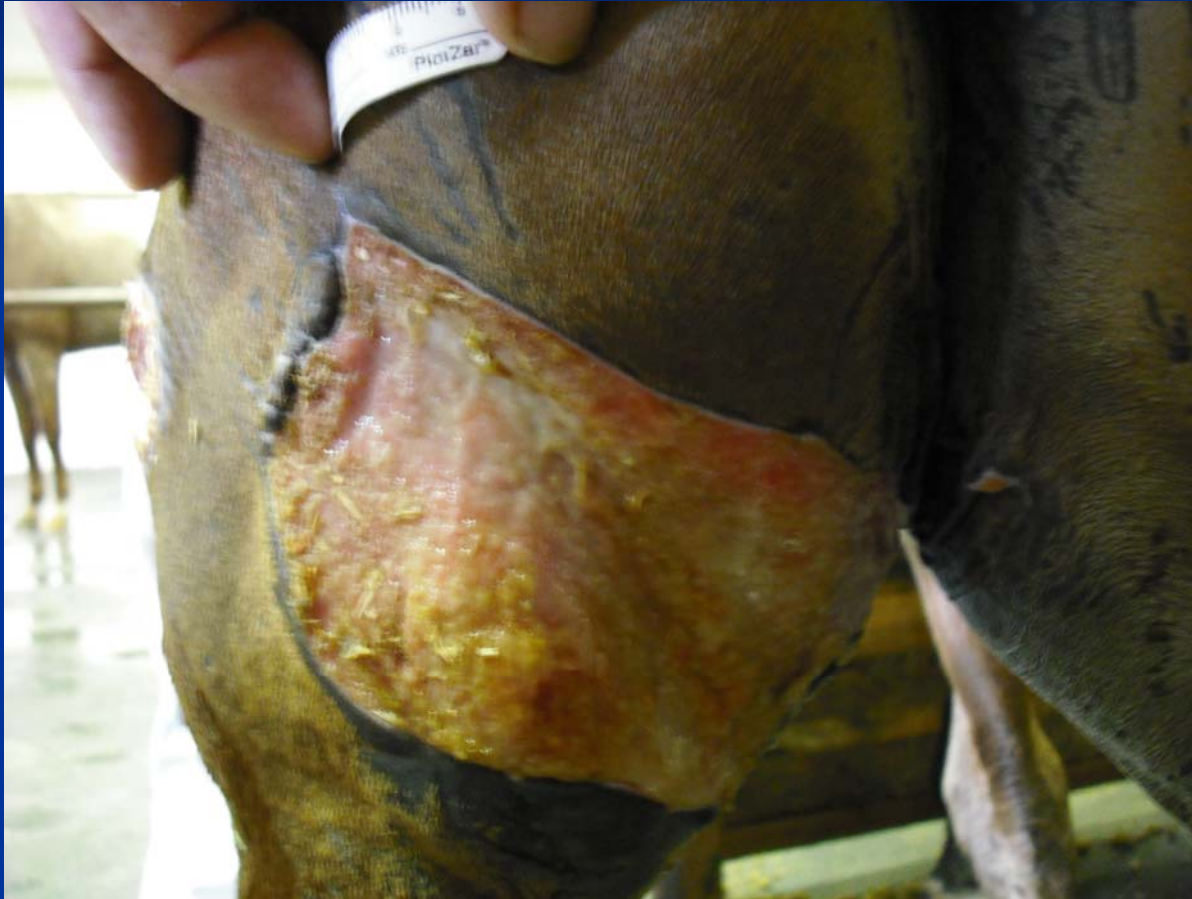

# Left Hind Quarter



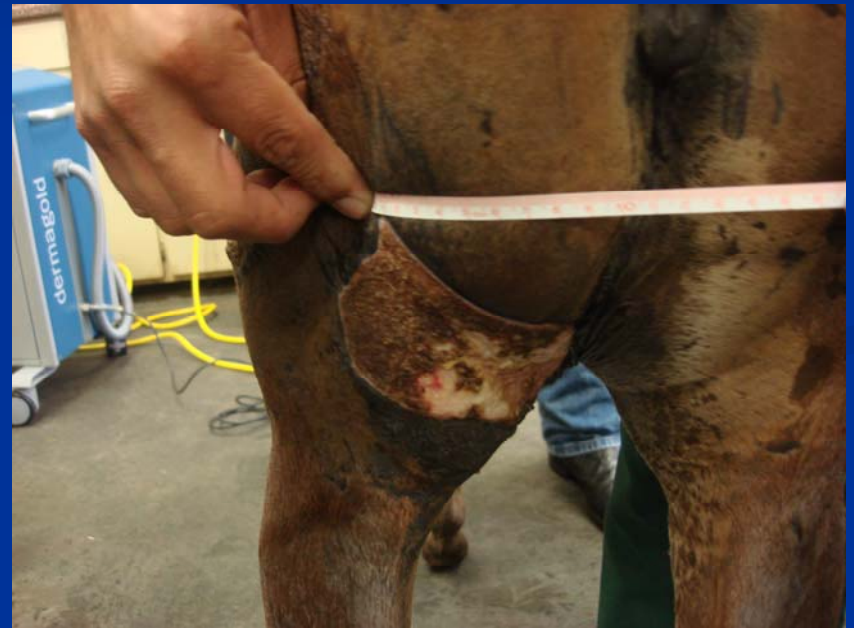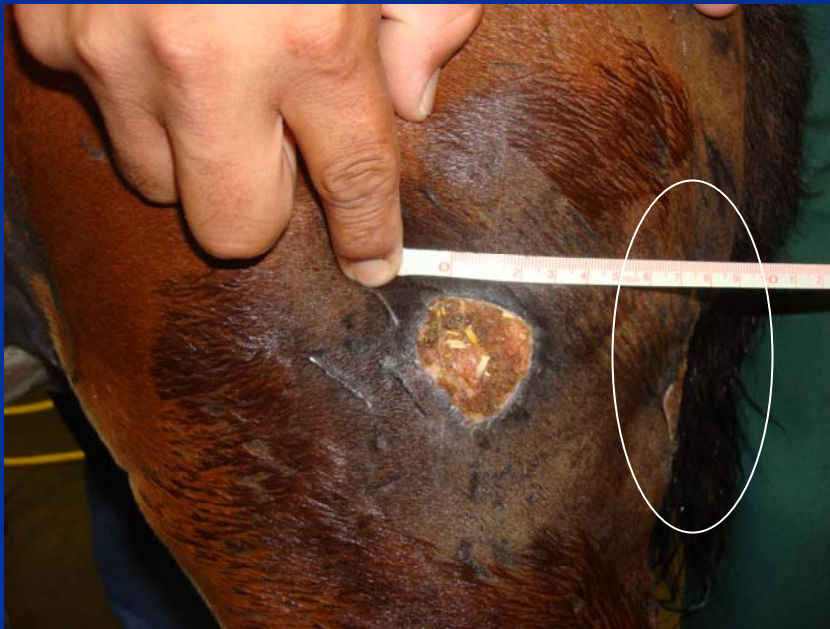9/4/08 Baseline: 2400 Pulses applied to wound bed and surrounding tissue with the Soft Focused head. No dressings applied post treatment, only Granulex spray.

# Left Hind Quarter



9/11/08 – 7 Days Post 1<sup>st</sup> Treatment; 2000 Pulses applied

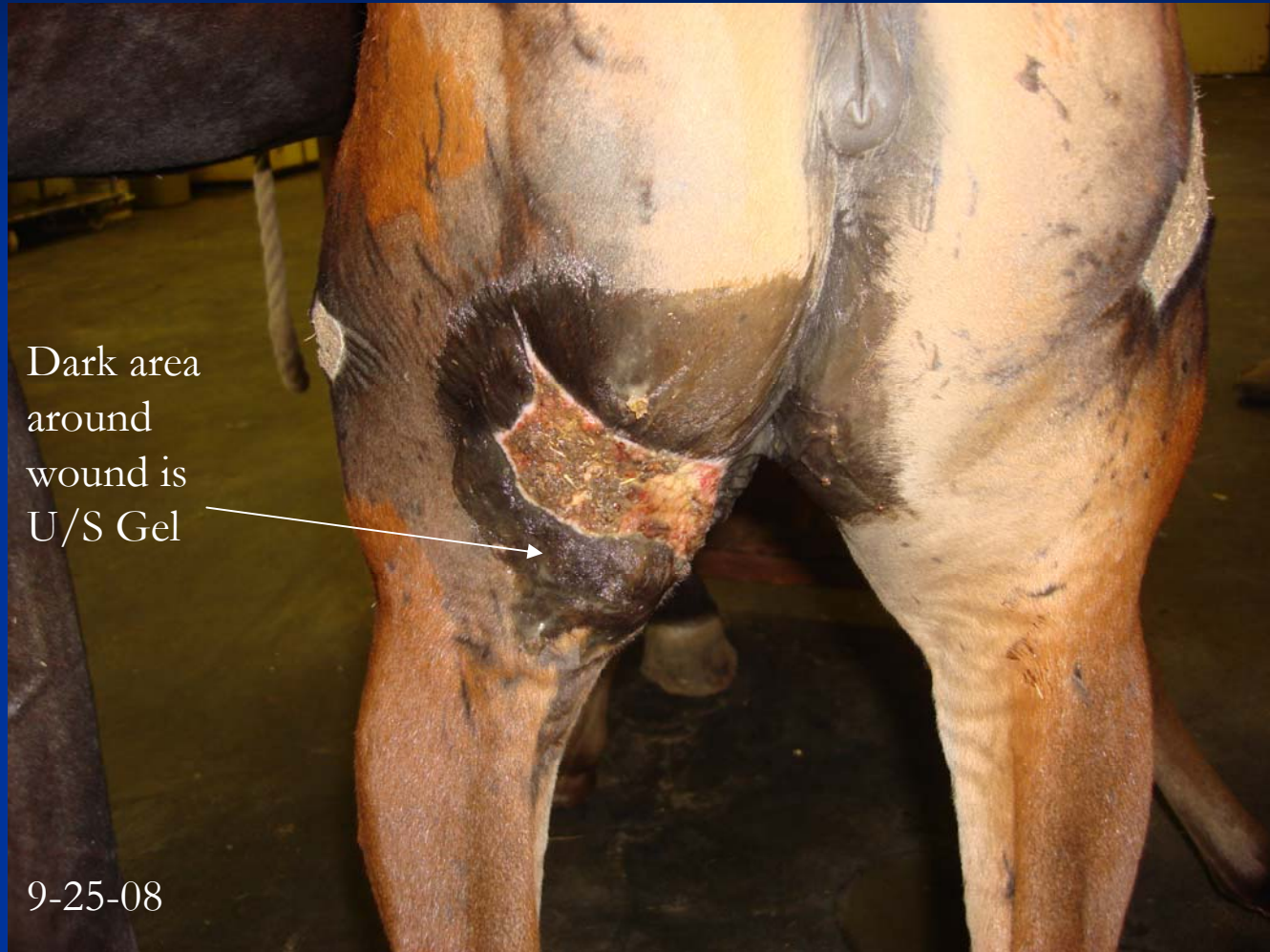# Left Hind Quarter



9/18/08 – 7 Days Post 2<sup>nd</sup> Treatment. 1600 Pulses Applied w/ Soft Focus Head

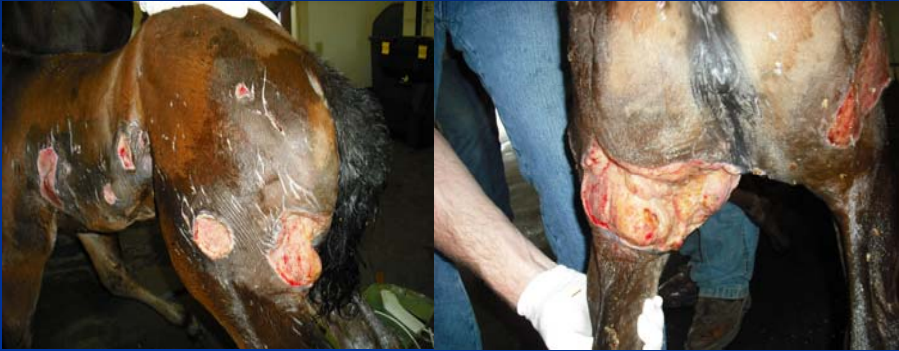

# Left Hind Quarter

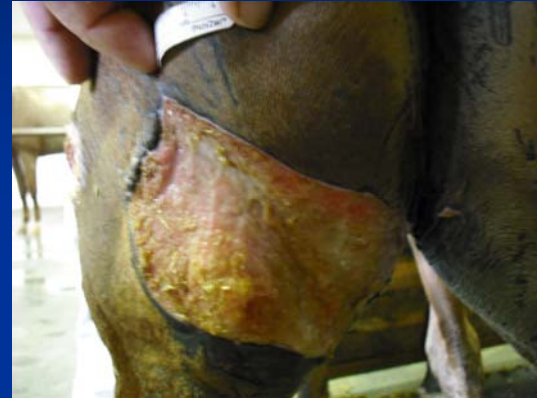

Applied final treatment of 1600 pulses.

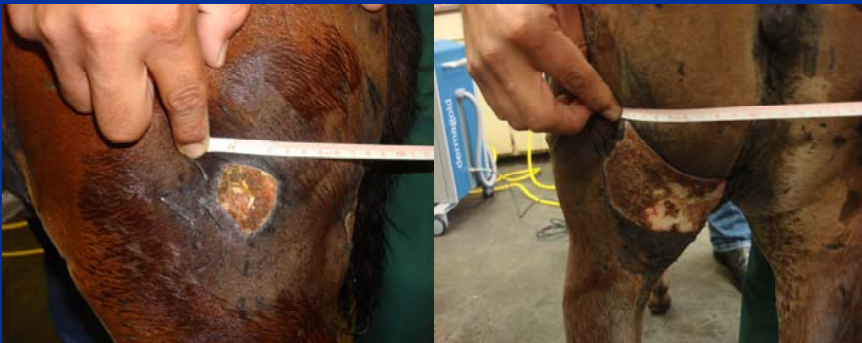# Left Hind Quarter – Progress Summary



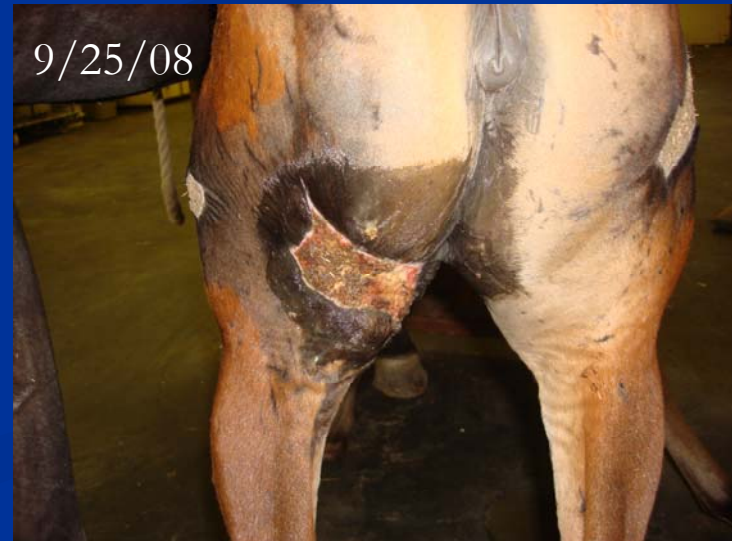9/4/08 – Baseline – 2400 Pulses Applied



9/11/08 – 2000 Pulses Applied



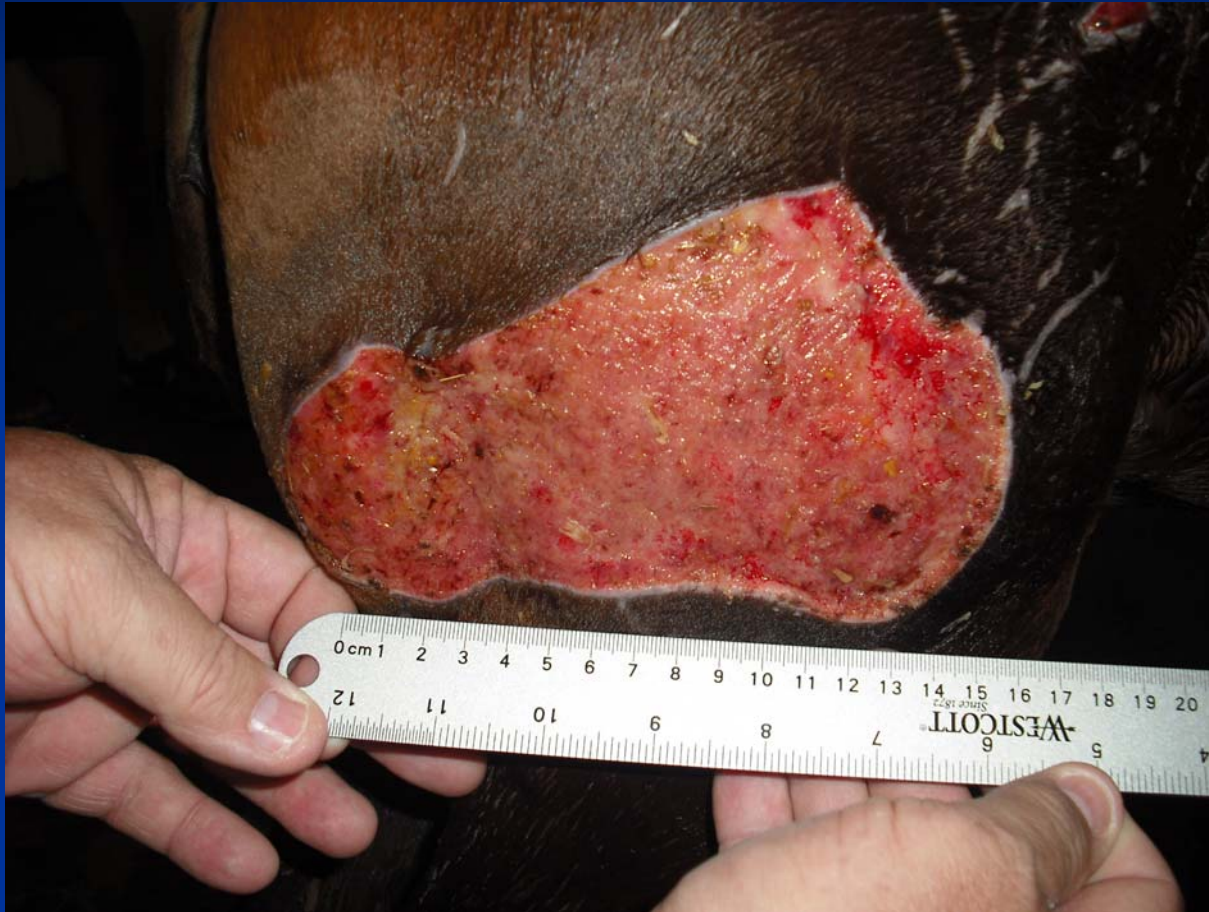9/18/08 – 1600 Pulses Applied



Applied final treatment of 1600 pulses



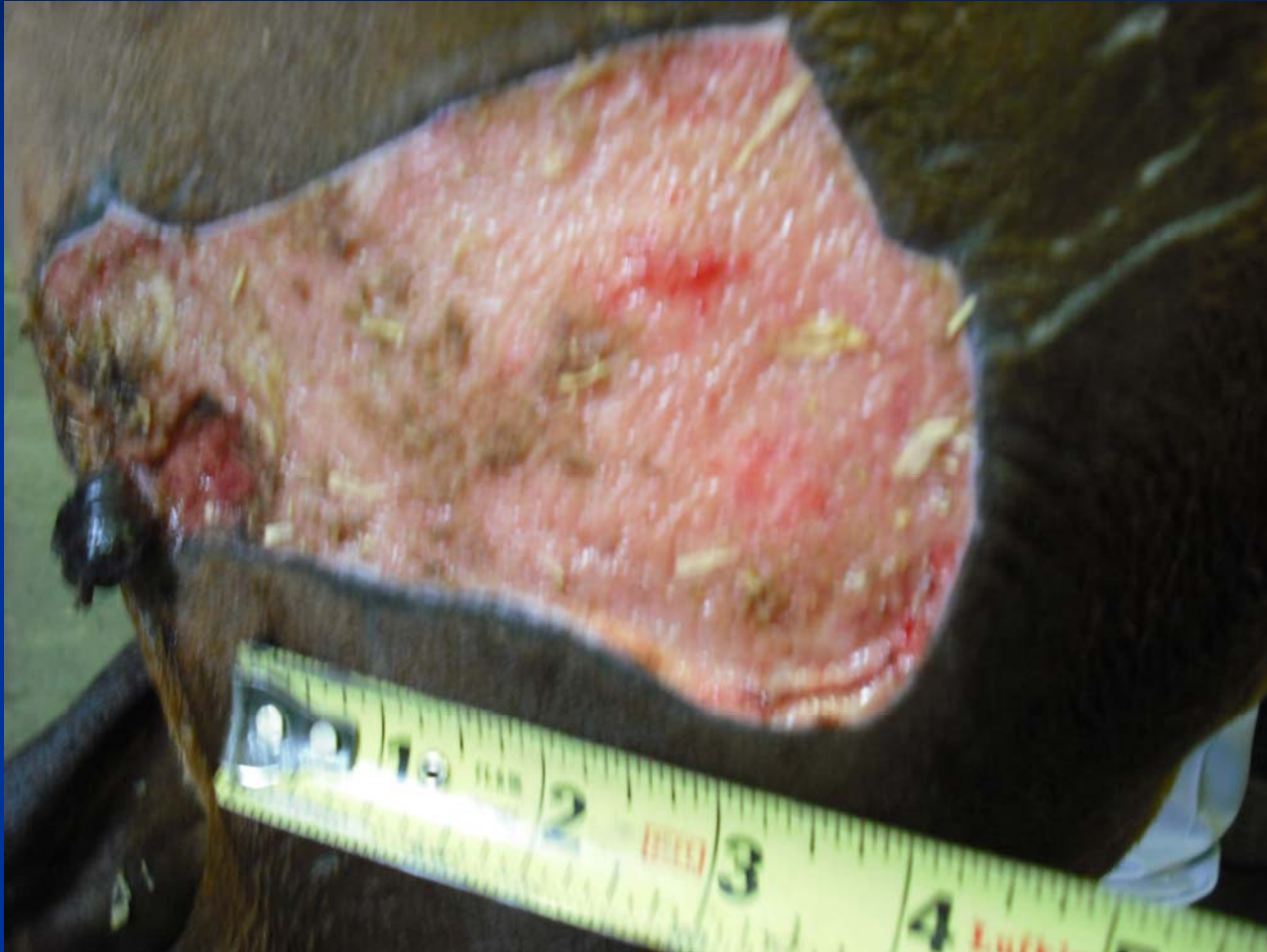
# Right Hip



9/4/08 – Baseline: 1200 Pulses Applied with SF Head

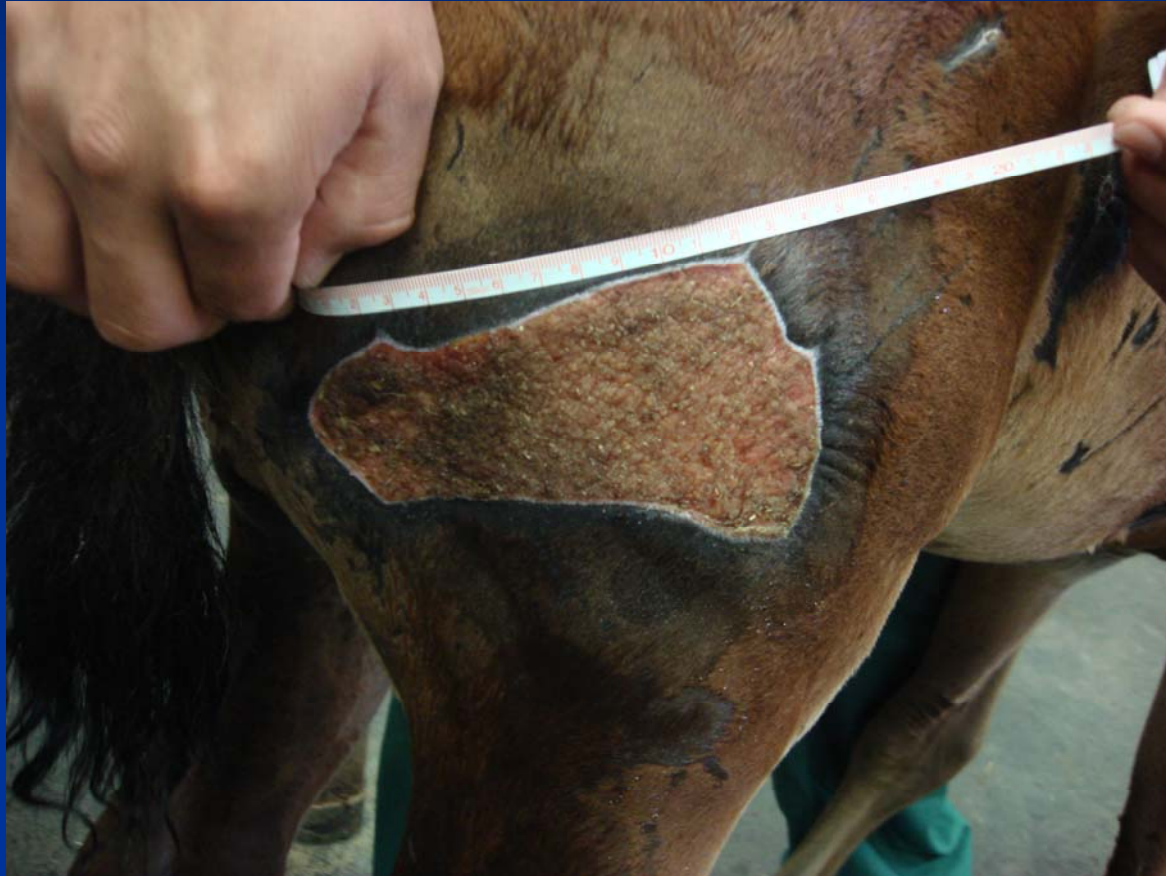

# Right Hip



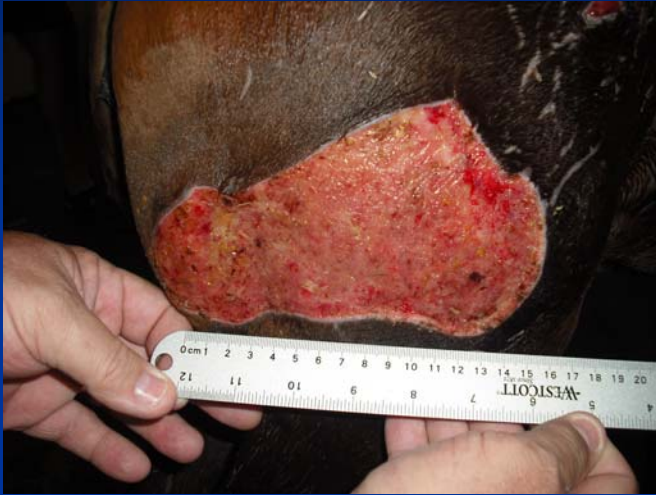9/11/08 – 7 Days Post 1<sup>st</sup> Treatment – 1200 Pulses Applied w/ SF Head

# Right Hip

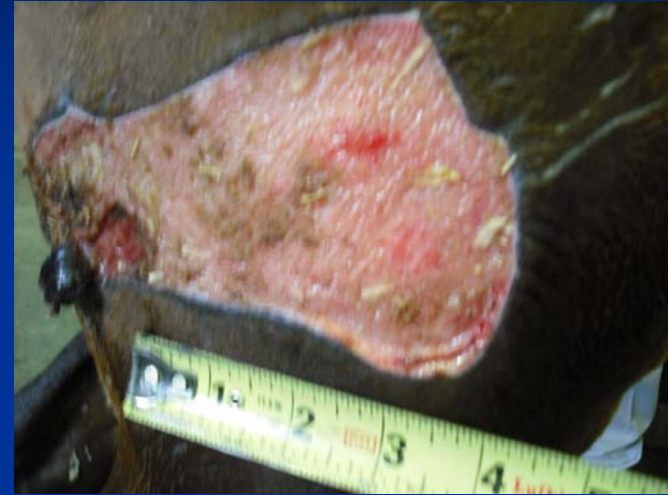


9/18/08 – 7 days Post 2<sup>nd</sup> Treatment – 600 Pulses Applied w/ SF Head

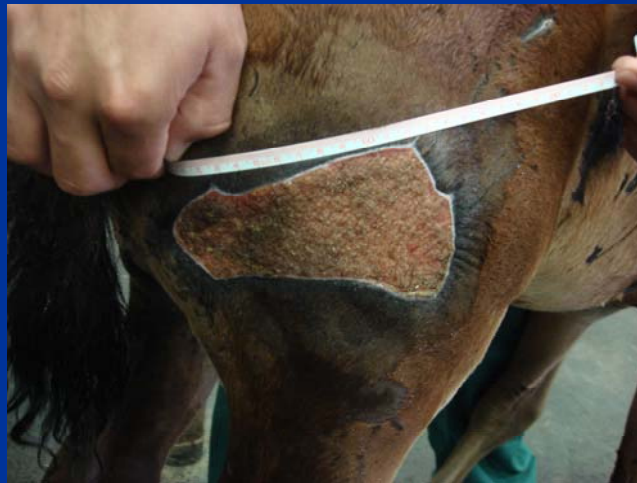# Right Hip Summary



9/4/08 - 1200 Pulses



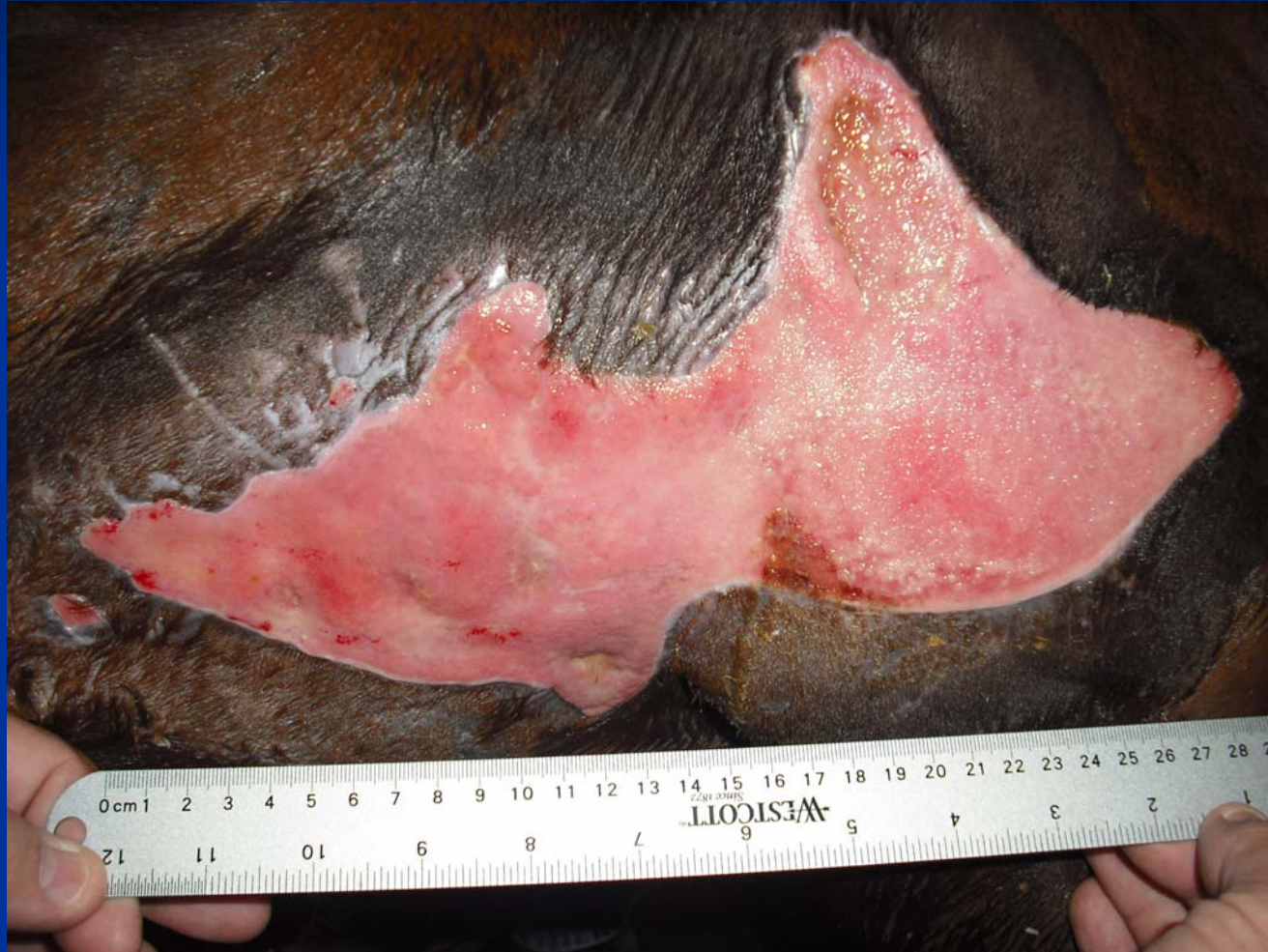9/11/08 - 1200 Pulses



9/18/08 – 600 Pulses

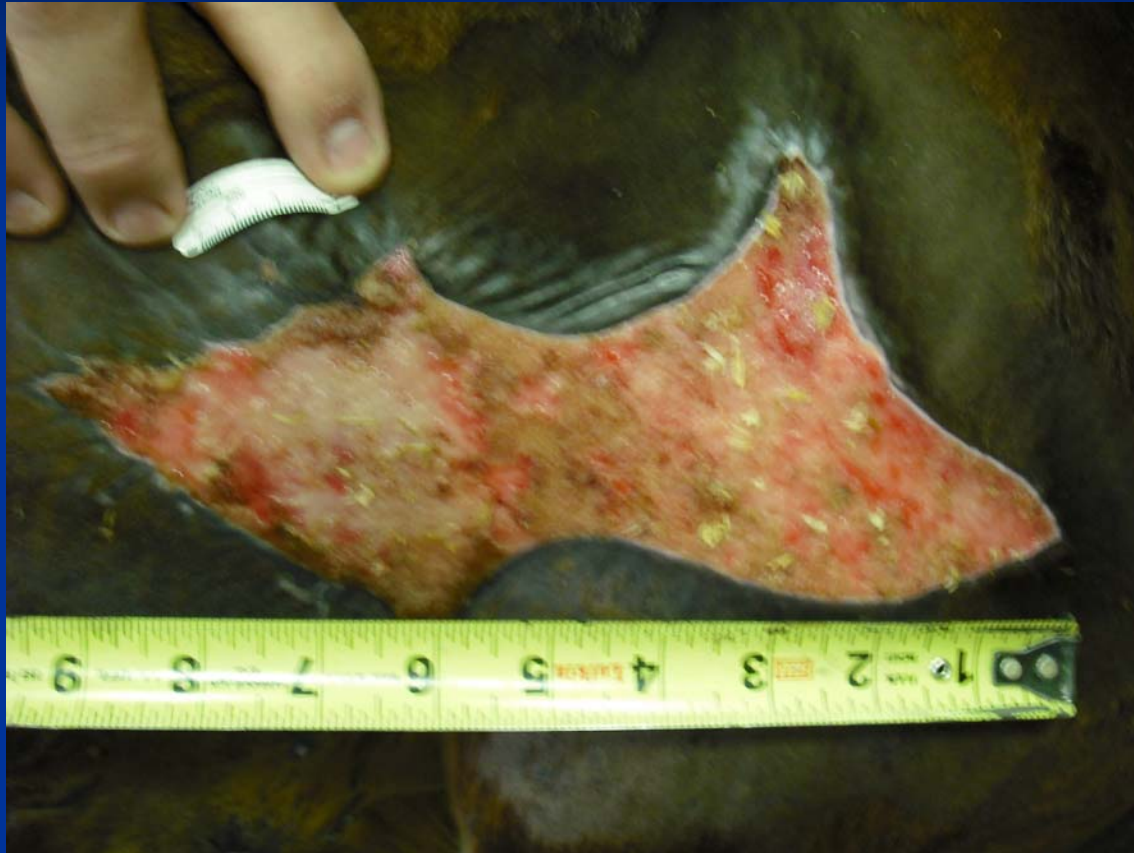

# Right Chest Wall



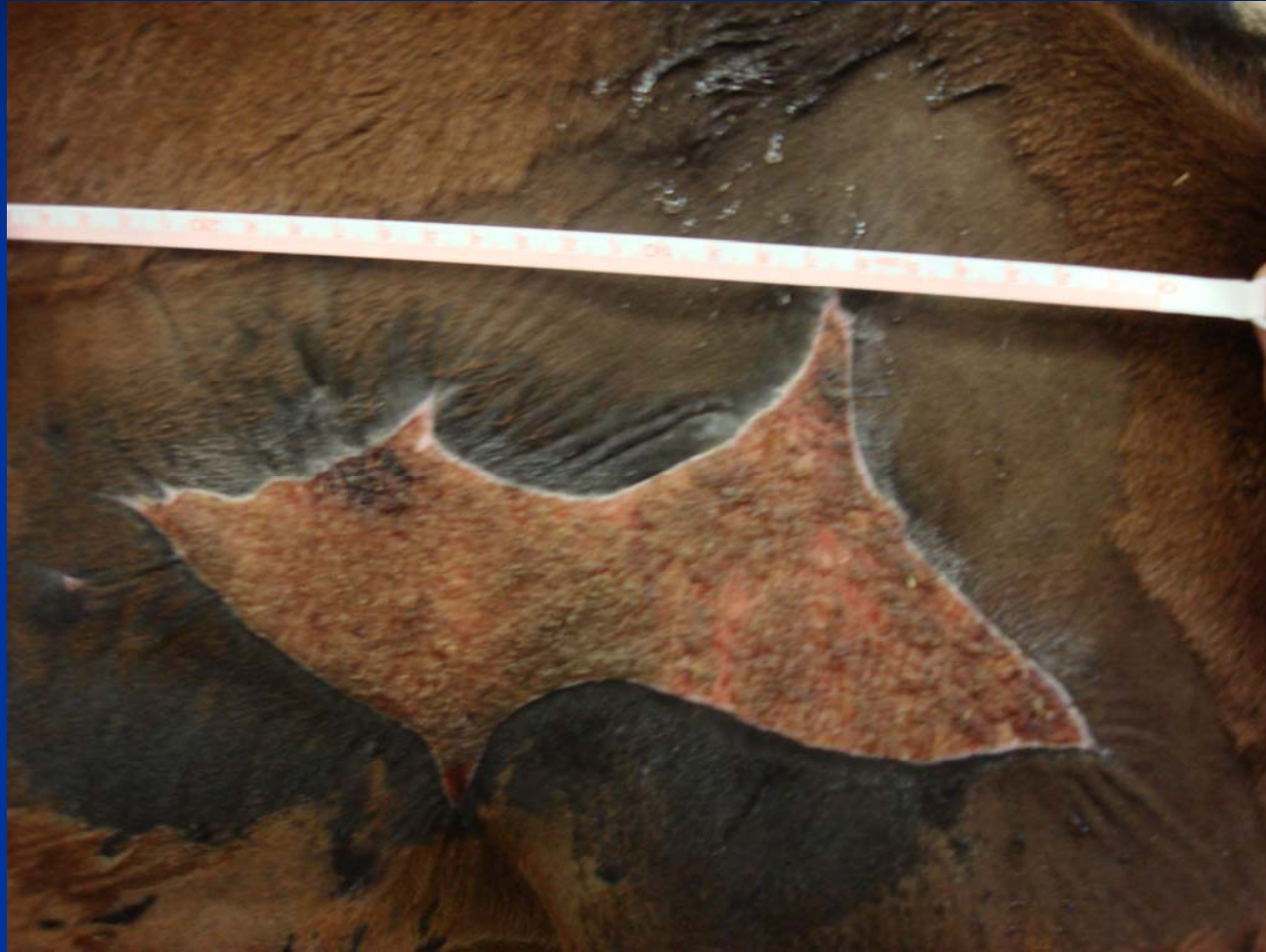9/4/08 Baseline – 1200 Pulses Applied w/ SF Head

# Right Chest Wall



9/11/08 – 7 Days Post 1<sup>st</sup> Treatment; Applied 1400 Pulses

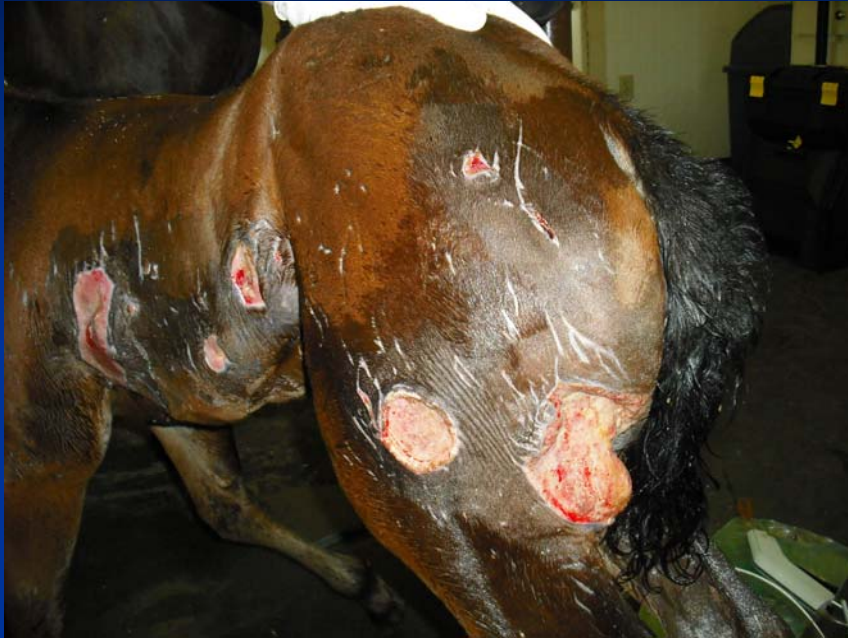# Right Chest Wall



9/18/08 – 7 Days Post 2<sup>nd</sup> Treatment; Applied 800 Pulses w/ SF Head

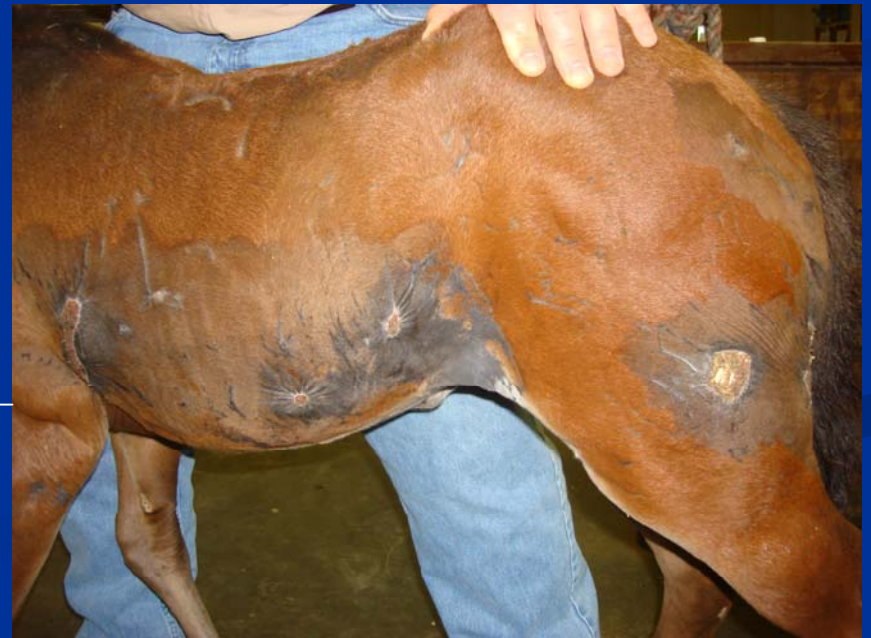

# Left Side

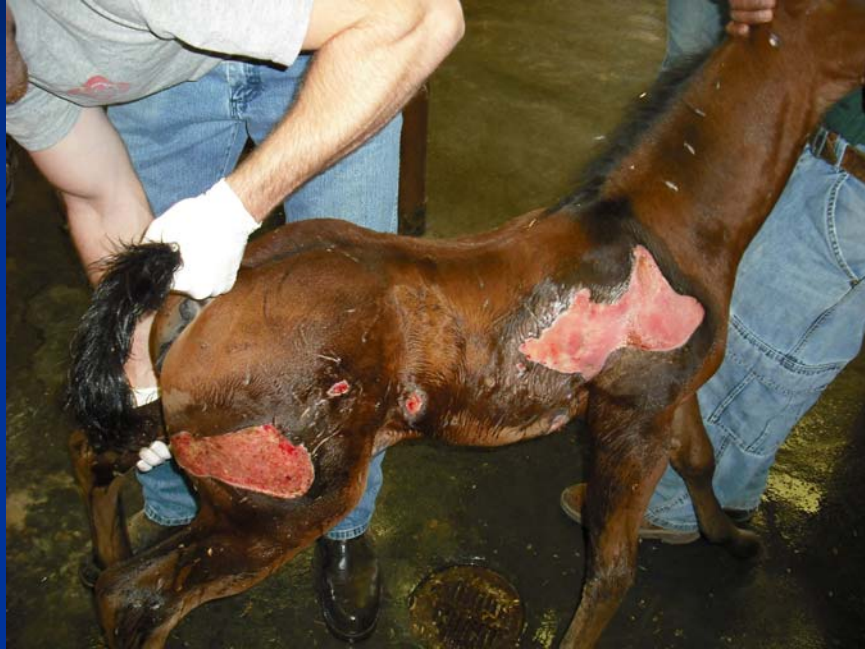

Baseline 9/4/08

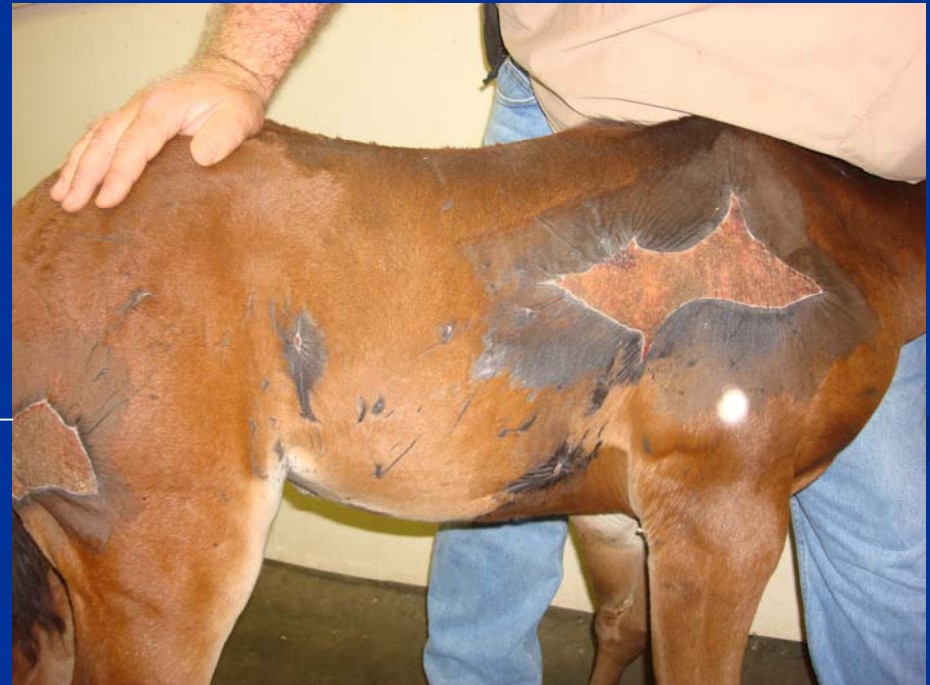9/18/08 Post 2  
Treatments



# Right Side



9/4/08 - Baseline



9/18/08 Post 2  
Treatments