

# A Case Series Examining the Use of Extracorporeal Shockwave Therapy (ESWT) to Treat Non-healing Venous Leg Ulcers

Matthew Regulski\*

DPM, FFPM, RCPS (Glasgow), ABMSP, Maharashtra, India.

## \*Correspondence:

Matthew Regulski, DPM, FFPM, RCPS (Glasgow), ABMSP, Maharashtra, India.

Received: 28 Dec 2022; Accepted: 25 Jan 2023; Published: 30 Jan 2023

**Citation:** Regulski M. A Case Series Examining the Use of Extracorporeal Shockwave Therapy (ESWT) to Treat Non-healing Venous Leg Ulcers. *Stem Cells Regen Med.* 2023; 7(1): 1-4.

## ABSTRACT

*With their complex pathogenesis, many wounds, such as venous leg ulcers (VLUs) and diabetic foot ulcers (DFUs), place a significant burden on the global healthcare system [1]. 93% of venous leg ulcers (VLUs) are open for more than a year due to a variety of factors such as comorbidities, lifestyle, and work demands. The most common causes are venous disease, arterial disease, and neuropathy. To avoid inappropriate treatment that could worsen the wound, delay healing, or harm the patient, a correct diagnosis is required. Wound chronicity can lead to complications such as infections, amputation, and even death. The purpose of this study is to determine the efficacy of ESWT therapy in patients with chronic non-healing venous leg ulcers who have not shown any signs of healing for more than a year [2].*

## Keywords

Wound care, Venous leg ulcers, Chronic wounds, Extracorporeal shockwave therapy (ESWT), Non-Healing, Macrophages, Inflammation, Healing, Chronic venous insufficiency.

## Key points

- For the two patients, 13 weekly sessions of ESWT resulted in faster healing time to complete closure on both chronic non-healing venous leg ulcers.
- By accelerating the healing of chronic wounds, ESWT may reduce complications such as infection, amputation, and mortality.
- Wound closure of both wounds suggests that incorporating ESWT into an evidence-based wound algorithm may be favorable.
- No adverse effects of ESWT during the 10–15-minute outpatient sessions.

## Introduction

Patients with wound chronicity face considerable anguish, a higher probability of infection, depression/anxiety, and a reduced quality of life. Patients with chronic wounds require a multidisciplinary team approach in which people from various specialized fields

combine their knowledge and skills, resulting in better outcomes. Evidence suggests that encouraging patients to actively participate in their own care, treatment, condition management, and support can improve outcomes and experiences [3].

Venous leg ulcers (VLUs) are the most common type of lower extremity ulcers with chronicity [4]. Chronic venous insufficiency (CVI) is a serious pathology that is underdiagnosed and undertreated. Pathophysiology of VLUs is complex, and healing is often delayed due to the multiple chemokines, cytokines, growth factors, proteases, and matrix metalloproteinases (MMPs) that are produced. Inflammation, inflammatory modulators, oxidative stress, and proteinase activity are uncoordinated in the pathogenesis of VLU. It is essential to comprehend the cellular and molecular processes that lead to the development of VLU. With a deeper comprehension of inflammatory pathways and potential processes, specific biomarkers could be identified and investigated for their role in the pathophysiology of VLU and as therapeutic targets for VLU healing [5]. Management of VLUs requires patience from both the provider and patient. Patient's must receive education about their condition and comply with their provider's recommendations for optimal outcomes [6].

---

Chronic non-healing wounds are wounds that do not move towards healing trajectory within 4 weeks. The healing process should be organized throughout all of the four healing phases (hemostasis, inflammation, proliferation, and remodeling) [7]. Due to the complexity of chronic wound care patients, many of whom have co-morbid conditions, a multidisciplinary approach and holistic management is required. Chronic non-healing wounds may require one or more advanced wound care treatment modalities including standard wound bed preparation, one or more debridement methods, advanced wound dressings, offloading, management of underlying issues, and/or compression therapy. If there are still no signs of wound healing, secondary treatments may include extracorporeal shock wave therapy (ESWT), ultrasound, negative wound pressure therapy (NPWT), cellular and tissue-based products, and hyperbaric oxygen therapy (HBOT).

Chronic non-healing wounds are characterized by persistent inflammation, therefore become stagnant in the inflammatory phase where there are elevated levels of pro-inflammatory cytokines, proteases, reactive oxygen species, senescent cells, infection, and a deficiency in amount and functionality of stem cells. Macrophages play a crucial part in every step of the healing process, and their instability leads in the inability to treat persistent wounds like non-healing venous leg ulcers. Macrophages are heterogeneous immune cells that play a vital role in all phases of wound healing, host defense responses, restoration and maintenance of homeostasis post-injury, infection, and malignancy. These cells secrete an array of factors including cytokines that support angiogenesis, extracellular matrix synthesis, fibroblast proliferation, and epithelialization which support tissue regeneration [8]. Paired with incompetent blood flow that favors thrombus formation, causing an inflammatory chain reaction to further fibrosis and valvular destruction [9]. Addressing and repairing the cellular and molecular causes of persistent inflammation in chronic wounds is a promising therapeutic method to return chronic wounds to a healing state and commence wound closure [10].

Extracorporeal shock wave therapy (ESWT) is a non-invasive treatment that involves producing transient pressure disturbances that propagate significantly in three-dimensional space outside the body and channeling acoustic energy inside the body to form therapeutic effects. Using an applicator head, ultrasonic gel as the contact medium, and a sterile barrier between the target and the applicator head, the shock waves generated by the medical device are delivered to the target site. In a wound, however, the acoustic impedance of the different tissue layers varies; these variances turn the acoustic energy of the shock waves into mechanical energy at the tissue interfaces, and the process of mechano-transduction converts this mechanical energy into biological regeneration [11].

Multiple ESWT effects are associated to neovascularization, reduced release of pro-inflammatory mediators, and macrophage activation, which increases blood flow perfusion and cell proliferation to accelerate tissue regeneration [10,12]. Low

shockwave intensities have been clinically recognized for diabetic and venous ulcer management, and it is a viable non-invasive method for improving healing of chronic wounds [13,14].

ESWT's role and effect on chronic wound macrophage activity and other macrophage-mediated disorders have been studied. ESWT improves chronic ulcer healing by increasing wound angiogenesis (CD31 staining), lowering the number of CD68-positive macrophages per biopsy area, and increasing macrophage activation overall. This was in accordance to wound measurements and immunohistochemical analysis. These *in vitro* (controlled environment) and *in vivo* (within the living) findings point to shockwaves as important regulators of macrophage functions associated with wound healing [15].

## Methods

In 2022, the case series was conducted. During the study period, two single center clinic patients who met the eligibility criteria and agreed to ESWT treatment were identified; two of whom also provided written informed consent to have their details included in the case series. Both patients had chronic non-healing venous leg ulcers (VLUs), which were validated by a venous reflux study, and adequate arterial flow, which was confirmed by arterial dopplers with toe pressures. Sharp debridement, an optimal moist environment, multi-layer compression bandaging, biofilm management, and skin substitute applications were all used on their venous ulcerations. Shockwave therapy (ESWT) was applied weekly for 10–15-minute sessions: 2,000 shocks at 3.5MHz. Total of 4200m.

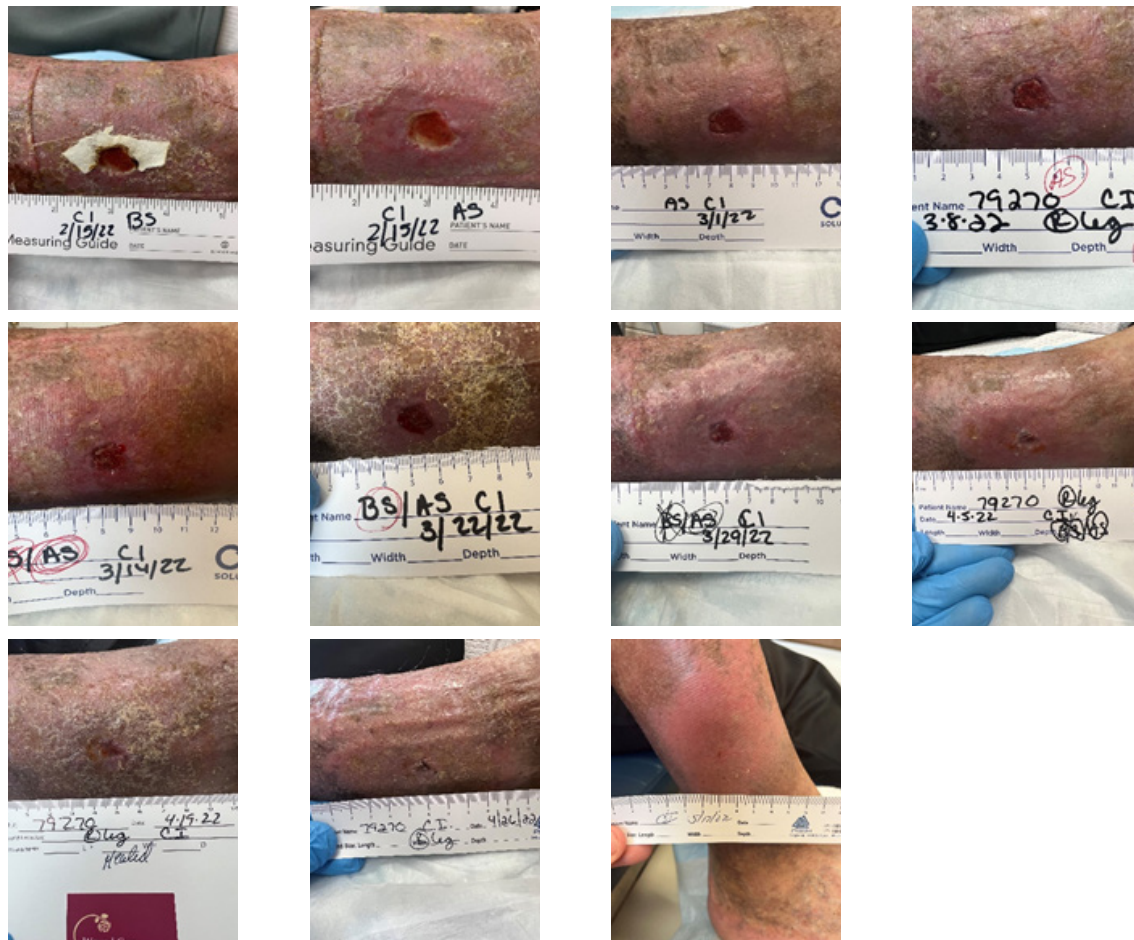
## Case Series

### Patient A: Chronic Non-healing Venous Leg Ulcer (VLU)

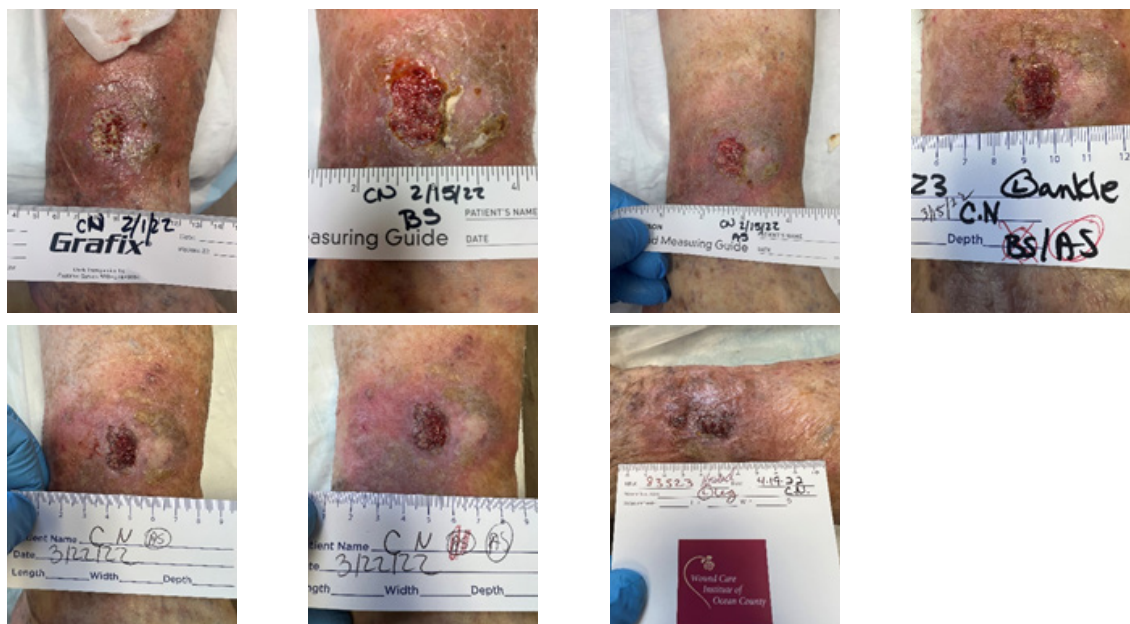53-year-old male referred for a non-healing venous leg ulceration with a wound duration > 1 year. This patient was previously treated for pelvic compression syndrome with stents placed in the common femoral vein. Per doppler, the patient's arterial flow was robust. Biopsies were taken from various areas, and the results were negative for skin cancer. There were 10 neonatal foreskin applications prior. Wound bed preparation included biofilm management by utilizing an anti-biofilm wound gel, collagen dressing, absorbent hydrofiber dressing, and a multi-layer compression bandage. Weekly shockwave therapy commenced.

### Patient B: Chronic Non-healing Venous Leg Ulcer (VLU)

Longtime smoker, 63-year-old male, referred for a non-healing venous leg ulceration with duration >1 year. Arterial doppler demonstrated adequate arterial flow, however a venous reflux study revealed significant GSV reflux necessitating endovenous ablation. Wound bed preparation included sharp debridement, biofilm management by utilizing an anti-biofilm wound gel, collagen dressing, absorbent hydrofiber dressing, and a multi-layer compression bandage. Weekly shockwave therapy commenced.



**Patient A:** Wound duration >1 year, left lower leg vascular ulcer at baseline on the first ESWT session, moving towards healing trajectory to complete closure after 13 weeks. Wound images captured prior to ESWT session, same day. Photographs and cases used with permission.



**Patient B:** Wound duration >1 year, left lower leg vascular ulcer at baseline on the first ESWT session, moving towards healing trajectory to complete closure after 13 weeks. Wound images captured prior to ESWT session, same day. Photographs and cases used with permission.

## Discussion/Conclusion

This case series indicates that ESWT therapy for non-healing venous leg ulcers is an effective adjunct therapy in moving chronic wounds towards healing. ESWT proved to be a convenient, outpatient treatment without anesthesia and adverse effects. ESWT was applied every 7 days for 6 sessions that were 10-15 minutes in duration. Incorporating ESWT into the wound care algorithm for chronic non-healing wounds can be advantageous because of its cost-effectiveness, accessibility, non-invasiveness, enhanced healing, reduction in hospitalizations, decreased risk of infection, fewer amputations, and reduced morbidity.

## Acknowledgement

Softwave® Tissue Regeneration Technologies, LLC supported this case series.

## References

1. Richmond NA, Maderal AD, Vivas AC, et al. Evidence-based management of common chronic lower extremity ulcers. *Dermatol Ther*. 2013; 26: 187-196.
2. Shubhangi Vinayak Agale. Chronic Leg Ulcers: Epidemiology, Aetiopathogenesis, and Management. *Ulcers*. 2013.
3. Vahdat S, Hamzehgardeshi L, Hessam S, et al. Patient involvement in health care decision making: a review. *Iran Red Crescent Med J*. 2014; 16: e12454.
4. Lal BK. Venous ulcers of the lower extremity: Definition, epidemiology, and economic and social burdens. *Semin Vasc Surg*. 2015; 28: 3-5.
5. Raffetto JD. Pathophysiology of wound healing and alterations in venous leg ulcers-review. *Phlebology*. 2016; 31:56-62.
6. Robles-Tenorio A, Lev-Tov H, Ocampo-Candiani J, et al. Venous Leg Ulcer. [Updated 2022 Apr 14]. In: StatPearls [Internet]. Treasure Island (FL): StatPearls Publishing. 2022.
7. Frykberg RG, Banks J. Challenges in the treatment of chronic wounds. *Adv Wound Care*. 2015; 4: 560-582.
8. Hesketh M, Sahin K.B, West Z.E, et al. Macrophage Phenotypes Regulate Scar Formation and Chronic Wound Healing. *Int J Mol Sci*. 2017; 7: 1545.
9. Mansilha A, Sousa J. Pathophysiological Mechanisms of Chronic Venous Disease and Implications for Venoactive Drug Therapy. *Int J Mol Sci*. 2018; 19: 1669.
10. Murray P, Macrophage Polarization. *Ann Rev Physiol*. 2017; 79: 541-566.
11. Lohrer H, Nauck T, Korakakis V, et al. Historical ESWT paradigms are overcome: a narrative review. *Biomed Res Int*. 2016; 3850461.
12. Mittermayr R, Hartinger J, Layr M, et al. Extracorporeal Shock Wave Therapy (ESWT) minimizes ischaemic tissue necrosis irrespective of application time and promotes tissue revascularization by stimulating angiogenesis. *Ann Surg*. 2011; 253: 1024-1032.
13. Zhang L, Weng C, Zhao Z, Fu X, et al. Extracorporeal shock wave therapy for chronic wounds: A systematic review and meta-analysis of randomized controlled trials. *Wound Repair Regen*. 2017; 4: 697-706.
14. Cooper B, Bachoo P, Extracorporeal shock wave therapy for the healing and management of venous leg ulcers. *Cochrane Database Syst. Rev*. 2018; 6: CD011842.
15. Marcus B. Extracorporeal Shock Wave Therapy (Eswt) For the Treatment of Chronic, Non-Healing Wounds: A Case Series. *Stem Cells Regen Med*. 2020; 4: 1-7A.