



MTS CLINICAL & PRECLINICAL STUDIES

Compendium of Published Study Abstracts

Edition 01-2024

Witness. The Spark of Life.

MTS Medical UG (limited liability) | Robert-Bosch-Str. 18 | 78467 Konstanz |
Germany | www.mts-medical.com

Content

List of Studies

Abstracts

CLINICAL STUDIES	19
1. Orthopedics	19
1.1. Tendinopathies / Soft Tissue Disorders	19
1.2. Bone Healing Disorders	37
1.3. Orthodontics	54
2. Dermatology	57
2.1. Acute Wounds and Burns	57
2.2. Chronic Wounds and Ulcers	60
2.3. Pathologic Scarring	79
2.4. Lymphoedema	82
3. Urology	83
3.1. Peyronie`s Disease	83
3.2. Erectile Dysfunction	85
3.3. Chronic Pelvic Pain / Chronic Prostatitis	105
3.4. Premature Ejaculation	106
3.5. Penile Augmentation	107
3.6. Testicular Function	108
3.7. Vestibulodynia	108
3.8. Persistent Genital Arousal Disorder / Genito-Pelvic Dysesthesia	112
3.9. Lithotripsy - Kidney and Ureter Stone Disease	114
4. Neurology	114
4.1. Spinal Cord Injury	114
4.2. Limb Loss / Phantom Pain / Sensory Reinnervation	116
4.3. Fibromyalgia	117
PRECLINICAL STUDIES / BASIC RESEARCH	119
5. Orthopedics	119
5.1. Tendinopathies / Soft Tissue Disorders	119
5.2. Bone Healing Disorders	123
5.3. Orthodontics	127
6. Dermatology	137
6.1. Acute Wounds and Burns	137
6.2. Chronic Wounds and Ulcers	145



6.3.	Pathologic Scarring	152
7.	Urology	152
7.1.	Peyronie`s Disease.....	152
7.2.	Erectile Dysfunction.....	154
7.3.	Chronic Pelvic Pain / Chronic Prostatitis	156
7.4.	Stress Urinary Incontinence	156
7.5.	Lithotripsy - Kidney and Ureter Stone Disease.....	157
8.	Neurology	158
8.1.	Spinal Cord Injury	158
8.2.	Nerve Grafting / Peripheral Nerve Regeneration.....	163
8.3.	Transcranial ESWT	170
9.	(Stem / Progenitor) Cell Activation	171
10.	(Lymph-) Angiogenesis, Inflammatory Control and Cardiology	174
11.	Physics / In Vitro Engineering	199
12.	Bibliography	203

List of Studies

CLINICAL STUDIES.....	19
1. Orthopedics.....	19
1.1. Tendinopathies / Soft Tissue Disorders.....	19
1.1.1. Combination of ESWT and Manual Medicine in the Treatment of Myofascial Pain and Trigger Points- Why Teamwork Will Surpass (Thiele et al., 2023).....	19
1.1.2. Focal Extracorporeal Shockwave Therapy (ESWT) for Ankle Impingement in Athletes (Ngai et al., 2023).....	20
1.1.3. Effect of Focal Extracorporeal Shockwave Therapy on Knee Focal Cartilage Defect in Athletes (Ngai et al., 2023)	21
1.1.4. An 8-year Retrospective Study of the Treatment Outcome and Safety of Focal Extracorporeal Shockwave Therapy (A. Ngai et al., 2022)	23
1.1.5. ESWT in Pubic Osteitis in Football Players (J. R. Aranzabal et al., 2022)	24
1.1.6. Shock Wave Treatment in Patients with Unilateral Spasticity of the Upper Limb After Ischemic or Hemorrhagic Stroke (Holfeld et al., 2021)	24
1.1.7. Efficacy of Unfocused Medium-Intensity Extracorporeal Shock Wave Therapy (MI-ESWT) for Plantar Fasciitis (Fansa et al., 2020)	25
1.1.8. Effect of a Single Administration of Focused Extracorporeal Shock Wave in the Relief of Delayed-Onset Muscle Soreness: Results of a Partially Blinded Randomized Controlled Trial (Fleckenstein et al., 2017)	25
1.1.9. Prospective Cohort Study Examining Short Term Changes in Pain after Application of Extracorporeal Shockwave Therapy (ESWT) in 178 Consecutive Patients (Aston Ngai et al., 2016)	26
1.1.10. Influence of Medical Shock Waves on Healthy Muscle Tissue (Vincent et al., 2016)	27
1.1.11. Radial Shockwave Therapy and High Frequency Laser Combined Treatment in Elbow Tendinopathies (Leal et al., 2014)	27
1.1.12. Extracorporeal Shockwave Therapy in Calcific Tendinosis of the Rotator Cuff: Comparison of radial and Focal Treatment (Edson Serrano, Karim Flores, Jean Carlos Criado, 2014)	29
1.1.13. The Significance of Inflammatory Tendon Hypervascularization for the Treatment Results with ESWT: Are the Actual Recommendation Still Valid? (Markus Gleitz 2014)	29
1.1.14. Results of Shockwave Treatment in Lateral Epicondylitis in Relation to Tendon Changes in Power Doppler (Gleitz, 2013)	30
1.1.15. Comparison of Low Dose and High Dose Shockwave Application in Plantar Fasciitis (Georgi et al., 2012)	31
1.1.16. Shockwave Medicine for Carpal Tunnel Syndrome (Barillas et al., 2012)	31
1.1.17. Effects of Extracorporeal Shockwave Therapy on Spasticity in Cerebral Palsy (CP): Our Experience (pilot study) (d'Agostino, et al., 2011)	33
1.1.18. Efficiency of Shockwave Treatment for Pain Reduction in the Shoulder (Erich Georgi, Thomas Georgi 2010)	33



1.1.19. Extracorporeal Shock Wave Therapy for Calcifying Tendinitis of the Shoulder (Hsu et al., 2008)	34
1.1.20. Our Experience with Shockwave Therapy (Fernando Dujo Rodriguez, 2008).....	34
1.1.21. Requirements for Research in ESWT Management of Spasticity (A. M. Larking, K. A. S. Hall, 2008)	35
1.1.22. Focused and Defocused ESWT. The Comparison of the Results in the Treatment of Heel Spurs (Sergej Marx, Richard Thiele, 2007)	36
1.1.23. Use of Extra-corporeal Shock Wave Therapy in the Treatment of Proximal Plantar Fasciitis: A Randomized, Prospective, Double-Blind, Placebo-Controlled Study (Naidoo et al., 2002)	36
1.2. Bone Healing Disorders	37
1.2.1. Shockwave Treatment vs Surgery for Proximal Fifth Metatarsal Stress Fractures in Soccer Players: A Pilot Study (Ramon et al., 2023).....	37
1.2.2. Focused Extracorporeal Shockwave Therapy for Youth Sports-related Apophyseal Injuries: Case Series (Shafshak & Amer, 2023)	38
1.2.3. Double Screw versus Angular Stable Plate Fixation of Scaphoid Waist Nonunions in Combination with Intraoperative Extracorporeal Shockwave Therapy (ESWT) (Quadlbauer et al., 2023)	38
1.2.4. ESWT Treatment of Compromised Clavicle Fracture Near Lung Tissue (Slezak et al., 2023)...	39
1.2.5. Effective Treatment of Compromised Clavicle Fracture of the Medial and Lateral Third Using Focused Shockwaves (Mittermayr et al., 2022)	40
1.2.6. The Role of Shockwaves in the Enhancement of Bone Repair - From Basic Principles to Clinical Application (Mittermayr R, Haffner N, Feichtinger X, 2021).....	41
1.2.7. High-Energy Extracorporeal Shockwave Therapy in Humeral Delayed and Non-Unions (Dahm et al., 2021).....	41
1.2.8. Shockwave is Equally Effective in Treating Tibial Nonunion Compared to Standard of Care Surgery but Cause Significantly Less Direct Health Care Costs (Mittermayr et al., 2021)	42
1.2.9. Successful Salvage via Re-Osseointegration of a Loosened Implant in a Patient with Transtibial Amputation (Gstoettner et al., 2020).....	43
1.2.10. Shockwave Treatment for Specific Injuries Including Stress Fractures in Soccer Athletes (Ramon et al., 2020).....	43
1.2.11. Treatment of Scaphoid Waist Nonunion by One, Two Headless Compression Screws or Plate with or without Additional Extracorporeal Shockwave Therapy (Quadlbauer et al., 2019).....	44
1.2.12. Extracorporeal Shockwave Therapy for the Treatment of Scaphoid Delayed Union and Nonunion: a Retrospective Analysis Examining the Rate of Consolidation and Further Outcome Variables (Fallnhauser et al., 2019)	45
1.2.13. Effect of Unfocused Extracorporeal Shockwave Therapy on Bone Mineral Content of Twelve Distal Forearms of Postmenopausal Women: A Clinical Pilot Study (Koolen et al., 2019)	45
1.2.14. Extracorporeal Shockwave Therapy (ESWT) Ameliorates Healing of Tibial Fracture Non-Union Unresponsive to Conventional Therapy (Haffner et al., 2016)	46

1.2.15. Extracorporeal Shockwave Therapy (ESWT) Ameliorates Healing of Tibial Fracture Non-Union Unresponsive to Conventional Therapy (Mittermayr et al., 2015)	47
1.2.16. Combined Treatment of Scaphoid Non-Union by Surgery and Additional Extracorporeal Shockwave Therapy (ESWT) (Quadlbauer et al., 2013).....	47
1.2.17. ESWT: An Extraordinary Tool for Tissue Regeneration and Remodeling (D'Agostino et al., 2013)	48
1.2.18. Development of a Prognostic Naive Bayesian Classifier for Successful Treatment of Nonunions (Stojadinovic et al., 2011).....	49
1.2.19. Quality Control of ESWT in the Treatment of Non-Union Fractures (Schaden et al., 2011)	49
1.2.20. ESWT for Non-Union Fractures – Economic Aspects (Schaden et al., 2011).....	50
1.2.21. ESWT in Foot Navicular Stress Fracture of a High Performance (Sergio Abello, Carlos Leal, 2011)	51
1.2.22. Shock Wave Therapy Compared with Intramedullary Screw Fixation for Nonunion of Proximal Fifth Metatarsal Metaphyseal-Diaphyseal Fractures (Furia et al., 2010).....	51
1.2.23. Shock Wave Therapy Versus Intramedullary Screw Fixation for Nonunion of the Proximal Fifth Metatarsal Metaphyseal Diaphyseal (Jones) Fracture (Furia et al., 2010).....	52
1.2.24. Extracorporeal Shockwave Therapy for Non-Unions and Delayed Healing Fractures (A. Valentin et al., 2007 / 2008)	53
1.2.25. Extracorporeal Shock Wave Therapy of Nonunion or Delayed Osseous Union (Schaden et al., 2001)	54
1.3. Orthodontics.....	54
1.3.1. Comparative Study Between the Effect of Shockwave Therapy and Low-Intensity Pulsed Ultrasound (LIPUS) on Bone Healing of Mandibular Fractures (Clinical & Radiographic Study) (Ahmed et al., 2022).....	54
1.3.2. Effect of Extracorporeal Shockwave Therapy (ESWT) on Pulpal Blood Flow After Orthodontic Treatment: a Randomized Clinical Trial (Falkensammer et al., 2016)	55
1.3.3. Impact of Extracorporeal Shockwave Therapy on Tooth Mobility in Adult Orthodontic Patients: a Randomized Single-Center Placebo-Controlled Clinical Trial (Falkensammer et al., 2015)	55
1.3.4. Impact of Extracorporeal Shock Wave Therapy (ESWT) on Orthodontic Tooth Movement-a Randomized Clinical Trial. (Falkensammer, Arnhart, et al., 2014)	56
1.3.5. Impact of Extracorporeal Shock-Wave Therapy on the Stability of Temporary Anchorage Devices in Adults: a Single-Center, Randomized, Placebo-Controlled Clinical Trial. (Falkensammer, Rausch-Fan, et al., 2014)	57
2. Dermatology	57
2.1. Acute Wounds and Burns.....	57
2.1.1. Prospective Randomized Phase II Trial of Accelerated Reepithelialization of Superficial Second-Degree Burn Wounds Using Extracorporeal Shock Wave Therapy (Ottomann et al., 2012)	57
2.1.2. Prospective Randomized Trial of Accelerated Re-epithelization of Skin Graft Donor Sites Using Extracorporeal Shock Wave Therapy (Ottomann et al., 2010)	58



2.1.3. Accelerated Reepithelisation of IIb° Scald Through Extracorporeal Shock Wave Therapy (Ottomann et al., 2009).....	58
2.1.4. Accelerated Healing of IIa-Burns Under the Influence of ESWT (Ottomann et al., 2008)	59
2.2. Chronic Wounds and Ulcers	60
2.2.1. Low Intensity Shockwave Treatment Modulates Macrophage Functions Beneficial to Healing Chronic Wounds (Holsapple et al., 2021).....	60
2.2.2. Extracorporeal Shock Wave Therapy (Eswt) For the Treatment of Chronic, Non-Healing Wounds_A Case Series (Marcus, 2020).....	60
2.2.3. The Role of Extracorporeal Shock Wave Therapy and Manual Lymphatic Drainage in Chronic Ulcers Treatment (Saggini et al., 2016)	61
2.2.4. 10-Year Experience in the Treatment of Sub-Acute and chronic Wounds with Extracorporeal Shockwave Therapy in the Trauma Center Meidling, Vienna, Austria (Dahm et al., 2015).....	61
2.2.5. Effectiveness of Extracorporeal Shock Wave Lithotripsy to Treat Dystrophic Calcinosis Cutis Ulcers (Delgado-Márquez et al., 2015).....	62
2.2.6. Influence of Treatment Frequency on Healing Outcome in Subacute and Chronic Wounds (Mittermayr et al., 2014).....	62
2.2.7. Shockwave Medicine and Leprosy - The Ultimate Challenge for Skin Regeneration by Mechanotransduction (Leal et al., 2014)	63
2.2.8. The Role of ESWT and Manual Lymphatic Drainage in the Treatment of Grade II Chronic Ulcers (Saggini et al., 2014)	65
2.2.9. Chronic Ulcers: Treatment with Unfocused Extracorporeal Shock Waves (Saggini et al., 2013)	65
2.2.10. Shock Wave Therapy for Systemic Sclerosis (Belloli et al., 2013)	66
2.2.11. Unfocused Shockwave Treatment of Skin injuries (Rerez Gomez et al., 2012)	66
2.2.12. Defocused ESWT for Chronic Skin Lesions – Treatment Interval Does Not Seem to Influence Healing Outcome (Mittermayr et al., 2011).....	67
2.2.13. The Influence of Comorbidities and Etiologies on the Success of Extracorporeal Shock Wave Therapy for Chronic Soft Tissue Wounds: Midterm Results (Wolff et al., 2011)	68
2.2.14. Prospective Trials of ESWT for Soft Tissue Indications (Stojadinovic et al., 2011).....	68
2.2.15. Combat Wound Initiative Program (Stojadinovic et al., 2010).....	69
2.2.16. Randomized Control of Extracorporeal Shock Wave Therapy Versus Placebo for Chronic Decubitus ulceration (Larking et al., 2010)	69
2.2.17. Extracorporeal Shockwave Treatment for Chronic Diabetic Foot Ulcers (Wang et al., 2009) .	70
2.2.18. Summation of the Experiences Using Defocused ESWT for Chronic Lesions in the Trauma Center Meidling (Mittermayr et al., 2009).....	70
2.2.19. Prophylactic Low-Energy Shock Wave Therapy Improves Wound Healing After Vein Harvesting for Coronary Artery Bypass Graft Surgery: A Prospective, Randomized Trial (Dumfarth et al., 2008).	71
2.2.20. Shock Wave Therapy to Improve Wound Healing After Vein Harvesting for CABG (Dumfarth et al., 2008).....	72

2.2.21. Clinical Experience with ESWT in Sub Acute and Chronic Wounds (Mittermayr et al., 2008) .	72
2.2.22. ESWT in Chronic Decubitus Ulceration in Complex Neurological Disability (Larking et al., 2008)	73
2.2.23. Blood Flow Perfusion and Molecular Response After ESWT in Chronic Skin Ulcers (Wang et al., 2008)	74
2.2.24. Non-Focused ESWT & Skin Ulceration in Complex Neurological Disabilities (Andrews et al., 2007)	75
2.2.25. Shockwaves Induce Cellular Response in Diabetic Skin Ulcers (Wang et al., 2007)	75
2.2.26. Extracorporeal Shockwave Therapy for Chronic Skin Lesions (Pusch et al., 2007)	76
2.2.27. Shock Wave Therapy for Acute and Chronic Soft Tissue Wounds: a Feasibility Study (Schaden et al., 2007).....	76
2.2.28. Shock Wave Therapy to Improve Wound Healing After Vein Harvesting for CABG (Vögele-Kadletz et al., 2007)	77
2.2.29. Extracorporeal Shock Wave Therapy (ESWT) in Skin Lesions (Schaden et al., 2006).....	78
2.3. Pathologic Scarring	79
2.3.1. Extracorporeal Shock Wave Therapy for Hypertrophic Scars (Chuangsuwanich et al., 2022).	79
2.3.2. Extracorporeal Shock Wave Treatment: An Emerging Treatment Modality for Retracting Scars of The Hands (Saggini et al., 2015)	80
2.3.3. Regenerative Model with ESWT in Atrophic and Retracting Scars (Saggini et al., 2014).....	80
2.3.4. The Effectiveness of Extracorporeal Shockwave Therapy in the Treatment of Surgical Hand Scars (Saggini et al., 2013).....	81
2.4. Lymphoedema.....	82
2.4.1. Low-Energy Extracorporeal Shockwave Therapy as a Therapeutic Option for Patients with a Secondary Late-Stage Fibro-Lymphedema After Breast Cancer Therapy: A Pilot Study (Joos et al., 2020)	82
3. Urology.....	83
3.1. Peyronie`s Disease.....	83
3.1.1. Low-Intensity Extracorporeal Shockwave Therapy (LI-ESWT) for Peyronie's Disease: a 4 Year Single Center Experience (Chiarelli et al., 2022)	83
3.1.2. Extracorporeal Shockwave Therapy in the Treatment of Peyronie's Disease: Our Initial Experience (Inneo et al., 2021).....	84
3.2. Erectile Dysfunction.....	85
3.2.1. Low Intensity Shockwave Treatment of the Erect Penis: Assessment by Pre-and Post-Grayscale (Goldstein et al., 2024)	85
3.2.2. Low Intensity Shockwave Therapy for Erectile Dysfunction: A Sham-Controlled Randomized Trial (Goldstein et al., 2024)	86
3.2.3. Simulation of Erectile Tissue Shockwave Energy Absorption During Low LiSWT for Erectile Dysfunction (Goldstein et al., 2024).....	86



3.2.4. Variations in Low Intensity Shockwave Treatment Protocols for Erectile Dysfunction: A Review of the Literature and Guide to Offering Treatment (Hayon et al., 2023).....	87
3.2.5. Three-dimensional shockwave modeling of the efficacy of secondary reflectors in low intensity shockwave therapy to the penis (Janout et al., 2023)	88
3.2.6. Low Intensity Shockwave Therapy (LiSWT) for Improvement of Erectile Function: Prospective Study and Engineering Studies (Goldstein et al., 2023)	89
3.2.7. A Sham-Controlled Randomized Trial of Low Intensity Shockwave Therapy for Erectile Dysfunction (Goldstein et al., 2023).....	92
3.2.8. Interim Analysis of a Sham-Controlled Randomized, Prospective Study Using Low Intensity Shockwave Therapy (LiSWT) for Improvement of Erectile Dysfunction (Goldstein et al., 2022)	93
3.2.9. Novel Low Intensity Shockwave Therapy Sham Delivery Method (Zero Energy) Assessed Objectively by Grayscale and Doppler Ultrasound Results (Goldstein et al., 2022)	94
3.2.10. Post-Finasteride Induced Erectile Dysfunction: Diagnosis by Grayscale / Doppler Ultrasound and Disease Modification Treatment with Erect Penile Extracorporeal Shockwave Therapy (Goldstein et al., 2022).....	95
3.2.11. Interim Analysis of a Sham-Controlled Randomized, Prospective Study Using Low Intensity Shockwave Therapy (LiESWT) for Improvement of Erectile Function (Goldstein et al., 2022).....	96
3.2.12. Retrospective Comparison of Focused Shockwave Therapy and Radial Wave Therapy for Men with Erectile Dysfunction (S. S. Wu et al., 2020)	97
3.2.13. Proposed Mechanisms of Erectile Function Improvement with Low Intensity Shock Wave Therapy: Vascular and Erectile Tissue Health Changes Pre- and Post-Treatment (Yih et al., 2020).....	98
3.2.14. Review of the Current Status of Low Intensity Extracorporeal Shockwave Therapy (Li-ESWT) in Erectile Dysfunction (ED), Peyronie's Disease (PD), and Sexual Rehabilitation After Radical Prostatectomy with Special Focus on Technical Aspects of the DifferentMarketed ESWT Devices Including Personal Experiences in 350 Patients (Porst, 2020)	99
3.2.15. Retrospective Review of Improvement of Erectile Dysfunction after Low-Intensity Shockwave Treatment with Urogold100 (Yih et al., 2020)	100
3.2.16. First Report for Unfocused Li-eswt for Nocturia and Erectile Dysfunction (Sharpe et al., 2019)	101
3.2.17. Case Series of Weekly Low Intensity Shockwave Therapy for Erectile Dysfunction (Shoskes et al., 2017).....	102
3.2.18. Effectiveness of Shock Wave Therapy: Implementation of a Soft Wide Focus Applicator in Patients with Erectile Dysfunction (Saffon et al., 2017).....	103
3.2.19. Penile Low Intensity Shock Wave Therapy for PDE5i Non-Responders Suffering from Vasculogenic Erectile Dysfunction since 2 to 10 Years: A Prospective, Randomized, Placebo-Controlled Study (Vinay et al., 2017)	104
3.3. Chronic Pelvic Pain / Chronic Prostatitis	105
3.3.1. Case Series of Low Intensity Shock Wave Therapy for Men with Chronic Prostatitis / Chronic Pelvic Pain Syndrome (Shoskes & Mooney, 2018).....	105
3.3.2. Efficacy of Extracorporeal Shockwave Therapy (ESWT) for Male Chronic Pelvic Pain Syndrome: a Phase III, Randomized, Double Blind Controlled with Placebo Study (Ramon et al., 2017)	105

3.4.	Premature Ejaculation.....	106
3.4.1.	Novel Use of a Shock Wave Device for Energy Flux Density Threshold Testing of the Distal Ventral Erect Penile Shaft as a Marker of Penile Dysesthesia/Hypersensitivity Associated with Premature Ejaculation (Uloko et al., 2020)	106
3.5.	Penile Augmentation.....	107
3.5.1.	The Concept of Spark Wave Therapy (Sw) Assisted Penile Augmentation (Mirza, 2017).....	107
3.6.	Testicular Function	108
3.6.1.	Pilot Trial, First Report Worldwide for Unfocused SoftWave Therapy (uESWT) for the Treatment of Testicles to Improve Testicular Size and Function (Sharpe et al., 2019)	108
3.7.	Vestibulodynia.....	108
3.7.1.	Chart Review of Low-Intensity Shockwave Therapy with Urogold100™ MTS for Hormonally-Mediated Vestibulodynia (Goldstein et al., 2024)	108
3.7.2.	A Pilot Study of Post-Vestibulectomy Opioid Use following Pre-Operative Vestibular Low Intensity Shockwave Therapy (Goldstein et al., 2024)	109
3.7.3.	Decrease in Opioid Use Post-Vestibulectomy Based on Pre-Operative Low Intensity Vestibular Shockwave Therapy (LiSWT) (Goldstein et al., 2021).....	110
3.7.4.	Retrospective Chart Review of Treatment Outcome Following Low-Intensity Shockwave Therapy for the Treatment of Vestibulodynia with Urogold100 (Yih, 2020)	111
3.8.	Persistent Genital Arousal Disorder / Genito-Pelvic Dysesthesia	112
3.8.1.	Extracorporeal Shockwave Therapy for the Management of Persistent Genital Arousal Disorder/Genito-Pelvic Dysesthesia from Lumbosacral Spine Pathology-Induced Sacral Radiculopathy (Goldstein et al., 2022)	112
3.8.2.	Lumbo-Sacral Low Intensity Shock Wave Therapy for Persistent Genital Arousal Disorder/Genito-Pelvic Dysesthesia Using the UroGold 100 MTS (Yih et al., 2020)	113
3.9.	Lithotripsy - Kidney and Ureter Stone Disease.....	114
3.9.1.	Lithotripter Outcomes in a Community Practice Setting: Comparison of an Electromagnetic and an Electrohydraulic Lithotripter (Bhojani et al., 2015).....	114
4.	Neurology	114
4.1.	Spinal Cord Injury	114
4.1.1.	Shock Wave Treatment Reduces Neuronal Degeneration Upon Spinal Cord Ischemia and Improves Symptoms in a First-in-Man Trial (Holfeld J., ... Tepeköylü C. et al., 2017)	114
4.1.2.	Unfocused SoftWave Therapy for the Treatment of Spine Injury Patients to Evaluate the Technology's Influence on Patient Strength, mobility, Sensitivity, Perspiration, Lung Function, Spasticity, Wound Healing and the Appearance of Scars (Weaver et al., 2015).....	115
4.2.	Limb Loss / Phantom Pain / Sensory Reinnervation	116
4.2.1.	Targeted Sensory Reinnervation (TSR) and Our Experience with Shock Wave Therapy for the Treatment of Microsurgical Nerve Sutures (Gardetto et al., 2022)	116
4.3.	Fibromyalgia	117



4.3.1. Radial Extracorporeal Shockwave Treatment: A New Paradigm on Fibromyalgia (Ramon et al., 2015)	117
4.3.2. Radial Extracorporeal Shockwave Therapy in Fibromyalgia (Ramon et al., 2014)	118
PRECLINICAL STUDIES / BASIC RESEARCH	119
5. Orthopedics	119
5.1. Tendinopathies / Soft Tissue Disorders	119
5.1.1. Shock Waves as Treatment of Mouse Myofascial Trigger Points (Monclús et al., 2023)	119
5.1.2. Improved Biomechanics in Experimental Chronic Rotator Cuff Repair after Shockwaves is not Reflected by Bone Microarchitecture (Feichtinger et al., 2022)	119
5.1.3. Substantial Biomechanical Improvement by Extracorporeal Shockwave Therapy After Surgical Repair of Rodent Chronic Rotator Cuff Tears (Feichtinger et al., 2019)	120
5.1.4. Shock Wave Treatment of Muscle Stem Cells – a New Implementation for Regeneration (Fuchs C., Weihs A., et al., 2017)	121
5.1.5. The Effect of Shock Waves on In Vitro Cartilage Development in Silk Scaffolds (Szwarc D., Fuchs C. et al., 2016)	122
5.1.6. Soft-focused extracorporeal shock waves increase the expression of tendon-specific markers and the release of anti-inflammatory cytokines in an adherent culture model of primary human tendon cells (de Girolamo et al., 2014)	122
5.1.7. Soft Focused Extracorporeal Shockwaves Increase the Expression of Tendon-Specific Markers and the Release of Anti-Inflammatory Cytokines in an Adherent Culture Model of Primary Human Tendon Cells (Vigano et al., 2014)	123
5.2. Bone Healing Disorders	123
5.2.1. Optimization of Screw Fixation in Rat Bone with Extracorporeal Shock Waves (Koolen et al., 2017)	123
5.2.2. Shock Wave Therapy for Osteoinduction (Koolen M., ...van der Jagt O. et al., 2017)	124
5.2.3. Unfocused Extracorporeal Shock Waves Induce Anabolic Effects in Osteoporotic Rats (Van Der Jagt et al., 2013)	124
5.2.4. Unfocused Extracorporeal Shock Waves Induce Anabolic Effects in Rat Bone (Van Der Jagt et al., 2011)	125
5.2.5. Unfocused Extracorporeal Shock Wave Therapy as Potential Treatment for Osteoporosis (van der Jagt et al., 2009)	126
5.2.6. Unfocused Extracorporeal Shockwave Therapy Diminishes Bone Loss in Rats (Olav P van der Jagt et al., 2008)	126
5.3. Orthodontics	127
5.3.1. The Effect of Shock Waves on Mineralization and Regeneration of Distraction Zone in Osteoporotic Rabbits (Özkan et al., 2023)	127
5.3.2. Orthodontic Force and Extracorporeal Shock Wave Therapy: Assessment of Orthodontic Tooth Movement and Bone Morphometry in a Rat Model (Hazan-Molina et al., 2022)	128
5.3.3. Dose-Related Effects of Extracorporeal Shock Waves on Orthodontic Tooth Movement in Rabbits (Demir & Arici, 2021)	128

5.3.4. Extracorporeal Shock-Wave Therapy or Low-Level Laser Therapy: Which is More Effective in Bone Healing in Bisphosphonate Treatment? (Göl et al., 2020)	129
5.3.5. Effect of Electrohydraulic Extracorporeal Shockwave Therapy on the Repair of Bone Defects Grafted with Particulate Allografts. (Özkan et al., 2019)	129
5.3.6. The Assessment of New Bone Formation Induced by Unfocused Extracorporeal Shock Wave Therapy Applied on Pre-Surgical Phase of Distraction Osteogenesis. (Senel et al., 2019)	130
5.3.7. Effects of Timing of Extracorporeal Shock Wave Therapy on Mandibular Distraction Osteogenesis: An Experimental Study in a Rat Model (Ginini et al., 2019)	130
5.3.8. The Effect of Unfocused Extracorporeal Shock Wave Therapy on Bone Defect Healing in Diabetics (Özkan et al., 2018).....	131
5.3.9. The Effect of Different Doses of Extracorporeal Shock Waves on Experimental Model Mandibular Distraction (Bereket et al., 2018).....	131
5.3.10. Extracorporeal Shockwave Treatment Impedes Tooth Movement in Rats (Atsawasuwan et al., 2018) 132	
5.3.11. Is it Possible to Change the Duration of Consolidation Period in the Distraction Osteogenesis with the Repetition of Extracorporeal Shock Waves? (Onger et al., 2017)	133
5.3.12. Effects of Shock Waves on Expression of IL-6, IL-8, MCP-1, and TNF- α Expression by Human Periodontal Ligament Fibroblasts: An In Vitro Study (Cai et al., 2016)	133
5.3.13. The Influence of Shockwave Therapy on Orthodontic Tooth Movement Induced in the Rat (Hazan-Molina et al., 2016)	134
5.3.14. Periodontal Cytokines Profile under Orthodontic Force and Extracorporeal Shock Wave Stimuli in a Rat Model (Hazan-Molina et al., 2015).....	134
5.3.15. Assessment of IL-1 β and VEGF Concentration in a Rat Model During Orthodontic Tooth Movement and Extracorporeal Shock Wave Therapy (Hazan-Molina et al., 2012).....	135
5.3.16. Effects of Low-Energy Shock Waves on Oral Bacteria (Novak et al., 2008)	135
5.3.17. Extracorporeal Shock Wave Therapy Induces Alveolar Bone Regeneration (Sathishkumar et al., 2008) 136	
5.3.18. Effects of Unfocused Extracorporeal Shock Waves on Gram-Positive and Gram-Negative Bacteria (Novak et al., 2007)	136
5.3.19. Extracorporeal Shock Wave Therapy Induces Alveolar Bone Regeneration in Experimental Peridontitis (Sathishkumar et al., 2007)	137
6. Dermatology	137
6.1. Acute Wounds and Burns.....	137
6.1.1. Effects of Extracorporeal Shock Waves on Microcirculation and Angiogenesis in the in vivo Wound Model of the Diver Box (Sorg et al., 2021)	137
6.1.2. Mechanical Stimulation of Fibroblasts by Extracorporeal Shock Waves: Modulation of Cell Activation and Proliferation Through a Transient Proinflammatory Milieu (Basoli et al., 2020)	138
6.1.3. Extracorporeal Shockwave Therapy as Supplemental Therapy for Closure of Large Full Thickness Defects—Rat Full-Thickness Skin Graft Model (Antonic et al., 2018).....	139



6.1.4. In Vitro Effects of Extracorporeal Shockwave Therapy (ESWT) on Proliferation and Metabolic Activity of Adult Human Keratinocytes (Ottomann MD & Antonic PhD, 2015)	139
6.1.5. Extracorporeal Shockwaves (ESW) Promote Proliferation and Differentiation of Keratinocytes In Vitro-Histology and Immunohistochemistry (Antonic V, Hartmann B, Münch S, Belfekroun C, Niedobitek G, 2015)	139
6.1.6. Shock Wave Treatment Enhances Cell Proliferation and Improves Wound Healing by ATP Release-Coupled Extracellular Signal-Regulated Kinase (ERK) Activation (Weihs et al., 2014)	140
6.1.7. Extracellular ATP Enhances Proliferation After In Vitro Shockwave Treatment by ERK Dependent Pathways (Weihs et al., 2013)	141
6.1.8. Effect of Unfocused Extracorporeal Shock Wave Therapy on Growth Factor Gene Expression in Wounds and Intact Skin of Horses (Link et al., 2013).....	141
6.1.9. Extracorporeal Shock Wave Therapy (ESWT) Minimizes Ischemic Tissue Necrosis Irrespective of Application Time and Promotes Tissue Revascularization by Stimulating Angiogenesis (Mittermayr et al., 2011).....	142
6.1.10. Effects of Unfocused Extracorporeal Shock Wave Therapy on Healing of Wounds of the Distal Portion of the Forelimb in Horses (Silveira A, Koenig JB, Arroyo LG, Trout D, Moens NM, LaMarre J, 2010)	142
6.1.11. Extracorporeal Shock Wave Therapy Suppresses the Early Proinflammatory Immune Response to a Severe Cutaneous Burn Injury (Davis et al., 2009).....	143
6.1.12. Angiogenic Response to Extracorporeal Shock Wave Treatment in Murine Skin Isografts (Stojadinovic et al., 2008).....	143
6.1.13. A Study of the Biological Factors and Wound Healing of a Skin Flap Model (Vasconez et al., 2007)	144
6.2. Chronic Wounds and Ulcers	145
6.2.1. Compare the Effectiveness of Extracorporeal Shockwave and Hyperbaric Oxygen Therapy on Enhancing Wound Healing in a Streptozotocin-Induced Diabetic Rodent Model (R. Chen et al., 2023)	145
6.2.2. The Potential Effect of Shock Wave Treatment on Cellular Senescence (D. Swarc-Hofbauer et al., 2022).....	146
6.2.3. Shockwaves Increase In Vitro Resilience of Rhizopus Oryzae Biofilm Under Amphotericin B Treatment (Slezak, Anderson, et al., 2022)	147
6.2.4. The Acceleration of Diabetic Wound Healing by Low-Intensity Extracorporeal Shockwave Involves in the GSK-3 β Pathway (R.-F. Chen et al., 2020)	147
6.2.5. Proteomic Analysis of Peri-Wounding Tissue Expressions in Extracorporeal Shock Wave Enhanced Diabetic Wound Healing in a Streptozotocin-Induced Diabetes Model (R. F. Chen et al., 2020)	148
6.2.6. Modulation of VEGF and MAPK-Related Pathway Involved in Extracorporeal Shockwave Therapy Accelerate Diabetic Wound Healing: Modulation of VEGF Pathway Involved in ESWT Accelerate Wound Healing.....	148
6.2.7. Serum Proteomic Analysis of Extracorporeal Shock Wave Therapy-Enhanced Diabetic Wound Healing in a Streptozotocin-Induced Diabetes Model (Yang et al., 2014)	149

6.2.8. Comparative Analysis of Angiogenic Gene Expression in Normal and Impaired Wound Healing in Diabetic Mice: Effects of Extracorporeal Shock Wave Therapy (Zins et al., 2010).....	149
6.2.9. Extracorporeal Shock-Wave Therapy Enhanced Wound Healing via Increasing Topical Blood Perfusion and Tissue Regeneration in a Rat Model of STZ-Induced Diabetes (Kuo et al., 2009).....	150
6.2.10. How Many Shock Waves are Enough? Dose-Response Relationship in Ischemic Challenged Tissue (Mittermayr et al., 2008).....	150
6.2.11. Shockwave Therapy is Protective Against Ischemia Induced Tissue Necrosis Irrespective of Application Time (Mittermayr et al., 2007).....	151
6.3. Pathologic Scarring.....	152
6.3.1. A Development of Biological Reparative Model in Human Tendon Derived from Fibroblasts Healing Process with unfocused ESWT (Saggini et al., 2014).....	152
7. Urology.....	152
7.1. Peyronie`s Disease.....	152
7.1.1. Low-intensity Extracorporeal Shockwave Therapy as an Adjunct to Xiaflex® in the Treatment of Peyronie's Disease (Soubra et al., 2022).....	152
7.1.2. Evaluating Different Low-intensity Extracorporeal Shockwave Therapy Intensities in the Treatment of Peyronie's Disease in a Rat Model (Kim et al., 2022).....	153
7.2. Erectile Dysfunction.....	154
7.2.1. Low-energy Shock Wave Therapy Ameliorates Erectile Dysfunction in a Pelvic Neurovascular Injuries Rat Model (Li et al., 2016)	154
7.2.2. Effects of Low-Energy Shockwave Therapy on the Erectile Function and Tissue of a Diabetic Rat Model (Qiu et al., 2013)	155
7.3. Chronic Pelvic Pain / Chronic Prostatitis	156
7.4. Stress Urinary Incontinence	156
7.4.1. Delayed Treatment with Low-intensity Extracorporeal Shock Wave Therapy in an Irreversible Rat Model of Stress Urinary Incontinence (Zhang et al., 2020)	156
7.4.2. Treatment of Stress Urinary Incontinence with Low-Intensity Extracorporeal Shock Wave Therapy in a Vaginal Balloon Dilation Induced Rat Model (A. K. Wu et al., 2018).....	156
7.5. Lithotripsy - Kidney and Ureter Stone Disease.....	157
7.5.1. Evaluation of the LithoGold LG-380 Lithotripter: In Vitro Acoustic Characterization and Assessment of Renal Injury in the Pig Model (Pishchalnikov et al., 2013).....	157
8. Neurology.....	158
8.1. Spinal Cord Injury	158
8.1.1. Neuronal Pre- and Postconditioning via Toll-like Receptor 3 Agonist or Extracorporeal Shock Wave Therapy as New Treatment Strategies for Spinal Cord Ischemia: An In Vitro Study (Lobenwein et al., 2022).....	158
8.1.2. Shock Waves Induce an Evolutionary Conserved Mechanism of Spinal Cord Regeneration (Gollmann-Tepeköylü et al., 2021).....	158
8.1.3. Shock Waves Promote Spinal Cord Repair via TLR3 (Gollmann-Tepeköylü et al., 2020)	159



8.1.4. Shock Waves Enhance Neuronal Survival and Improve Motor Function After Traumatic Spinal Cord Injury (Tepeköylü C., Nägele F., ...Holfeld J. et al., 2017)	159
8.1.5. ESWT In Experimental Traumatic Spinal Cord (SCI) Injury (Posa et al., 2016)	160
8.1.6. Shock Wave Therapy Enhances Neuronal Sprouting and Improves Neuronal Survival (An A., Nägele F, ...Tepeköylü C. et al., 2016)	161
8.1.7. Shock Wave Treatment Reduces Neuronal Degeneration Upon Spinal Cord Ischemia via Toll-like Receptor 3 Dependent Mechanism (Lobenwein D, Tepeköylü C., ... Holfeld J. et al., 2016)	161
8.1.8. Shock Wave Treatment Protects from Neuronal Degeneration via a Toll-Like Receptor 3 Dependent Mechanism: Implications of a First-Ever Causal Treatment for Ischemic Spinal Cord Injury (Lobenwein et al., 2015).....	162
8.2. Nerve Grafting / Peripheral Nerve Regeneration.....	163
8.2.1. Effects of ESWT on Neuroregeneration after Median Nerve Reconstruction with Autologous Nerve Grafts or Three Different Conduits in the Rat (Heinzel et al., 2021)	163
8.2.2. Motor and Sensory Schwann Cell Phenotype Commitment is Diminished by Extracorporeal Shockwave Treatment In Vitro (Hercher et al., 2020).....	163
8.2.3. Efficacy of Extracorporeal Shockwaves Therapy on Peripheral Nerve Regeneration (Sağır et al., 2019)	164
8.2.4. ESWT Affects Schwann Cell Phenotype In Vitro and In Vivo Thereby Accelerating Nerve Regeneration (Hercher et al., 2018).....	164
8.2.5. Extracorporeal Shockwave Treatment: A Novel Tool to Improve Schwann Cell Isolation and Culture (Schuh et al., 2016).....	165
8.2.6. Regenerating Peripheral Nerves – Shockwave Treatment as A Supportive Mean (Hercher et al., 2016)	165
8.2.7. ESWT Affects Schwann Cell Phenotype In Vitro and In Vivo thereby Accelerating Nerve Regeneration (Hercher D., Schuh C., et al., 2016).....	166
8.2.8. ESWT Affects Schwann Cell Phenotype in Vitro and in Vivo Thereby Accelerating Nerve Regeneration (Hercher et al., 2015).....	167
8.2.9. The Activating Effect of ESWT on Schwann Cells In Vitro and In Vivo (Hercher D., Schuh C., 2014)	167
8.2.10. Improved Rate of Peripheral Nerve Regeneration Induced by Extracorporeal Shock Wave Treatment in the Rat (Hausner et al., 2012)	168
8.2.11. Shock wave Therapy in Peripheral Nerve Repair: Investigation in a Rat Sciatic Nerve Repair Model (Halat et al., 2008).....	169
8.2.12. Shock Wave Therapy in Peripheral Nerve Repair (Halat et al., 2007)	169
8.3. Transcranial ESWT	170
8.3.1. A Comparative Feasibility Study for Transcranial Extracorporeal Shock Wave Therapy (Slezak, Flatscher, et al., 2022)	170
9. (Stem / Progenitor) Cell Activation	171
9.1. Advantages of Preconditioning of ASCS by Shockwave Therapy (Freitag et al., 2021)	171

9.2. Improvement of Adipose Tissue-Derived Cells by Low-Energy Extracorporeal Shock Wave Therapy (Priglinger et al., 2017).....	171
9.3. Shock Wave Treatment for In Vitro Engineering Applications (Anna M. Weihs et al., 2016)	172
9.4. In Vitro Extracorporeal Shock Wave Treatment Enhances Stemness and Preserves Multipotency of Rat and Human Adipose-Derived Stem Cells (Schuh et al., 2014)	172
9.5. Adipose Derived Stem Cells: In Vitro Treatment with Extracorporeal Shockwaves Enhances Stemness and Preserves Multipotency (Schuh et al., 2013)	173
9.6. Shockwave Therapy on Human Fat-Derived Stem Cells (Morton et al., 2008)	174
10. (Lymph-) Angiogenesis, Inflammatory Control and Cardiology	174
10.1. Hippo/YAP/TAZ Mediates Angiogenic Response and Exosome Release Upon SWT (Nägele et al., 2021)	174
10.2. miR-19a-3p Containing Exosomes Improve Function of Ischemic Myocardium Upon Shock Wave Therapy (Pölzl et al., 2021)	175
10.3. Therapeutic Transdifferentiation of Fibroblasts to Functional Endothelial Cells Upon Shock Wave Therapy (Graber et al., 2021)	176
10.4. A Standardized Murine Model of Extracorporeal Shockwave Therapy Induced Soft Tissue Regeneration (Hirsch et al., 2021)	176
10.5. Defining a Therapeutic Range for Regeneration of Ischemic Myocardium via Shock Waves (Pölzl L et al., 2021)	177
10.6. Exosome Isolation after in vitro Shock Wave Therapy (Pölzl et al., 2020)	177
10.7. miR-19a-3p Containing Exosomes Improve Function of Ischemic Myocardium Upon Shock Wave Therapy (Gollmann-Tepeköylü et al., 2019)	178
10.8. Shock Wave Therapy Improves Cardiac Function in a Model of Chronic Ischemic Heart Failure: Evidence for a Mechanism Involving VEGF Signaling and the Extracellular Matrix (Gollmann-Tepeköylü et al., 2018)	178
10.9. Shock Wave Treatment After Hindlimb Ischaemia Results in Increased Perfusion and M2 Macrophage Presence (Tepeköylü et al., 2018)	179
10.10. Shockwaves Prevent from Heart Failure After Acute Myocardial Ischaemia via RNA/Protein Complexes (Tepeköylü et al., 2017)	179
10.11. Shock Waves Induce Angiogenesis via Exosome Release (Graber et al., 2017)	180
10.12. Elucidating the Molecular Mechanisms Underlying Cardiac Shock Wave Therapy (Szwarc D., Fuchs C. et al., 2017)	180
10.13. Shock Waves Induce Angiogenesis via Exosome Release (Tepeköylü C., ... Holfeld J. et al., 2016)	181
10.14. Toll-Like Receptor 3 Signalling Mediates Angiogenic Response Upon Shock Wave Treatment of Ischaemic Muscle (Holfeld, Tepeköylü, et al., 2016)	182
10.15. Antimicrobial Peptide LL37/RNA Complexes Stimulate Toll-Like Receptor 3 Upon Shock Wave Therapy (Graber et al., 2016)	182
10.16. Epicardial Shock-Wave Therapy Improves Ventricular Function in a Porcine Model of Ischaemic Heart Disease (Holfeld, Zimpfer, et al., 2016)	183



10.17. The Beneficial Effects of In Vitro Shock Wave Treatment on Cardiomyogenesis are Energy Dependent (Fuchs C., Weihs A. M. et al., 2016).....	184
10.18. Low-Energy Shock Waves Treatment Induces Angiogenesis in Ischemic Muscle by Stimulation of Toll-Like Receptor 3 Signalling (Holfeld J., Tepeköylü C et al., 2016).....	184
10.19. Shock Wave Therapy Causes Increased Macrophage Recruitment and Enhances M2 Polarization (Nägele F., Graber M., ...Tepeköylü C., Holfeld J., 2016).....	185
10.20. Effect of Shock Waves on Macrophages: A Possible Role in Tissue Regeneration and Remodeling (Sukubo et al., 2015)	186
10.21. Shockwave Treatment Promotes the Expression of Alox15 in Pro-Resolving Macrophages (Sukubo et al., 2014) (Sukubo et al., 2015)	186
10.22. Alteration of Inflammatory Response by Shock Wave Therapy Leads to Reduced Calcification of Decellularized Aortic Xenografts in Mice (Tepeköylü et al., 2015)	187
10.23. Low Energy Shock Wave Therapy Induces Angiogenesis in Acute Hind-Limb Ischemia via VEGF Receptor 2 Phosphorylation (Holfeld, Tepekoylu, et al., 2014)	188
10.24. Shockwave Therapy Differentially Stimulates Endothelial Cells: Implications on the Control of Inflammation via Toll-Like Receptor 3 (Holfeld, Tepeköylü, Kozaryn, Urbschat, et al., 2014).....	188
10.25. Molecular and Cellular Effects of In Vitro Shockwave Treatment on Lymphatic Endothelial Cells (Rohringer et al., 2014).....	189
10.26. Shockwaves Induce Postnatal Vasculogenesis in infarcted Myocardium by Recruitment of Bone Marrow Derived Endothelial Progenitors (Holfeld et al., 2014)	189
10.27. In Vitro Shockwave Treatment Influences Lymphatic Endothelial Cells Marker Expression and Proliferation (Riedl et al., 2014)	190
10.28. In Vitro Shockwave Treatment Influences Lymphatic Endothelial Cells Marker Expression and Proliferation (Riedl et al., 2013)	191
10.29. Shock Wave Treatment Induces Angiogenesis and Mobilizes Endogenous CD31/CD34-Positive Endothelial Cells in a Hindlimb Ischemia Model: Implications for Angiogenesis and Vasculogenesis (Tepeköylü et al., 2013).....	191
10.30. Early Angiogenic Response to Shock Waves in a Three-Dimensional Model of Human Microvascular Endothelial Cell Culture (HMEC-1) (Sansone et al., 2012).....	192
10.31. New Insights into Morphology of Cardiac Tissue Regeneration after Direct Epicardial Shock Wave Treatment (Holfeld et al., 2011).....	192
10.32. Changes in Connexine Expression of Cardiomyocytes after In Vitro Shock Wave Treatment (Holfeld et al., 2010).....	193
10.33. Recruitment of Endothelial Progenitor Cells after Direct Epicardial Shock Wave Treatment of Ischemic Heart Failure in Rats (Holfeld et al., 2010)	194
10.34. Direct Epicardial Shock Wave Therapy Improves Ventricular Function and Induces Angiogenesis in Ischemic Heart Failure (Zimpfer et al., 2009)	194
10.35. Shock Wave Therapy as an Alternative to Cardiac Cell Therapy – An In-Vitro Examination (Holfeld et al., 2009).....	195
10.36. Direct Epicardial Shock Wave Therapy in a Porcine Model of Myocardial infarction – Pre-clinical Safety and Feasibility Aspects (Holfeld et al., 2009)	196

10.37. The Importance of a Standardized Model for Shock Wave In-Vitro Trials – a Proposal Plus Preliminary Results of Cardiac Cells (Holfeld et al., 2008)	196
10.38. Epicardial Shock Wave Therapy Induces Neoangiogenesis and Improves Left Ventricular Function After Myocardial Infarction in Pigs In Vivo (Holfeld et al., 2008).....	197
10.39. Direct Epicardial Shock Wave Therapy Improves Left Ventricular Function in an Experimental Model of Ischemic Heart Failure (Zimpfer et al., 2008)	197
10.40. Effects of Unfocused Shock Waves Stimulation on Human Microvascular Endothelial Cell Line HMEC-1 (d'Agostino et al., 2007).....	198
11. Physics / In Vitro Engineering	199
11.1. Physical Considerations for In Vitro ESWT Research Design	199
11.2. Variable Sound Fields of Electro-Hydraulic Extracorporeal Shockwave Applicator (Slezak et al., 2019)	199
11.3. Shock Wave Treatment for In Vitro Engineering Applications (Weihs et al., 2016).....	200
11.4. Shock Wave Application to Cell Cultures (Holfeld, Tepeköylü, Kozaryn, Mathes, et al., 2014)	200
11.5. Accumulated Total Energy Flux Density an Indicator to Compare Electrohydraulic and Piezoelectric Device? (Neumann and Duchtstein, 2012)	200
12. Bibliography	203



CLINICAL STUDIES

1. Orthopedics

1.1. Tendinopathies / Soft Tissue Disorders

1.1.1. *Combination of ESWT and Manual Medicine in the Treatment of Myofascial Pain and Trigger Points- Why Teamwork Will Surpass (Thiele et al., 2023)*

MVZ Chimanos, Berlin, Germany.

Introduction

For several years, the treatment of myofascial pain syndromes has been carried out using extracorporeal shock wave therapy. Here, painful points in the muscle, possibly myofascial trigger points, are treated with focused shock wave therapy or radial pressure waves in order to achieve a resolution of the painful muscle hardenings. For this purpose, the excellent work of C. Stecco should be consulted, especially her research on fascia as a pain generator. Established shock wave users such as Dr Hannes Müller-Ehrenberg and Dr Kwangsun Park have shown a reduction of stiffness and increased mobility of the fascia in the treated area and therefor gained success in pain relief. The hardening of the muscle with the resulting painful points in the muscle is followed in the Munich-classification according to Müller-Wohlfahrt in stage 2a and 2b. Here, in the neurophysiological representation of the MWE, School of Manual Medicine, a segmental protective reflex is found as the basis for nociceptively controlled muscle hardening. This increase in muscle-tone remains or is regularly restored as long as the triggering reflex pattern persists. The trigger here is a disturbed joint play in the area of the peripheral or vertebral joints. The basis of manual medicine is the restoration of joint play to lower the excitation level in the wide dynamic range neuron in the posterior horn of the spinal cord.

Discussion

A touching medicine can reduce the nociceptive influences under excitation of the proprioceptors and thus achieve a tonus reduction. Here the Nobel laureates of 2021, David Julius and Ardem Patapoutian, showed the necessary basis with the description of the receptors for temperature and touch. It now appears that under the combination of manual medicine with recovery of joint play and interruption of the protective reflex pattern with local myofascial treatment of local trigger points and muscle hardening in the painful area, a useful combination can be found for the treatment of myofascial pain syndromes.

Technology: Combination of Manual Medicine and Radial Pressure Waves (EMS), as well as Focused Shockwave (MTS).

COI: No conflict of interest’.

25th ISMST Congress Daegu, Korea, 2023.

Study Performance: **OW100**

1.1.2. Focal Extracorporeal Shockwave Therapy (ESWT) for Ankle Impingement in Athletes (Ngai et al., 2023)

Aspetar Orthopaedic and Sports Medicine Hospital, Doha, Qatar.

Introduction

Footballer's ankle or ankle impingement is defined as a chronic ankle pain with painful restriction of dorsiflexion (anterior), or plantarflexion (posterior) caused by compression of bony or soft tissue, often due to recurrent ankle sprain, chronic ankle instability or repetitive microtrauma during sports or after ankle surgery (Dhooghe et al, 2022; Lavery et al, 2016; Ross et al, 2016; Tol et al, 2006). This condition is diagnosed clinically with confirmation by imaging (X-ray and MRI of the ankle), with painful ankle dorsiflexion or plantarflexion, tender areas of impingement, osseous lesions, hypertrophied synovium, bone oedema, and cartilage lesions (Russo et al, 2013; Berman et al, 2017). This condition affects the competitive participation of the athlete during the season if not treated appropriately (Dhooghe et al, 2022). Conservative treatment (e.g., rest, bracing, orthoses, physiotherapy, and injection therapy) is usually attempted prior to attempting surgical intervention (Lavery et al, 2016; Ross et al, 2016). Unfortunately, one-third of footballers with posterior impingement fail to respond to conservative treatment (Kudas et al, 2016). Recently, arthroscopic surgery has been suggested to be more effective than open surgery in treating this condition (Ribbans et al, 2015; Ross et al, 2016).

High energy ESWT has been shown to be useful to remove calcifications in rotator cuff tendons and improving pain relief and function in osteoarthritic knee joints has not been demonstrated previously (Verstraelen et al 2014; Wang et al, 2017; Hsieh et al, 2020). It has also been previously used to reduce pain and improve function in subacromial impingement (Testa et al 2020). In Aspetar, athletes with ankle impingement have been treated with focal ESWT for both bony and soft tissue impingement. We hypothesize that focal ESWT would have a beneficial effect in reducing pain and expediting return to play in ankle impingement.

Methods

A retrospective analysis patients diagnosed with anterior or posterior ankle impingement treated with focal ESWT was done from 2015 to 2022. Inclusion criteria were patients who did not respond to physiotherapy or injection therapy (Corticosteroid or hyaluronic acid or platelet rich plasma injection) or have residual pain and restricted ankle movement after ankle arthroscopic or open surgery. Meanwhile, patients with recent treatment with PRP injection or corticosteroid injection or double anti-coagulation were excluded. Each athlete was treated with up to four treatments (once fortnightly) of focal ESWT (Orthogold 100). Energy flux density (EFD) used was 0.10 -0.27mJ/mm², 1000-1400 pulses (depending on the size of lesion (s)). Once the patients were able to return to play (RTP) (or physical activities for non-athletes), and was satisfied with treatment, no further treatment was provided. Patients were allowed to continue with physiotherapy during treatment. No NSAIDS was recommended. For each patient, number of treatments, minimum EFD (Elow), maximum EFD (Ehigh), total energy (TotalE), number of pulses, frequency (Hz) was reported. Pre and post VAS score, patient perceived outcome (5-point likert scale), adverse effects and RTP were routinely collected. Patients who had to resort to PRP injection or Corticosteroid injection or surgical treatment were considered as failure to RTP. Ethics review for the chart review is pending with Aspetar IRB.

Results

In this study, 56 patients (54 male and 2 female, 46 athletes and 10 non-athletes, 38 conservative and 18 postsurgical) required 94 treatments for ankle impingement. The age and BMI were 30 ± 11 years and 25.6 ± 4.0 kg/m² respectively. Most of the athletes belonged to the sport football (32.1%), followed by volleyball (16.1%), basketball (14.3%) handball (8.9%), and others. The duration of symptoms before treatment were 13.1 ± 15.0 months. Average number of treatments given was 1.7 ± 0.89 (ranging from



1 to 4), and it did not differ significantly irrespective of the type of sports, location (anterior or posterior) or previous treatment (conservative or post-surgical). Most of the patients (n=47, 85.5%) only required up to 2 treatments. The treatment parameters are given in Figure 1. Pre and post VAS score was 4.1 ± 2.4 and 1.8 ± 1.7 respectively. From the 44 patients who could be followed-up, only 35 patients RTP (79.5%) with 1.5 ± 1.1 months. A greater proportion of patients from the post-surgical group (n=14; 87.5%) RTP compared to the conservative group (n=21; 75%). From those who failed to RTP in both groups (n=9; 20.5%), three were treated with corticosteroids, one with PRP injection, two with ankle surgery whereas three did not continue treatment. Patients from the post-surgical group also had a quicker RTP compared to the conservative group (1.1 ± 0.9 months vs 1.76 ± 1.1 months, $p=0.008$). There were no adverse events reported.

Figure 1

		Indication											
		Ankle Impingement - anterior						Ankle Impingement - posterior					
		Treatment						Treatment					
		Conservatively N=50			Post-surgical N=20			Conservatively N=18			Post-surgical N=6		
		N	M	SD	N	M	SD	N	M	SD	N	M	SD
ApType	SoftFocused	11			2			0			0		
	NonFocused	6			2			1			0		
	Focused	33			16			17			6		
E low			.15	.04		.17	.04		.15	.03		.19*	.02
E high			.22	.06		.25*	.04		.26	.02		.27	.00
Total E		5483	1621		6510*	1246		5354	727		6380*	982	
Hz			4.2	.8		4.3	.7		3.9	.6		4.8*	.4
Pulses		1188	127		1245	185		1140	164		1133	163	

* $P < 0.05$.

Treatment parameters according to location and previous treatment given

Conclusion

Focal ESWT is an effective and safe non-invasive treatment option for ankle impingement in athletes with a mean of RTP of 1.5 months. However, a prospective study including longer-term observation is needed to determine the durability of treatment.

Technology: Focused Shockwave

Device and Manufacturer: MTS

COI: 'No conflict of interest'.

25th ISMST Congress Daegu, Korea, 2023.

Study Performance: **OW100**

1.1.3.Effect of Focal Extracorporeal Shockwave Therapy on Knee Focal Cartilage Defect in Athletes (Ngai et al., 2023)

Aspetar Orthopaedic and Sports Medicine Hospital, Doha, Qatar.

Introduction

Focal cartilage defects have been reported to be found in 36% of symptomatic knees of athletes (Flanigan et al, 2010). These lesions are often co-related with previous injury to the knee (e.g., Anterior

cruciate ligament rupture, meniscus tear and patella dislocation) or repetitive microtrauma from jumping or pivoting during intense physical activity in sports (Aroen et al, 2004; Widuchowski et al, 2007). Common symptoms e.g., pain, locking, catching, swelling and functional impairment may interfere with the competitive performance of an athlete (Richter et al 2016; Aroen et al, 2004). Evidence from previous studies suggest that conservative treatment of knee FCD (e.g., physiotherapy, hyaluronic acid injection, Platelet rich plasma (PRP injection), and medicinal stem cell injection (MSC)) have not been found to be very effective (Southworth et al, 2019; Sherman et al, 2019). Most of the studies in athletes involve surgical cartilage repair which may require prolonged rehabilitation and conflicting evidence of level of return to play (Hacken et al, 2020; Krych et al, 2017; Zaffagnini et al, 2019). Wang et al suggested that extracorporeal shockwave therapy (ESWT) has a chondroprotective and osteogenic effect on the subchondral bone (Wang et al, 2012). We speculate that focal ESWT would have a beneficial effect on reducing pain and expediting return to play in FCD in athletes.

Methods

A retrospective analysis of treatment of athletes diagnosed with knee FCD (full thickness cartilage lesion) with focal ESWT was done from 2015 to 2022. Inclusion criteria were athletes who did not respond to physiotherapy or injection therapy (Corticosteroid or hyaluronic acid or platelet rich plasma injection) or were not indicated for cartilage surgery. Meanwhile, athletes with recent treatment with PRP injection or corticosteroid injection or double anti-coagulation were excluded. Each athlete was treated with up to three treatments (once fortnightly) of focal ESWT (Orthogold 100). Energy flux density (EFD) used was 0.10 -0.27mJ/mm², 1000 – 1400 pulses (depending on the size of lesion (s)).

Once the athlete was able to return to play, and was satisfied with treatment, no further treatment was provided. Patients were allowed to continue with physiotherapy. No NSAIDS was recommended. For each athlete, number of treatments, minimum EFD (Elow), maximum EFD (Ehigh), total energy (TotalE), number of pulses, frequency (Hz), site of cartilage lesion, size and total number of lesions was reported. Pain and pain change using VAS (1-10), patient perceived outcome (5-point likert scale), Farrar score for change (7-point likert scale), adverse effects and return to play were routinely collected. Ethics review for the chart review is pending with Aspetar IRB.

Results

In this study, 32 athletes (required 69 treatments) were studied. Patients required median of one treatment (range of 1 to 4). The average age and BMI of the athletes was 32.3±7.3 and 26.7±5.2 respectively. The maximum size of cartilage lesion was 1.5 cm (0.9) (mean (SD)). Most of the athletes were football (34.4%), handball (18.8%) or volleyball (18.8%) players. The athletes observed a pain reduction from 4.7 (2) to 1.9 (1.9). There was no correlation with Elow, Ehigh, Total E, and Hz with pain change. However, athletes treated with a higher number of pulses led to a greater reduction of pain between VAS1 and VAS2 ($r=0.668$, $p<0.001$). In their individual treatments, athletes playing basketball, handball and volleyball respectively responded better than athletes playing football, rugby and throwing sports. Athletes who responded with a greater pain reduction required fewer treatments. Athletes with FCD located at the lateral femoral condyle, lateral tibial plateau, trochlear, and medial patella facet had a better response to focal ESWT (≥ -2.9). However, there was no correlation of a poorer response to the total number of lesions and size of lesion. Return to play was only available for 26/32 (72.2% of the athletes). Most of the athletes returned immediately (18 (56.3%)), and 6 athletes (18.7%) returned in 4 weeks or more. No adverse events were reported.

Discussion

Athletes diagnosed with knee FCD during the competition season who failed other conservative treatment have limited options other than surgery. Our study suggests that focal ESWT may provide a suitable option to provide a quick relief and allow return to play within 1 month of treatment. This may be suitable to enable the athlete to return to play and plan for definitive treatment at the end of



season. However, the durability of the treatment is not known as patients were followed not more than 3 months. We were unable to determine if the players played at the previous level of play or whether they had residual symptoms. Return to play was not available for six athletes (27.8%) as they could not be traced.

Conclusion

Focal ESWT is an effective and safe modality to treat knee FCD in athletes and expedite their return to play. However, further studies are required to determine long-term effect of the treatment.

Technology: Focused Shockwave

Device and Manufacturer: MTS

COI: 'No conflict of interest'.

25th ISMST Congress Daegu, Korea, 2023. P-13.

Study Performance: **OW100**

1.1.4. An 8-year Retrospective Study of the Treatment Outcome and Safety of Focal Extracorporeal Shockwave Therapy (A. Ngai et al., 2022)

Aspetar Hospital, Sports Medicine Department, Doha, Qatar.

Aspetar Hospital, Research Department, Doha, Qatar.

Introduction

Focal extracorporeal shockwave therapy (fESWT) has been increasingly used to relieve pain and promote tissue healing in sports and chronic pain syndromes with introduction of the modality for new indications in clinical practice.

Over the past 8 years, fESWT has consistently been shown to be effective on fasciopathy, calcific and non-calcific tendinopathy, healing of small fractures (non-healing and delayed healing) and impingement syndromes (shoulder, knee and ankle). Despite conventional approved indications, there is a need to evaluate the effect of fESWT in other common sports injuries and musculoskeletal pain syndromes. For the past 8 years, fESWT has been used to relieve pain and facilitate rehabilitation in conditions like AC joint osteoarthritis, lateral epicondylopathy with intrasubstance tears, plantar fasciopathy with intrasubstance tears and knee Hoffa fat pad impingement syndromes and focal cartilage lesions in the knee and ankles. The aim of this study is to determine the effect of fESWT on sports related injuries and musculoskeletal pain syndromes amongst athletes and non-athletes.

Material & Method

A retrospective analysis of fESWT treatment at the Aspetar Orthopaedic and Sports Medicine Hospital from 2015 to 2022. An Orthogold 100 device was utilized with 3 separate applicators for various tissue type and indications i.e. OE50 (bone, joint and tendon), OE35 (tendon, fascia), OP155 (tendon, fascia, fat pad, tissue inflammation). Pain and pain change were assessed using VAS (1–10), patient perceived outcome (5-point likert scale) and Farrar score for change (7-point likert scale).

Results

In this study, 910 patients (496 females) had 1793 treatment visits (66 % non-athletes, 34 % athletes). Around 40.0 % of the treatment were for foot, followed by ankle (18.4 %), knee (14.6 %) and shoulder (11.6 %). 88.6 % needed only one or two treatments. The tissue types treated were fascia (38.1 %), tendon (36.8 %), joint (16.1 %), bone (10.9 %) and others (9.2 %). Immediately post-treatment, most patients (89.9 %) reported minimum, much improved or very much improved, whereas 10.2 % were unchanged or worse. The average pre- and post-treatment VAS was 5.05 ± 2.2 and 2.432 ± 2.1 respectively with an average VAS reduction of 2.6 ± 1.7 , $p < 0.0001$. There were 7 incidences of erythema, 5 temporary increased pain, two swelling and one bruising.

Discussion

fESWT is a useful alternative treatment for sports injuries and musculoskeletal pain syndromes and has been found to be useful help expedite return to sports in athletes and non-athletes. The treatment provides good short-term effect and is safe even in newer indications. However, more studies are needed to determine the long-term effect of fESWT in these conditions.

24rd World Congress of the ISMST 2022 in Prague, Czech Republic, oral presentation ISMST22-0081.

Study Performance: **orthogold100**

1.1.5. ESWT in Pubic Osteitis in Football Players (J. R. Aranzabal et al., 2022)

Policlinica Gipuzko, Shock Wave Medical Treatments, San Sebastian, Spain.

Pubic Osteitis or Osteopathy of the pubis is a serious injury that can happen to any soccer player, and even more so to professional players, during their sporting career. It is a very disabling injury, which prevents the athlete from playing his sport, with all that this implies, especially at the professional level. Its treatment by conventional means can be prolonged for a long time, and in many occasions the lack of response leads to surgery, and to late and uncertain recoveries. For more than 20 years the treatment with Shock Waves in this pathology has been controversial.

The use of different devices and different technologies can give uncertain results. For the last 3 years, the speaker, using Focal Shock Waves from an Electrohydraulic generator, has achieved good and reproducible results: Medical treatment with Shock Waves brings that unblocking factor to these processes, with an early analgesic response that, together with Exercises and Physiotherapy treatment, makes a decisive progress in the recovery. The speaker explains his treatment method and his experience, in coordination with the Medical Services of a Spanish League Division of Honor Football Club.

24rd World Congress of the ISMST 2022 in Prague, Czech Republic, oral presentation ISMST22-0084.

Study Performance: **orthogold100**

1.1.6. Shock Wave Treatment in Patients with Unilateral Spasticity of the Upper Limb After Ischemic or Hemorrhagic Stroke (Holfeld et al., 2021)

*Department of Neurology, Hochzirl Hospital, Austria
Medical University of Innsbruck, Austria.*

Introduction

Spasticity is a common complication in patients with stroke. Patients suffer from exaggeration of stretch reflexes with uncontrolled, repetitive, involuntary muscle contractions and enhanced reflexes. It is associated with reduced quality of life, increased pain and joint contractures. Current treatment alternatives exhibit serious side effects with limited efficacy. Therefore, there is a strong need for an effective spasticity treatment. In this study, we aimed to test the efficacy of SWT for the treatment of post-stroke spasticity (PSS).

Material & Method

In this prospective, randomized, single-center trial 10 patients with unilateral upper limb PSS received. SWT (n=5) or standard therapy (n=5). Patients in the SWT group received four shock wave treatments within two weeks. Prior to treatment, degree of PSS was assessed by measurement of passive stretch, volitional movement and active/passive function. For this purpose, the modified Ashworth scale (MAS), the range of motion (ROM) test, the box and block test, a robotic resistance test and a full



neuropathological assessment have been performed in a standardized manner. Moreover, WHO quality of life (WHOQOL) questionnaire was used.

Results

Primary endpoint was the functional improvement of upper limb function at 12 weeks, whereas secondary endpoints included changes in quality of life and acceleration to mobilization/rehabilitation. No side effects of SWT occurred in the treatment group. Patients in the treatment group showed improvement in PSS symptoms manifesting in improved scores in the MAS, ROM, box and block and robotic resistance tests. Moreover, WHOQOL scores were improved upon treatment and mobilization time decreased.

Discussion

In this study we provide evidence for the efficacy of SWT in patients with PSS. SWT could develop a potent treatment option for patients suffering from PSS.

Study Performance: **orthogold180c**

23rd World Congress of the ISMST 2021 in Vienna, Austria, 8. ESWT in Neurological Pathologies.

1.1.7. *Efficacy of Unfocused Medium-Intensity Extracorporeal Shock Wave Therapy (MI-ESWT) for Plantar Fasciitis* (Fansa et al., 2020)

Weill Medical College of Cornell University, New York, NY.

Extracorporeal shock wave therapy (ESWT) is a promising treatment for plantar fasciitis (PF), however treatment results have varied due to inconsistencies among types of shock waves treatment and devices used. This retrospective chart review includes patients who underwent EWST using the OrthoGold 100™ shock wave device (MTS, Konstanz, Germany) for PF between January, 2013 and September, 2018. There were 108 patients (119 heels) identified, with a mean age of 51.7 ± 16.5 (Range 21-83) years. Patients were treated weekly for 3 weeks, with 2000 impulses per session at an energy flux density (EFD) between 0.10 and 0.17 mJ/mm². Mean follow-up duration was 11.5 ± 9.7 (Range 3-51) months. Mean pre-ESWT pain visual assessment scale (VAS) improved from 6.7 ± 1.7 to 2.6 ± 2.7 ($p < 0.001$). The Foot and Ankle Outcome Score (FAOS) subscales: pain, function of daily living, function of sports and recreational activities and quality of life domains improved from 53.7 ± 14.9 to 75.7 ± 16.7 ($p < 0.001$), from 38 ± 15.2 to 71.8 ± 23 ($p < 0.001$), from 55.8 ± 16.4 to 71.4 ± 18 ($p < 0.001$), from 42.4 ± 21.5 to 59.4 ± 20.3 ($p < 0.001$) and from 44.9 ± 16.4 to 69 ± 23.9 ($p < 0.001$), respectively. Eighty-eight patients (81.5%) were satisfied with the procedure at final follow-up. Treatment of plantar fasciitis with unfocused shock waves was well tolerated and led to significant pain reduction, functional improvement and patient satisfaction.

Study Performance: **orthogold100**

1.1.8. *Effect of a Single Administration of Focused Extracorporeal Shock Wave in the Relief of Delayed-Onset Muscle Soreness: Results of a Partially Blinded Randomized Controlled Trial* (Fleckenstein et al., 2017)

Goethe-Universität Frankfurt am Main.

Objective: To examine the effects of a single administration of focused extracorporeal shock wave therapy on eccentric exercise-induced delayed-onset muscle soreness (DOMS).

Design: Three-arm randomized controlled study.

Setting: University research center.

Participants: Participants (N=46; 23 women) had a mean age of 29.0±3.0 years and a mean body mass index of 23.8±2.8kg/m².

Interventions: Participants were randomly allocated to verum- (energy flux density, .06-.09mJ/mm²; pulse ratio per point, 200) or sham-focused extracorporeal shock wave therapy (no energy) at 7 equidistant points along the biceps muscle or no intervention.

Main outcome measures: The primary outcome was the difference in pain intensity. Secondary outcomes included maximum isometric voluntary force (MIVF), pressure pain threshold (PPT), and impairment in daily life.

Results: Despite descriptive clinically meaningful differences, mixed-effects analysis (group × time) of changes to baseline did not reveal significant differences in the reduction of pain intensity between groups ($F_{2,42}=2.5$, $P=.094$). MIVF was not significantly different between groups ($F_{2,43}=1.9$, $P=.159$). PTT ($F_{2,43}=0.2$, $P=.854$) and daily life impairment ($F_{2,42}=1.4$, $P=.248$) were not significantly decreased over time, and there were no differences between groups in the post hoc analysis.

Conclusions: DOMS is a common symptom in people participating in exercise, sports, or recreational physical activities. A single treatment with focused extracorporeal shock wave therapy causes clinically relevant effects in the relief of pain, increase in force, and improvement of pain-associated impairments of daily living. Still, results need to be cautiously interpreted because of the pilot character of this study. Focused extracorporeal shock wave therapy might present an option in the midterm recovery from DOMS (72h) and be an approach to enhance the return to play in athletes.

Study Performance: **dermagold100**

1.1.9. Prospective Cohort Study Examining Short Term Changes in Pain after Application of Extracorporeal Shockwave Therapy (ESWT) in 178 Consecutive Patients (Aston Ngai et al., 2016)

Aspetar Hospital, Doha, Qatar.

Introduction: ESWT has been found to be useful in treating chronic musculoskeletal injuries but there was conflicting evidence regarding its efficacy in some conditions. This prospective outcome study investigates the short-term effect of focal ESWT on reported pain in these patients.

Methods: Between December 2015 and May 2016, 178 patients (136 non-athletes, 42 athletes) with chronic musculoskeletal injuries were treated with an incremental focal ESWT without anaesthesia. The patients' pre and post-treatment pain score, 5-point Likert scale and adverse events were reported.

Results: There were significant reductions in pain in knee (2.9, SD=1.6), foot (2.4, SD=1.7) shoulder (2.4, SD=1.6), elbow (2.2, SD=1.4) and ankle injuries (1.8, SD=1.9) ($p<0.001$). Depending on the tissue type, pain reductions ranged from 1.9 (SD=1.4, $p=0.01$) to 2.9 (SD=1.9, $p<0.001$). 89% of patients required only one or two treatments. Immediately after treatment, 38% reported mild improvement, 49% felt much improvement, and 13% were unchanged or slightly worse. Patient response in different tissues was no different. More males than females (93% compared to 82%, $p<0.05$) reported being much improved. 4 incidences each of Erythema (1.6%) and short-term pain increase (1.6%) were reported.

Discussion: The results suggest that most patients obtain short-term pain reduction in most regions and tissue types with one or two treatment with focal ESWT.

Conclusion: There is good short-term reduction in reported pain after treatment with focal ESWT. Male patients seemed to improve more female patients. Future research should examine the durability of these pain reductions to longer term.



19th ISMST Congress in Kuching Malaysia, Abstract No. 28.

Study Performance: orthogold100

1.1.10. *Influence of Medical Shock Waves on Healthy Muscle Tissue (Vincent et al., 2016)*

Kompass GW Sports Medicine, Victoria, Australia.

Introduction: Competitive sport requires each athlete to be at peak performance at all times. This is often a challenging task to manage, as overuse and fatigue syndromes often impede performance. For over a decade shockwave therapy (SWT) have been utilized successfully to manage sports injuries. 1 Our investigation aimed to determine the effects of SWT on muscle tissue of healthy subjects.

Methods: Four golfers and weightlifters were recruited for this project. Weightlifter baseline (BS) and post-intervention (PI) data was collected from activation patterns of six muscles over five repetitions of a 120kg loaded back-squat. Personal-best (PB) back-squat records of each weightlifter was noted and compared PI. Golfers hit 20 balls with a 7- iron and each swing speed, club-ball interface, and ball distance was measured utilizing FlightScope®. 500 acoustic impulses were administered over selected muscles relevant to each sport over two session conducted at two-week intervals utilizing an electrohydraulic generator (OrthoGold-100). PI data was collected at week 8.

Result: Golf - increases in both swing speed and ball distance was noted in each golfer with the mean average (MA) recorded as being: Swing-speed (BS: 140.21km/h – PI: 147.12km/h), club-ball interface (BS: 1.32m/sec – PI: 1.46m/sec), Ball distance (BS: 143.25m – PI: 167.4m). Weightlifting – sEMG activation patterns recorded the following averages over six different muscles throughout each back-squat (BS: 1588.08üv/back squat – PI: 1322.87üv/back-squat). PB back-squat score avg. (BS: 340kgs – PI: 401kgs).

Discussion: Our observations utilizing sport specific measurements suggests that SWT had a positive influence on muscle output and performance. Although an overall improvement in performance was observed in both sporting disciplines and in each athlete, but of note was the reduced muscle expenditure required to complete a similar task PI, as observed in weightlifting. From what that has been presently 21st Annual Congress 6th – 9th July 2016 Vienna, Austria elucidated of the positive mechanotransductive impact of SWT on human tissue¹. It is plausible to suggest that SWT modulates a favorable biocellular and molecular response in muscle tissue, 1 offering the potential to reduce, even prevent overuse syndromes in sports. This case report has its limitations (e.g. small sample size) however the observations are encouraging and opens new possibilities in sports science and medicine, inviting further investigation and collaboration in this area.

21th Annual Congress in Vienna, Austria.

Study Performance: orthogold100

1.1.11. *Radial Shockwave Therapy and High Frequency Laser Combined Treatment in Elbow Tendinopathies (Leal et al., 2014)*

Fenway Medical; Bosque University; Bogota, Colombia.

Introduction: The treatment of elbow tendinopathies with radial pressure waves (RSWT) has showed good and excellent results in over 75% of the cases in most of the series in the literature. In the past ten years we have used a two-session RSWT protocol with 2000 therapeutic radial shockwaves above 2 bar, preceded by 2000 analgesic shockwaves with high number of repetitions per second, followed by another analgesic 2000 shockwaves. This protocol has allowed us to have 81% success rate in the

treatment of chronic elbow tendinopathies. Our protocol includes a follow up visit two weeks after the final SWT session. If the patient reports a VAS pain scale improvement lower than 50%, we proceed to a third and final session, usually with a higher power focused device. Our group has been working in the past year with High Intensity Laser Therapy (HILT) for acute musculoskeletal painful conditions with excellent results. We hypothesize that the use of HILT may have a significant control of pain if combined with RSWT. In this study we compare the outcome of a combined therapy of RSWT and HILT on the third session of Focused Shockwaves in patients that did not improve pain over 50% in their follow up evaluation.

Methods: We performed a case control study on 21 patients diagnosed for chronic lateral epicondyle elbow tendinopathy, that did not improve pain control over 50% in the VAS scale on the follow up visit two weeks after the second RSWT session. We had 14 female and 7 male subjects with an average age of 35.5 y/o (19-52 y/o). They were divided in two groups of 10 and 11 patients. The two groups were statistically similar. They all signed an informed consent. In all cases we used for the first two sessions a Radial SWT generator (BTL 5000 Power – BTL Industries Czech Rep). All subjects were tested and evaluated by ISMST & ONLAT certified specialists. In the Cases Group (RSWT+HILT) we applied a progressive protocol using 200 shocks on 15 Hz, 200 shocks on 10 Hz and 200 shocks on 5 Hz, plus the application of 2500 laser shots over the elbow epicondyle painful region. We used a HILT unit (BTL Industries Czech Rep). The laser treatment was then repeated every 4 days in four more sessions. In the Control Group (RSWT+FSWT) we used our regular protocol of 1000 focused shockwaves using an electrohydraulic device (MTS Orthogold – OE155 – soft focused applicator - MTS Medical – Konstanz, Germany). We followed up the patients for four months, with a monthly record of VAS pain score, the Roles and Maudsley scale, and a record for any adverse effects. All data was recorded and analyzed using a One-Way ANOVA, and the P value was based in <0.01 . The study was done independently with no financial or material support from the manufacturers of the mentioned devices.

Results: Both the cases group and the control group patients improved pain and function in the four months follow up. The RSWT+HILT treated patients had a 71% VAS pain reduction after 5 months, as compared with a 70% in the RSWT+FSWT control group. The Roles and Maudsley scores showed good and excellent results in 70% of the cases group patients, as compared with 73% in the control group. 9/11 patients improved 25%-50% their pain in the four-month follow up, and 2/11 improved over 50% in the cases group. The control group had similar results, with 7/10 patients that improved 25%- 50% and 3/10 over 50%. All reported data in pain control, functional score and improvement rates were not statistically significant. No patients showed increase in pain or any complications.

Discussion: The use of HILT has proven efficacy and safety in pain control of musculoskeletal lesions, and its regenerative power is still under research. Shockwave medicine has proven to be a great tool in tissue regeneration, neovasculogenesis and healing, but pain control is still a short and long-term issue. This study shows a possible use of the best of both technologies in benefit of our tendinopathy patients. We do have better results in our cases with RSWT that did not require a third session, with a 81% pain control, as compared with the 71% and 70% of the patients included in this study, who were the poor-results individuals who required a third treatment session. In future studies we will compare primary patients using RSWT, FSWT and combined RSWT+HILT.

Conclusion: The use of a combined therapy of radial shockwaves and high intensity laser therapy showed similar results as the use of focused shockwaves in the recurrent pain after a primary shockwave treatment for tennis elbow.

17th ISMST Congress in Milano, Italy. Abstract No. 37.

Study Performance: **orthogold100**



1.1.12. *Extracorporeal Shockwave Therapy in Calcific Tendinosis of the Rotator Cuff: Comparison of radial and Focal Treatment (Edson Serrano, Karim Flores, Jean Carlos Criado, 2014)*

Neomedica Shockwave Unit; Lima, Peru.

Introduction: Calcific tendinosis of the shoulder is often associated with chronic pain and impairment of function. Extracorporeal shockwave therapy (ESWT) is considered to be a treatment option. We compared the effects of two different EST technologies: focal and radial:

Methods: Forty-eight shoulders were followed in 2 groups of twenty-four each. The treatment was weekly consisted of 3 x 2000 focal electrohydraulic shockwave with an energy flux density of 0.14-0.2 mJ/mm² without anesthesia (group A) and 5 x 6000 impulses of radial impulses with progressive protocol (group B). The patients were examined at 4 weeks, 3 and 6 months after treatment. X-rays were performed at each visit.

Results: In six months of following after treatment the Constant Score improved from 52.5 to 78.4 in group A and from 54.2 to 72.6 in group B (p<0.05). The values on the visual analog scale which ranges from 0 (no pain) to 10 (maximal pain) improved from 7.7 to 3.1 (group A) and from 7.4 to 3.3 (group B) before and 5 months after treatment respectively. X-rays showed a complete or subtotal calcific resorption in 56% in group A, and 38% in group B of patients.

Discussion: This is a preliminary study indicates that three sessions of extracorporeal electrohydraulic focal shockwave therapy with energy flux density of 0.14-0.2 mJ/mm² may be as effective as five applications of a radial extracorporeal shockwave therapy with progressive protocol for calcific tendinosis of rotator cuff. Focal technology shortens the treatment time, but the radial treatment is more accessible to people.

Conclusion: Both technologies of ESWT (focal and radial) had successful and comparable result in the treated patients with calcific tendinosis of rotator cuff of the shoulder. No complications seen in six months of following. Subjectively, 84% of group A and 76% of group B judged the treatment to be successful.

17th ISMST Congress in Milano, Italy Abstract No. 38.

Study Performance: orthogold100

1.1.13. *The Significance of Inflammatory Tendon Hypervascularization for the Treatment Results with ESWT: Are the Actual Recommendation Still Valid? (Markus Gleitz 2014)*

Orthopaedic Practice, Luxembourg, Luxembourg.

Introduction: Although ESWT of chronic tendinopathies is judged as efficient and is partly considered as a standard indication according to the ISMST/DIGEST guidelines, results vary according to the indications. Former personal results with Power Doppler examinations in radial epicondylopathia (ISMST 2013) have shown that chronic tendinopathies develop variable amounts of a secondary tendon hypervascularization that is decisive for the pain sensation and for the reliability of good treatment results.

Methods: In a retrospective study of 160 patients with chronic tendinopathies (> 3 months: radial epicondylopathy of the elbow, Achilles tendinopathy, patella tendinopathy, plantar fasciitis), ultrasound examinations including grey-scale changes and Power Doppler were performed (1 examiner, not blinded) before and every 3 months after 3 ESWT sessions, up to 24 months. Power Doppler changes were quantified according to the percentage of surface of neovessels within the tendon insertion area. Treatment results were evaluated using the Visual Analogue Scale (VAS in mm,

0-100) during function. The correlation between pre-treatment ultrasonographic changes and the treatment pain as well as the VAS during function 3 months after ESWT was calculated.

Results: The amount of neovessels in the different tendons and fasciae varied significantly at the beginning of the treatment and it correlated with the treatment pain during ESWT ($r=0.72$, $p<0.05$) and the length of the symptoms after ESWT ($r=0.68$, $p<0.05$). The VAS during function 3 months after ESWT was significantly higher ($r=0.77$, $p<0.05$) in patients with an increased amount of neovessels before ESWT. No correlation was found between the amount of neovascularity and the duration of symptoms before ESWT and the amount of neovascularity and the mean pain VAS before ESWT. The highest neovascularity was found in radial epicondylitis, Achilles and patella tendinopathy, followed by the plantar fasciitis, which has the best clinical results. The amount of neovascularity determined the length of the healing period. The typical 3 months interval showed to be an inappropriate time span, as highly vascularized tissues need 6-12 months to heal, even without surgery.

Discussion: Hypervascularity is considered to be associated with an active inflammatory response and is highly correlated with pain intensity. Neovascularity in Power Doppler seems to be a valid parameter for the estimation of pain during ESWT and for the prediction of treatment results. The classical time span of 3 months after ESWT is not a valid parameter to clinically decide about the final treatment results. The unknown presence of neovessels might be the reason for the heterogeneous study results in the literature, as this parameter has never been considered in the highly ranked studies that are usually taken as a reference.

Conclusion: Pre-treatment tissue conditions of the different tendinopathies vary and determine the time span for treatment results: The classical 3 months are no longer valid. For this reason, ultrasound examinations using grey-scale pictures and Power Doppler should be performed as a routine before and after ESWT.

17th ISMST Congress in Milano, Italy. Abstract No. 8.

Study Performance: **orthogold100**

1.1.14. Results of Shockwave Treatment in Lateral Epicondylitis in Relation to Tendon Changes in Power Doppler (Gleitz, 2013)

Introduction: Although ESW treatment of lateral epicondylitis is judged as a standard indication according to the ISMST/DIGEST guidelines, results vary more than for other standard indications. As ESWT is considered as a regenerative treatment stimulating tissue repair the question arises, whether the pre-treatment tissue conditions might have an influence on the treatment results.

Methods: In a prospective study of 41 patients with chronic unilateral epicondylitis (> 3 months) ultrasound examinations including grey-scale changes and Power Doppler were performed (1 examiner, not blinded) before and 3 months after 3 ESWT sessions, that have been applied at weekly intervals. Power Doppler changes were quantified according to the percentage of surface of neovessels within the common extensor insertion area. Treatment results after 3 months were evaluated using the Visual Analogue Scale (VAS in mm, 0-100) during function. The correlation between pre-treatment ultrasonographic changes and the treatment pain as well as the VAS during function 3 months after ESWT was calculated.

Results: The amount of neovessels correlated with the treatment pain during ESWT ($r=0.68$, $p<0.05$), making the use of significantly lower treatment energies necessary. The VAS during function 3 months after ESWT was significantly higher ($r=0.76$, $p<0.05$) in patients with an increased amount of neovessels before ESWT. No correlation was found between the amount of neovascularity and the duration of symptoms before ESWT and the amount of neovascularity and the mean pain VAS before ESWT.



Discussion: Hypervascularity is considered to be associated with an active inflammatory response and is highly correlated with pain severity. The presence of neovessels and accompanying nerves in areas of tendinopathy are associated with an increased tendon pain. Neovascularity in Power Doppler seems to be a valid parameter for the estimation of pain during ESWT and predictive estimation of treatment results. The classical parameters (duration of symptoms, functional scores) are of minor use for the estimation of treatment results. The unknown presence of neovessels might be the reason for the heterogeneous study results in the literature, as this parameter has never been considered in the highly ranked studies that are usually taken as a reference.

Conclusion: Pre-treatment tissue conditions vary and determine the treatment results. For this reason, ultrasound examinations using grey-scale pictures and Power Doppler should be performed as a routine before ESWT.

16th ISMST Congress in Salzburg, Austria. Abstract No. P19.

Study Performance: **orthogold100**

1.1.15. Comparison of Low Dose and High Dose Shockwave Application in Plantar Fasciitis (Georgi et al., 2012)

Medical University, Graz, Austria, Trauma Hospital, Graz, Austria.

Introduction: When it comes to the treatment of plantar fasciitis there is a wide field of therapeutic approaches. Extracorporeal Shockwave treatment (ESWT) is known to improve pain symptoms, however there are discussions going on about the level of dosage for permanent pain relief. Therefore, we conducted a study to compare the clinical outcome of high dose ESWT under general anesthesia and low dose ESWT without any anesthesia.

Methods: Plantar fasciitis was diagnosed clinically and radiologically in 40 feet (32 patients) of which 22 underwent ESWT without any anesthesia (group 1: 1400 impulses, 0,9 mJ/mm²) and 18 underwent ESWT under general anesthesia (group 2: 2000 impulses, 0,27 mJ/mm²). The patient's condition was examined initially and in follow-up observations.

Results: The feet were assigned into following scale for evaluation: 1=worse, 2=same complaints, 3=improvements, 4=asymptomatic. In the first group in 13 feet the same complaints remained, 7 feet showed improvements of symptoms and 2 were free of any symptoms. Whereas in group 2 improvements could be found in 5 feet and in 13 feet pain was extinguished completely.

Discussion: Most cases the threshold for effective treatment lies beyond the bearable pain level. Hence improvements appear but the complete therapeutic effect may not be reached with low dose ESWT.

Conclusion: The different appearance of improvements in our study on plantar fasciitis can be charged to a higher level of dosage. Therefore, we suggest a use of high dose shockwave treatment, if possible.

15th ISMST Congress in Cartagena, Colombia. Abstract No. P25.

Study Performance: **Orthowave100, Orthowave180**

1.1.16. Shockwave Medicine for Carpal Tunnel Syndrome (Barillas et al., 2012)

Unitron, Valencia, Carabobo, Venezuela.

Introduction: Carpal tunnel syndrome is considered a peripheral neuropathy by compression and swelling of soft tissue structures that exert pressure on the median nerve within the carpal tunnel,

between the carpal bones and the transverse carpal ligament. It is thought that repeated movement causes the synovial membranes to swell therefore increasing the pressure on the nerve without possibility of compression relief in a closed compartment. There are many conservative treatments such as lose control, job change, splints, NSAIDs, steroids, rehabilitation and if there is no improvement surgery is considered. There are several surgical techniques described, both open and endoscopic. Even though the results of surgical procedures are usually positive, in many cases there is a persistence of unexplained symptoms in the postoperative period. In this study we used focal shock waves based on the concept of managing the pathophysiology of the symptoms of CTS: decreasing the content within the continent. We want to present the preliminary results, evaluating global hand function, symptoms and clinical signs, satisfaction degree, ultrasonographic changes and / or behavior modification, in the patients treated at the Unitrond Shockwave center in Valencia in 2009 – 2010.

Methods: We performed a cross-sectional. Retrospective, observational and descriptive study. Five patients with carpal tunnel syndrome were treated. Two were unilateral and three bilateral cases. We had only female subjects. The average age was 50 years. Our inclusion criteria were patients with absolute indication for surgery for carpal tunnel syndrome that stated their will not to have a surgical procedure. We evaluated the outcomes using a Carpal tunnel Syndrome functional score, checking on paresthesia, muscle strength, Phalen sign, Tinel sign, sleep disruption, need to shake hands, ultrasound findings, electromyographic findings, muscle dynamometry, initial and final VAS and patient satisfaction scale. We used a focused shockwave generator (Orthogold 100 – MTS-TRT). We applied shockwaves on the upper and volar limits of the carpal tunnel and transverse carpal ligament. We used an intensity of 0.08 mJ/mm². We applied a total of 200 shockwaves in a single session, without sedation. Assessment and follow-up were done at 21 days, 6 weeks, 3 months and 6 months.

Results: All five patients met the inclusion criteria and signed the informed consent. The patient satisfaction level was of 60% satisfied, 20% dissatisfied and 20% not satisfied. Persistence of paresthesia was present in 80% of the cases. Sleep disturbance was also persistent in 80%. Tinel sign and Phalen signs were negative in all cases. We found a persistent swelling in tendon ultrasound in 60% of the cases. The diameter of the median nerve was measured in the pre ESWT period, finding initial diameters between 8.3 mm to 8.9 mm. After ESWT treatment five nerves showed 6 mm to 6.6 mm diameter, 2 nerves 5 mm and one with 4.2 mm. Dynamometry showed that all patients had good muscle strength. In pain assessment, the initial VAS 40% severe and 60% moderate with no mild scores in average. The final VAS reported no severe cases, 80% moderate and 20% mild.

Discussion: The focused shockwaves treatment for carpal tunnel syndrome used in our five patients showed clinical modifications in pain control as well as positive changes in the Median Nerve size evaluated by ultrasound. Changes could be explained by the already known effects of shock waves in tendinopathy, which would decrease the compression on the median nerve by means of swelling controls and increasing the space into the carpal tunnel.

Conclusion: Although this is a small case series, our results open another door in the treatment of carpal tunnel syndrome. We must establish the precise mechanism of action of shock waves in this proposed theoretical content and contingent groups. We would recommend a case controls study with ultrasound measurements of the diameter tendons, and propose to establish, securely, and that patients can be applied effectively to reduce interventional surgical treatment in carpal tunnel syndrome.

15th ISMST Congress Cartegna, Colombia. Abstract No. 43.

Study Performance: **orthogold100**



1.1.17. *Effects of Extracorporeal Shockwave Therapy on Spasticity in Cerebral Palsy (CP): Our Experience (pilot study) (d'Agostino, et al., 2011)*

ESWT Unit, Orthopedic Rehabilitation Dept., Humanitas Clinical institute, Milan, Italy.

Introduction: Spasticity, an abnormality of the tonic stretch reflex, commonly found in Cerebral Palsy (CP), interferes with the normal growth and functionality of the musculoskeletal system, thus leading to deformities, functional limitations, and disability. The principal aim of treatment is to reduce spasticity and retard secondary musculoskeletal alterations, thus avoiding or delaying the need for surgery. Extracorporeal Shockwave Therapy (ESWT) is widely known to be efficacious in the treatment of tendon and osseous diseases as well as in tissue healing. Moreover, evidence from the Literature suggests that ESWT can reduce muscle spasticity, although the mechanism of action is still under investigation and further evidence may be useful.

Methods: 24 spastic diplegic children (6-10 years old, Gross Motor Function Classification System I-II) were treated with 4 sessions of weekly focalized bilateral ESWT on calf muscles (Orthowave, 2000 pulses, EL 0.03 mJ/mm²). Participants were evaluated before (baseline), after intervention program (T1) and 3 months later (T2). Primary outcome measurements were ankle ROM, calf spasticity by MAS and Tardieu scales, and descriptive walking abilities by quantitative gait analysis. Secondary outcomes were individually defined by Goal Attainment scale (GAS).

Results: Statistically significant improvements were observed in ankle ROM and calf spasticity by MAS; walking abilities by gait analysis didn't show any significant modification in kinetic or kinematic pattern of the ankle. Significant improvement was reported in activity performance measured by GAS.

Discussion: These findings provide further clinical evidence in this new field of application in term of efficacy, safety and a painless treatment approach in CP tone reduction.

Conclusion: These findings also seem to suggest some hypothesis on possible mechanisms of action.

14th ISMST Congress in Kiel, Germany, Abstract No. 54.

Study Performance: **orthowave**

1.1.18. *Efficiency of Shockwave Treatment for Pain Reduction in the Shoulder (Erich Georgi, Thomas Georgi 2010)*

Trauma Hospital of Graz, Austria.

Introduction: From 2006-2009, shockwave therapy was performed in the Trauma Hospital of Graz on patients with pain in the shoulder. Patient complaints were pain when raising the arm higher than 60° and pain during the night with trouble of continuous sleep. The aim of this study was to evaluate the rate of success and to detect any hints for predictable success of this treatment.

Methods: Patients suffering from tendinitis of the rotator cuff tendon (n=42) with or without calcification were treated. 86% patients (n=36) were available for follow up. Shockwaves were applied using an Orthowave 180 shockwave machine. Each patient received 2000-2500 impulses under general anesthesia.

Results: Post treatment evaluation included measurement of ROM and additional assessment of the patient's condition. Therefore, we created four categories ranging from success to impairment. 64% showed complete success with pain relief ranging from immediate to 4 months after treatment. 11% of patients continued to have painful restrictions but nightly pain attacks disappeared. No improvement could be achieved in 25%. These patients ultimately underwent surgery after additional treatment. Impairment of the situation was not observed in any subject.

Discussion: Although we received a high rate of success (75%), we could not find any parameters which can predict the success of the treatment.

Conclusion: In summary, the collected data on this topic explicitly proves that shockwave therapy can substitute surgery. Due to pain relief, the quality of life can be improved.

13th ISMST Congress in Chicago, Abstract No. 5.

Study Performance: **orthowave180C**

1.1.19. Extracorporeal Shock Wave Therapy for Calcifying Tendinitis of the Shoulder (Hsu et al., 2008)

Departments of Orthopaedics and Radiology, China Medical University Hospital, Taichung, Taiwan.

We prospectively studied extracorporeal shock wave therapy (ESWT) for calcific tendinitis of the shoulder in 46 consecutive patients. All patients were randomly divided into 2 groups: treatment and control. The 33 patients in the treatment group received 2 courses of ESWT at the energy density of 0.55 mJ/mm² (1000 impulses). The control group underwent sham treatment with a dummy electrode (13 patients). Evaluation included the Constant score, pain scale, and radiographs. The ESWT results were good to excellent in 87.9% of shoulders (29/33) and fair in 12.1% (4/33), and the control results were fair in 69.2% (9/13) and poor in 30.1% (4/13). Among ESWT patients, calcium deposits were completely eliminated in 7 cases (21.2%), partially eliminated in 11 (36.3%), and unchanged in 15 (45.4%). In contrast, elimination was partial in 2 control patients (15.3%) and unchanged in 11 (84.7%). There was no significant difference between Gärtner type I and type II groups in the Constant score ($P > .05$). ESWT shows promise for pain relief and functional restoration of calcific tendinitis with negligible complications.

Study Performance: **orthowave180c**

1.1.20. Our Experience with Shockwave Therapy (Fernando Dujo Rodriguez, 2008)

Hospital Central Paeso De La Habana, Madrid, Spain.

Introduction: We studied the application of high energy shockwaves as an alternative to other treatments, using shockwaves as complementary treatment when orthopaedic and surgical treatment have failed in traumatology.

Methods: The patients were divided into different groups according to their pathology: (i) bone pathologies and (ii) insertion tendinopathies with or without calcifications. As we are dealing with patients in the labor sector, this implies typical characteristics, especially with regard to being refractory concerning pain.

Results: We achieved bony healing in 99% of patients who had had non-unions for up to two years and 90% in pseudarthrosis of more than two years duration. We achieved 100% improvement in patients with delayed healing fractures and calcifications. ESWT was successful in 60% of patients with insertion tendinopathies.

Discussion: We treated patients in no more than 4 sessions, one every two weeks, when the application was done under anesthesia; and we treated patients with eight sessions, one per week, when the application was done without anesthesia.

Conclusion: For our institution, high energy shockwave therapy is the treatment of choice in delayed healing fractures and pseudarthroses of less than two years duration; ESWT is used in established



pseudarthroses (older than two years) and in patients with calcifications. It also can be used as a first attempt to treat insertion tendinopathies.

11th ISMST Congress in Juan le Pins, France, Abstract No. 37.

Study Performance: **orthogold280**

1.1.21. *Requirements for Research in ESWT Management of Spasticity* (A. M. Larking, K. A. S. Hall, 2008)

Institute of Neuropalliative Rehabilitation Royal Hospital for Neuro-disability West Hill Putney London.

Introduction: Spasticity following brain injury is usually permanent and if unmanaged results in contractures or fixed deformities. There have been suggestions that ESWT can help decrease in muscle tone in spasticity. Because spasticity occurs in a wide range of muscles from the small muscles of the hand to large muscles of the legs it is uncertain as to the techniques required, the optimal equipment design, the muscle groups with the greatest potential for treatment and the study design. This pilot study of two types of ESWT machines on a range of severe spasticity in neurological conditions aimed to answer some of these questions.

Methods: An uncontrolled trial of ESWT was tried on ten patients with severe spasticity. Two ESWT machines were tried – Orthowave 180 - with both focused (6 areas) and unfocussed (12 areas) heads and a Wolf Piezo Wave machine (3 areas). Patients included in this pilot study were those patients on rehabilitation wards in a hospital specializing in severe forms of neurological disorders. The patients all had acute onset brain damage due to trauma, anoxia or subarachnoid hemorrhage. The contracted limb was treated at the muscle tendon origins and insertions and also over the muscle belly. Measurement of range of movement was taken using the Neutral Zero Method, a standardized method of measurement of range of movement from a defined neutral point using a goniometer. This gave three measurement components: the range of flexion; the extension; and the level at which the deformity was fixed as a starting point. This assessment was carried out for passive movement of the joints and also the range for active movement by the patient.

Results: The treatment approach, both in time and area treated, needed to change throughout each session depending on the degree of muscle relaxation during the session, especially in the presence of deformities. The two ESWT devices used had both advantages and disadvantages: The Orthowave therapy head was heavy to hold, especially for long periods, but easily molded to the accessible skin surface of a contracted hand whereas the Piezowave head was more difficult to easily access some of the joints in a contracted limb. The high noise level of the Orthowave increased the spasticity in some patients and made it impossible to carry out in the presence of other patients thus limiting the treatment environment. Since it started up at a higher energy level than was required for treatment and the level could only be reduced by firing unnecessary shockwaves this added to the noise level without benefiting the patient. The Piezowave was a very quiet machine to work with. The Orthowave therapy head was easy to use and clean between patient treatments, whereas the Piezowave had to be dismantled after each patient for thorough cleaning. The Orthowave was not easy to push from one ward to another, whereas the Piezowave, a much smaller machine, was stored and moved around the hospital on a large dressings trolley.

Discussion: Since physiotherapy could not be discontinued on ethical grounds it is suggested that the most appropriate study is a randomized cross-over study of physiotherapy + placebo ESWT vs. physiotherapy + ESWT. The nature of spasticity is such that external factors such as sudden changes in temperature and noise increase the muscle tone. The sudden impact noise level is therefore an important factor limiting treatment with ESWT. This study suggests that the optimal requirements of

an ESWT machine for treating spasticity are: small head, flexibility for access to a wide range of joints, quiet, ease of cleaning (or availability of disposable covers) and ease of mobility.

Conclusion: A randomized controlled trial of physiotherapy vs. physiotherapy + ESWT is recommended. The optimal ESWT machine for treating spasticity needs to be quiet, have a small head, be flexible to enable access to a wide range of joints, be easily cleaned (or have disposable covers) and be easily mobile.

11th ISMST Congress in Juan le Pins, France, Abstract No. 48.

Study Performance: **orthowave180c**

1.1.22. Focused and Defocused ESWT. The Comparison of the Results in the Treatment of Heel Spurs (Sergej Marx, Richard Thiele, 2007)

International shock wave center (IZS), Berlin, Germany.

Introduction: In the former time only shockwave devices with focused and radio therapy heads were used in the orthopedic field. Since ca. 2 years defocused shockwave therapy head was used for wound and skin treatment. This was the reason to use therapy head for the heel spur treatments as well.

Methods: Between 1/2002 and 10/2005 there were treated 179 patients with heel spurs. Follow up: 6, 12, 18 and 124 weeks. The devices: HMT EvoTron and MTS Orthowave 180, Focus head: 1200 shocks, 0.12-0.14 mJ/mm², local anesthesia 5 Hz. Between 11/2005 and 12/2006 95 heel spur patients were treated with Orthowave 180 defocused therapy head, 1200 shocks, 0,14 mJ/mm², no local anesthesia, 5 Hz.

Results: Group 1: 20 weeks after the 1. Treatment (in some cases 2 and 3 treatments), VHS 96%, Roles and Maudsley score 67% excellent and good, 33% acceptable and poor Group 2: Defocused therapy head, 24 weeks, VHS 74% Roles and Maudsley score, 75,8% excellent and good, 24,2% acceptable and poor (drop out: group 1 45 patients, group 2 21 patients).

Discussion: Better results in group 2, because of the defocused therapy head or of no use of local anesthesia?

Conclusion: ESWT with defocused therapy heads seems to be good matter to treat orthopedic indications. Now it is necessary to make valid studies to proof the effectiveness of this kind of treatment.

10th IMST Congress in Toronto, Abstract No. 63.

Study Performance: **orthowave180**

1.1.23. Use of Extra-corporeal Shock Wave Therapy in the Treatment of Proximal Plantar Fasciitis: A Randomized, Prospective, Double-Blind, Placebo-Controlled Study (Naidoo et al., 2002)

Montefiore Medical Center of the Albert Einstein College of Medicine, Bronx, New York, USA.

The purpose of this study was to evaluate the effect of high-energy extra-corporeal shock wave therapy (ESWT) for treatment of proximal plantar fasciitis in patients unresponsive to other nonoperative treatment modalities. Forty-seven patients with persistent symptoms of proximal plantar fasciitis for more than six months, who met other strict inclusion criteria, were randomized tot wo groups for actual or placebo treatment. All participants completed pre and post treatment physical exams and questionnaires. The treatments were administered with the Orthowave device (FDA approved for investigational applications only) after injection of a local analgesic at the medial calcaneal tubercle.



Patients were treated with two sessions at a two-week interval. Each treatment consisted of 800 impulses of high energy acoustic shock waves. Follow-ups were done at 6, 12, and 24 weeks after the last treatment. All patients were placed on a standardized home therapy program and nonsteroidal anti-inflammatory medication. Each patient maintained a log for a daily assessment of pain and medication use. There was a significant alleviation of pain to palpation, improvement of function and activity, and patient assessment of pain in all treated patients at all follow-up visits. Pain improvements over baseline were 53% at 6 weeks; 74% at 12 weeks and 74% at 24 weeks. The placebo effect accounted for an average of 3% improvement of symptoms over baseline at 6 weeks, 14% at 12 weeks, and 11% at 24 weeks. We conclude that high energy ESWT is an effective modality for alleviating pain and improving the function and activity level of patients with chronic refractory proximal plantar fasciitis.

American Academy of Orthopaedic Surgeons Annual Meeting 2002, Poster Board Number: P198

Study Performance: **orthowave280**

1.2. Bone Healing Disorders

1.2.1. Shockwave Treatment vs Surgery for Proximal Fifth Metatarsal Stress Fractures in Soccer Players: A Pilot Study (Ramon et al., 2023)

Department of Physical Medicine and Rehabilitation, Hospital Quirónsalud Barcelona, Spain

Background: To compare the clinical, radiologic, and functional outcomes between shockwave and operative treatments for proximal fifth metatarsal stress fractures in soccer players in a pilot study.

Methods: Between 2017 and 2019, 18 soccer players with fifth metatarsal stress fractures attended at Mutuallidad de Futbolistas Españoles-Delegación Catalana were included. Patients were randomly assigned into 2 groups receiving either surgery with an intramedullary screw (group 1) or high-energy focused extracorporeal shockwave treatment (group 2 performed once a week for 3 weeks using 2000 impulses at an energy flux density of 0.21 mJ/mm² and 4 Hz frequency). Clinical (pain), radiologic (bone healing), and functional (Tegner Activity Scale and American Orthopaedic Foot & Ankle Society [AOFAS] ankle-hindfoot scales) outcomes before and after receiving the treatment were compared between both groups. In addition, ability and time to return to play was also compared between groups.

Results: No patients were lost to follow-up. There were no statistically significant differences at last follow-up between surgery and extracorporeal shockwave treatment for bone healing, pain relief, AOFAS ankle-hindfoot score, Tegner score, and time return to play. No complications were reported in either of the 2 groups.

Conclusion: In this pilot study, extracorporeal shockwave treatment and operative treatment were found to be equally effective at reducing pain, achieving bone healing, and allowing the soccer players to return to play after proximal fifth metatarsal stress fractures. This study suggests that ESWT may be a good option for the management of proximal fifth metatarsal stress fractures in soccer players. If this approach proves successful in larger trials, the shockwave approach might help avoid known complications of the surgical treatment like wound problems, nerve injury, and hardware intolerance. Further investigations with larger sample size should be conducted in order to confirm the present conclusions.

Study Performance: **orthogold100**

1.2.2.Focused Extracorporeal Shockwave Therapy for Youth Sports-related Apophyseal Injuries: Case Series (Shafshak & Amer, 2023)

Department of Physical Medicine, Rheumatology and Rehabilitation, Faculty of Medicine, Alexandria University, Al-Khartoum Square, Alexandria, 21526, Egypt

Background

Apophyseal overuse injuries are self-limited with skeletal maturity; however, they may be a source of significant pain and time lost from training. There is a lack of consensus for its management with the current available treatment, which might lag behind the ongoing development of regenerative medicine. The current retrospective case study aimed to assess the potential effectiveness and short-term safety of extracorporeal shockwave therapy (ESWT) in apophyseal injuries.

Methods

Data from 22 growing athletes [15 patients with Osgood-Schlatter disease and seven patients with Sever's disease] who received ESWT at a sports medicine unit in a university hospital were reviewed. All patients received low energy ($= 0.1 \text{ mJ/mm}^2$) level-focused ESWT using electrohydraulic generation technology. The clinical focusing technique was used upon applying ESWT.

Results

The number of sessions received to achieve full recovery ranged from 1 to 3 sessions. The time from treatment initiation to previous activity level was 2 weeks in 14 patients (63.3%), 4 weeks in seven patients (31.8%) and 11 weeks in one patient (4.5%). No adverse events were reported. No recurrence occurred up to 3 months after the last session.

Conclusion

ESWT is a potentially safe and effective treatment for apophyseal injuries. It may facilitate an early return to sport activities.

Study Performance: **OW180, Applicator CE50**

1.2.3.Double Screw versus Angular Stable Plate Fixation of Scaphoid Waist Nonunions in Combination with Intraoperative Extracorporeal Shockwave Therapy (ESWT) (Quadlbauer et al., 2023)

AUVA Trauma Hospital Lorenz Böhler - European Hand Trauma and Replantation Center, Donaueschingenstrasse 13, 1200, Vienna, Austria.

Introduction: Over the past years, different fixation techniques focused on rotational stability in order to increase stability and stimulate union rates. Additionally, extracorporeal shockwave therapy (ESWT) has gained importance in the treatment of delayed and nonunions. Purpose of this study was to compare the radiological and clinical outcome of two headless compression screws (HCS) and plate fixation in scaphoid nonunions, in combination with intraoperative high energy ESWT.

Materials and methods: Thirty-eight patients with scaphoid nonunions were treated by using a nonvascularized bone graft from the iliac crest and stabilization with either two HCS or a volar angular stable scaphoid plate. All patients received one ESWT session with 3000 impulses and energy flux per pulse of 0.41 mJ/mm^2 intraoperatively. Clinical assessment included range of motion (ROM), pain according to the Visual Analog Scale (VAS), grip strength, disability of the Arm Shoulder and Hand Score, Patient-Rated Wrist Evaluation Score, Michigan Hand Outcomes Questionnaire and modified Green O'Brien (Mayo) Wrist Score. To confirm union, a CT scan of the wrist was performed.

Results: Thirty-two patients returned for clinical and radiological examination. Out of these, 29 (91%) showed bony union. All patients treated with two HCS compared to 16 out of 19 (84%) patients treated by plate showed bony union on the CT scans. The difference was not statistically significant. However,



at a mean follow-up interval of 34 months, no significant differences could be found in ROM, pain, grip strength and patient-reported outcome measurements between the two HCS and plate group. Height-to-length ratio and capitulum angle improved significantly in both groups compared to preoperative.

Conclusions: Scaphoid nonunion stabilization by using two HCS or angular stable volar plate fixation and intraoperative ESWT results in comparable high union rates and good functional outcome. Due to the higher rate for a secondary intervention (plate removal), HCS might be preferable as first choice, whereas the scaphoid plate fixation should be reserved for recalcitrant (substantial bone loss, humpback deformity or failed prior surgical intervention) scaphoid nonunions.

Study Performance: [orthowave280](#)

1.2.4.ESWT Treatment of Compromised Clavicle Fracture Near Lung Tissue (Slezak et al., 2023)

Utah Valley University, Orem, UT 84058, USA.

Ludwig Boltzmann Institute for Traumatology, 1200 Vienna, Austria.

Introduction

Treatments with lung tissue in the treatment area have long been considered contraindications for extracorporeal shockwave therapy (ESWT) thus limiting the therapies' regenerative scope of application. This recommendation has been due to the potential tissue damage associated with cavitation induced pulmonary capillary bleeding which may occur at significant distances from the therapy site. In contrast, we consider the potential benefits of ESWT for near-lung bone fractures. A delay or failure to heal is the most common possible complication in clavicle fractures, especially in cases primarily treated conservatively. As the current standard therapy, surgical revision achieves good healing results, but are associated with potential surgery-related complications. Shockwave therapy proposes a comparable non-invasive alternative over surgical intervention while avoiding complications.

Material & Method

A prospective open clinical study was conducted on the efficacy of shockwave therapy in compromised, delayed, or non-union fractures of the clavicle. This retrospective monocentric study compares focused, electrohydraulic ESWT-treated fractures with traditional surgical outcomes. To assess safety and evaluate in-situ ESWT pressure fields during the therapy, a comprehensive three-dimensional computational simulation was performed. Based on applicator reference data, computer simulations provide insights into wave propagation and pressure zones about the lungs thus allowing for safety-guidance based on established ultrasound threshold parameters.

Results

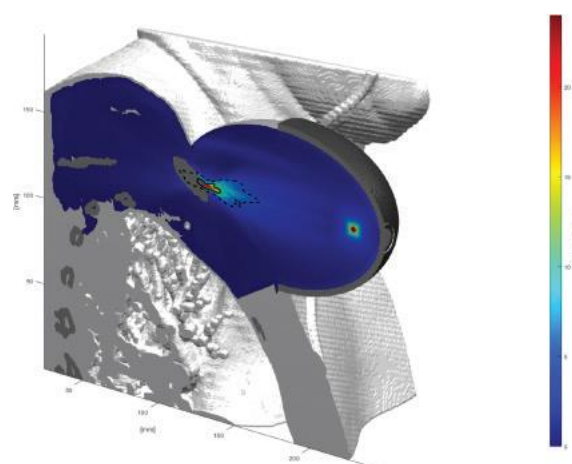
Three months post treatment 46% of the shockwave treated group showed consolidation which is similar to the healing in the surgical group. At the six-month time point both groups achieved healing in three quarters of the patients. ESWT treatments took significantly less time, incurred lower costs, and had no serious complications compared to 19% of the case in the surgical group. The latter further indicates that no evidence was found that lung tissue was damaged during the shockwave treatments. This is further supported by numerical simulations of the treatment which shows the mechanical index of tensile waves to be below FDA approved thresholds at all locations in the vicinity of the lungs.

Table 1

Outcome	ESWT (n = 28)	Surgery (n = 21)	p-Value
After 3 months			
Healed	13 (46%)	9 (43%)	>0.9999
Not healed	15 (64%)	12 (57%)	
After 6 months			
Healed	21 (75%)	15 (71%)	0.7172
Not healed	7 (25%)	3 (14%)	
Lost follow up	-	3 (14%)	
Complications			
Complications	0 (0%)	4 (19%)	0.0282 *
No complications	28 (100%)	21 (81%)	

Patient outcomes over time for ESWT and Surgical intervention

Figure 2



Simulated ESWT pressure fields in and about the therapy zone extending to the lungs.

Discussion

We show that based on numerical simulation and a clinical evaluation that shockwave treatment of for mid- and lateral-clavicle fractures is a safe and effective alternative. ESWT yields good healing results comparable to the surgical treatment, while avoiding surgery-related risks and complications. The presented two-pronged assessment of computational modelling and clinical evaluation allow for a systematic evaluation of potential additional future ESWT treatment sites about the lungs with excellent health outcomes while promising substantial health-care cost saving.

Technology: Focused electrohydraulic Shockwaves

Device and Manufacturer: Orthogold 280C, MTS Medical UG, Konstanz, Germany.

COI: No conflict of interest.

25th ISMST Congress Daegu, Korea, 2023. P-15.

Study Performance: [orthowave280](#)

1.2.5. Effective Treatment of Compromised Clavicle Fracture of the Medial and Lateral Third Using Focused Shockwaves (Mittermayr et al., 2022)

Department Meidling, AUVA Trauma Center Vienna, 1120 Vienna, Austria.

A delay or failure to heal is the most common possible complication in clavicle fractures, especially in cases primarily treated conservatively. As the current standard therapy, surgical revision achieves good healing results, but is associated with potential surgery-related complications. Shockwave therapy as



a non-invasive therapy shows similar reasonable consolidation rates in the non-union of different localizations, but avoids complications. Compromised clavicle fractures in the middle and lateral third treated with focused high-energy shockwave therapy were compared with those treated with surgical revision (ORIF). In addition, a three-dimensional computer simulation for evaluating the pressure distribution during shockwave application accompanied the clinical study. A comparable healing rate in bony consolidation was achieved in both groups. Significantly fewer complications, however, occurred in the shockwave group. The simulations showed safe application in this instance, particularly in avoiding lung tissue affection. When applied correctly, shockwaves represent a safe and promising therapy option for compromised clavicle fractures in the middle and lateral third.

Study Performance: **orthowave280**

1.2.6. The Role of Shockwaves in the Enhancement of Bone Repair - From Basic Principles to Clinical Application (Mittermayr R, Haffner N, Feichtinger X, 2021)

Ludwig Boltzmann Institute for experimental and clinical traumatology, Vienna, Austria; AUVA Trauma Center Meidling, Vienna, Austria; AUVA trauma research center, Vienna, Austria.

Extracorporeal shockwave therapy is a treatment modality, originally introduced into the clinic as lithotripsy, which has also been successfully used in the last two decades in the non-invasive treatment of delayed or non-healing fractures. Initially, the mechanism of action was attributed to microfracture-induced repair, but intensive basic research has now shown that the shockwave generates its effect in tissue via mechanotransduction. Numerous signal transduction pathways have already been demonstrated, which in their entirety trigger an endogenous regeneration process via cell proliferation, migration and differentiation. Clinically, these shockwave-conveyed biological signals support healing of acute, delayed and non-union fractures. The attainable outcome is comparable to surgery but avoiding an open approach with associated potential complications. These advantageous properties with a clearly positive cost-benefit ratio make shockwave therapy a first line treatment in delayed and non-union fractures.

Study Performance: **orthowave280**

1.2.7. High-Energy Extracorporeal Shockwave Therapy in Humeral Delayed and Non-Unions (Dahm et al., 2021)

AUVA Trauma Center Meidling, Kundratstr. 37, 1120, Vienna, Austria.

Introduction: Within the last few decades, focused high-energy extracorporeal shockwave therapy (ESWT) has proven to be an effective alternative to standard of care revision surgery in delayed healing fractures or manifest non-unions in various anatomical regions.

Materials and methods: A retrospective multi-variant analysis of an open prospective, single-armed clinical study was conducted. Patients receiving focused high-energy ESWT for a delayed healing or an apparent non-union of a humeral fracture between January 1999 and December 2015 at a single trauma center were included in the study. Bony healing was defined as cortical continuity in three of four cortices and pain-free force loading and evaluated using CT scans and clinical examination at three- and six-month follow-ups after ESWT.

Results: A total of 236 patients were included. N = 93 (43.8%) showed bony consolidation three months after ESWT and n = 105 (52.5%) after six months. Sub-group analysis showed significantly better

healing for the proximal metaphyseal humerus (66.7% after six months, n = 42) compared to the diaphyseal region (48.1%, n = 133) and distal metaphyseal humerus (48.1%, n = 25). Regression analysis indicated significantly increased healing rates for patients of younger ages ($p = 0.001$) and a fracture diastasis of less than 5 mm ($p = 0.002$).

Conclusion: The findings of this study indicate that ESWT can be considered as a treatment option for a well-selected patient population despite the lower healing rates compared to other anatomical regions.

Study Performance: **orthowave280**

1.2.8. Shockwave is Equally Effective in Treating Tibial Nonunion Compared to Standard of Care Surgery but Cause Significantly Less Direct Health Care Costs (Mittermayr et al., 2021)

AUVA Trauma Center Vienna, Austria.

Introduction

Delayed or non-healing bone fractures cause high suffering pressure in the affected patients, but also place high demands on the treating physician. In addition, protracted treatment through direct and indirect costs places a heavy burden on the socio-economic system. At present, surgical revision surgery is still the standard procedure, although recent studies indicate the high effectiveness of extracorporeal shock wave therapy (ESWT) in this indication.

Material & Method

Surgically treated tibial non-union from 2011 until 2018 in the AUVA trauma center Vienna, Meidling were retrospectively analyzed and compared to shockwave treated tibial non-unions from 2018 with respect to healing rate and direct health care costs.

Results

A healing rate of 73% (n=8) of previously non-healed tibial fractures was found after surgical intervention. A similar bony consolidation rate of tibial fractures was observed after shockwave therapy (82%; n=9). Considering the therapy-associated costs (surgical and inpatient treatment), there was a significantly lower financial expenditure for treatment with shockwaves (mean 2,943.4 € ± 619.1 € SD) compared to a surgical therapy with mean total costs of 13,381.4 ± € 9,241.3 € SD ($p < 0.0001$). In addition to the naturally significantly higher total surgical costs for surgically rehabilitated tibial pseudarthroses (mean 3054.3 € ± 1418.8 € SD) with an average surgical time of 156 minutes ± 69 minutes SD, it is primarily the ward costs (mean 13,381.4 € ± 9,241.3 € SD) that drive up the financial burden. Corresponding figures for shockwave treatment are 430.5 € average operation costs (± 128.5 € SD) with an average treatment time of 29 minutes (± 7 minutes SD). The mean ward costs amounted to 2,512.9 € (± 565.3 € SD).

Discussion

Same radiological healing rate of tibial pseudarthrosis was found with extracorporeal shockwave therapy in comparison to standard of care surgery. In the same time, however, ESWT cause significantly lower associated direct costs compared to surgical remediation. ESWT should therefore be considered the therapy of the first choice in this indication.

Study Performance: **orthogold280**

23rd World Congress of the ISMST 2021 in Vienna, Austria, 9. Recent developments of ESWT in orthopedics and traumatology.



1.2.9. *Successful Salvage via Re-Osseointegration of a Loosened Implant in a Patient with Transtibial Amputation* (Gstoettner et al., 2020)

Clinical Laboratory for Bionic Extremity Reconstruction, Department of Surgery, Medical University of Vienna, Vienna, Austria.

Case description: Osseointegration is a relatively new technique for prosthetic limb attachment that offers various improvements for patients with amputation and facilitates joint preservation. We present a case of implant loosening during rehabilitation in a patient with transtibial amputation that was successfully managed through a combination of measures, aiming to promote re-osseointegration of the implant.

Objectives: Not much is known about structured management of adverse events after osseointegration. Septic or aseptic loosening is currently regarded as implant failure, prompting removal and possible re-implantation at a later stage. The objective of this case report was to evaluate the feasibility of salvaging a loosened implant.

Study design: Case report.

Treatment: A novel treatment approach was employed to enable renewed osseointegration of the implant. First, the bone-implant interface was disrupted and renewed through axial rotation and distal repositioning of the implant. Afterwards, extracorporeal shockwave therapy and antibiotic treatment were administered. Prosthetic rehabilitation was then started anew. Regular follow-up x-rays and clinical evaluations were conducted, including standardized outcome tests.

Outcomes: These combined measures led to a successful re-osseointegration of the implant. In a 21-month follow-up, the patient regained a stable and secure gait pattern, using his prosthesis every day for 15 hours and scoring above average on standardized outcome measures.

Conclusion: This represents the first report of implant salvage after failed primary osseointegration. As the associated risks of this novel treatment are very low, investigations are warranted to evaluate this approach on a larger scale.

Study Performance: **orthogold280**

1.2.10. *Shockwave Treatment for Specific Injuries Including Stress Fractures in Soccer Athletes* (Ramon et al., 2020)

Hospital Quirónsalud, Barcelona, Spain.

Injuries are a complication in soccer causing absenteeism in the athlete's career. The most common diagnoses are muscle/tendon injuries of the lower extremities. Some injuries or re-injuries may be potentially serious and cause longer absences in time loss from soccer play. Stress fractures of the fifth metatarsal are relatively common in soccer. The purpose of this study was to compare the clinical, radiological, and functional outcomes between shockwave and surgical treatments for fifth metatarsal stress fractures in soccer players.

Methods

Between 2017 and 2019, 18 soccer players with fifth metatarsal stress fractures attended at Hospital Quirónsalud Barcelona were included. Patients were randomly assigned into two groups receiving either surgery (group 1) or high-energy focused extracorporeal shockwave treatment (F-ESWT) (group 2). F-ESWT was performed once a week for three weeks using the electrohydraulic technology (Orthogold 100 MTS): 2.000 impulses at an energy flux density of 0.21 mJ/mm² and 4 Hz frequency. Clinical (pain), radiological (bone healing), and functional (Tegner and American Orthopedic Foot and

Ankle Score scales) outcomes before and after receiving the treatment were compared between both groups. In addition, ability and time to return to play was also compared between groups.

Results

There were no statistically significant differences for time to achieve bone healing, pain relief, American Orthopedic Foot and Ankle Score scale, Tegner scale and ability and time return to play between surgery and F-ESWT. No complications were reported in any of the two groups.

Conclusion

Extracorporeal shockwave treatment and surgical treatment are both equally effective at reducing pain, achieving bone healing, and allowing the soccer players to return to play after fifth metatarsal stress fractures. Therefore, F-ESWT is recommended over surgery because of its non-invasive nature and high safety profile (avoiding potential complications from surgical treatment).

Autumn congress of the College of Club Doctors and Consultants (CCC).

Study Performance: **orthogold100**

1.2.11. *Treatment of Scaphoid Waist Nonunion by One, Two Headless Compression Screws or Plate with or without Additional Extracorporeal Shockwave Therapy* (Quadlbauer et al., 2019)

AUVA Trauma Hospital Lorenz Böhler - European Hand Trauma Center, Vienna, Austria.

Introduction: Scaphoid nonunion remains challenging for hand surgeons. Several treatment options are available such as: non-vascularized or vascularized bone grafting, with or without additional stabilization. In the last few decades, extracorporeal shockwave therapy (ESWT) has become an established procedure for treating delayed and nonunions. Purpose of this retrospective follow-up study was (a) to investigate union rate and clinical outcome of the different implants [either one/two headless compression screws (HCS) or a plate] and (b) union rate and clinical outcome using only surgery, or a combination of surgery and ESWT.

Materials and methods: The study included 42 patients with scaphoid nonunions of the waist with a mean follow-up of 52 months. All patients received a non-vascularized bone graft from the iliac crest and stabilization was achieved by using one, two HCS or a plate. ESWT was performed with 3000 impulses, energy flux density per pulse 0.41 mJ/mm² within 2 weeks after surgery. Clinical assessment included range of motion (ROM), pain according to the Visual Analog Scale (VAS), grip strength, Disability of the Arm Shoulder and Hand Score, Patient-Rated Wrist Evaluation Score, Michigan Hand Outcomes Questionnaire and modified Green O'Brien (Mayo) Wrist Score. In addition, each patient had a CT scan of the wrist.

Results: A total of 33/42 (79%) patients showed union at the follow-up investigation. Patients treated with additional ESWT showed bony healing in 21/26 (81%) and without ESWT in 12/16 (75%). Patients that were stabilized using one HCS showed bony healing in 6/10 (60%), with two HCS 10/12 (83%) and by plate 17/20 (85%). The ESWT group had a significantly lower pain score according to the VAS and better modified Green O'Brien (Mayo) Score. No differences could be found in respect of ROM, grip strength, functional outcome score depending of which stabilization method was used.

Conclusions: Stabilization of scaphoid waist nonunions with two HCS or plate showed higher union rates than a stabilization using only one HCS. In addition, ESWT combined with a nonvascularized bone graft from the iliac crest seems a suitable option for treating scaphoid nonunions.

Study Performance: **orthowave280**



1.2.12. *Extracorporeal Shockwave Therapy for the Treatment of Scaphoid Delayed Union and Nonunion: a Retrospective Analysis Examining the Rate of Consolidation and Further Outcome Variables* (Fallnhauser et al., 2019)

Paracelsus Medizinische Privatuniversität Humanmedizin.

Background: Operative procedures are considered gold standard in the treatment of scaphoid nonunion, albeit their considerable complexity and the risk of intraoperative complications. High energy extracorporeal shockwave therapy (ESWT) offers a non-invasive treatment option for scaphoid nonunion. The aim of this study was to explore the rate of bony consolidation and further outcome variables in patients with delayed union of scaphoid fractures and scaphoid nonunion treated with ESWT.

Patients and methods: Due to delayed union (21) or nonunion (21) of a scaphoid fracture 42 patients (37 men, and 5 women) with an average age of 48,3 (15-66) years underwent ESWT followed by immobilization in a forearm cast including the proximal phalanx of the thumb for 6 to 8 weeks. In 13 patients the fracture was initially treated, 8 with immobilization, 5 with screw fixation. In 5 of the 29 patients without an initially treatment, the fracture resp. nonunion was secondarily treated with screw fixation (2) or a medial femur condyle (3) but failed to heal. 10 to 12 weeks after the ESWT bony healing was controlled with computed scanning in the long axis of the scaphoid. If 50 % of diameter of the scaphoid showed trabecula bony healing was considered. Factors with potential influence on bony healing (site of the fracture/nonunion, scapholunate angle, patient's age, Body Mass Index, smoking and alcohol consume) were analyzed. In addition, 34 patients underwent a clinical follow-up examination including DASH and Mayo Wrist Score, pain analyzes (VAS).

Results: Seventy-one per cent of patients showed scaphoid fracture consolidation using ESWT. In 7 out of 8 patients with conservative treatment and in 4 out of 5 patients with screw fixation of the initial fracture bony healing was achieved. From the 5 patients with secondary surgical treatment of the scaphoid only 1 patient, treated with a medial femur condyle, failed to heal the scaphoid. 15 out of the 24 initially non-treated scaphoid fractures healed. The time between ESWT and the documented bony healing averaged 8.4 months (256 days). Neither fracture site, nor the scapholunate angle, alcohol and tobacco use, as well as biometric factors, such as age and BMI had influence on the success rate of the ESWT. Side effects of the ESWT were limited to local skin irritations and petechial bleedings.

Conclusion: ESWT has a positive effect regarding bony healing of scaphoid fracture with delayed fracture healing and nonunion with a success rate of 71 %. The complication rate is low, and the clinical results regarding wrist motion and pain are satisfying. Further investigations are necessary to evaluate the input of fracture/nonunion characteristics like the morphological appearance on bony healing.

Study Performance: **orthogold280**

1.2.13. *Effect of Unfocused Extracorporeal Shockwave Therapy on Bone Mineral Content of Twelve Distal Forearms of Postmenopausal Women: A Clinical Pilot Study* (Koolen et al., 2019)

Department of Orthopaedics, University Medical Centre Utrecht, Utrecht, The Netherlands.

Extracorporeal shockwave therapy showed a pronounced effect on bone mass in previous animal studies. We showed in this pilot study that a single treatment with unfocused shockwave therapy in unselected patients does not show side effects. Although our study did not show any effect of shockwave on BMD, the limited sample size does not definitively exclude this and a study with 174 subjects per group would be needed to show an effect size of 0.3 with a power of 80%.

Purpose: Unfocused extracorporeal shockwave therapy might stimulate bone formation to reduce the fracture risk. In this study, we assessed the safety of unfocused extracorporeal shockwave therapy and its effects on bone mass.

Methods: A clinical pilot study with twelve female patients free of bone disease undergoing elective surgery of the lower extremity or elective spinal surgery under general anesthesia received 3.000 electrohydraulic-generated unfocused extracorporeal shockwaves (energy flux density 0.3 mJ/mm^2) to one distal forearm. The contralateral forearm served as a control. We examined the effect on bone mass with the use of repeated dual energy X-ray absorptiometry measurements and we measured patient discomfort around the therapy.

Results: No difference in bone mineral content and density was measured 6 and 12 weeks after therapy. shockwave therapy occasionally caused transient erythema or mild hematoma, but no discomfort in daily life or (late) adverse events.

Conclusions: Unfocused extracorporeal shockwave therapy is a safe treatment, but no increase in bone mass on the forearm was found at 0.3 mJ/mm^2 energy flux density. In this study, we were not able to demonstrate that a single treatment with unfocused shockwave therapy in unselected patients had any effect in terms of bone mineral density (BMD) or bone mineral content (BMC). A power analysis indicated that 174 patients per group are required to show an effect size of 0.3 with a power of 80%.

Study Performance: **orthogold180c**

Also presented at the 23rd World Congress of the ISMST 2017 in Vienna, Austria, 9. Recent developments of ESWT in orthopedics and traumatology.

1.2.14. Extracorporeal Shockwave Therapy (ESWT) Ameliorates Healing of Tibial Fracture Non-Union Unresponsive to Conventional Therapy (Haffner et al., 2016)

Orthopaedic Hospital Gersthof, Vienna, Austria.

Tibial non-unions are common cause of demanding revision surgeries and are associated with a significant impact on patients' quality of life and health care costs. Extracorporeal shockwave therapy (ESWT) has been shown to improve osseous healing in vitro and in vivo. The main objective of present study was to evaluate the efficacy of ESWT in healing of tibial non-unions unresponsive to previous surgical and non-surgical measures. A retrospective multivariant analysis of a prospective open, single-centre, clinical trial of tibia non-union was conducted. 56 patients with 58 eligible fractures who met the FDA criteria were included. All patients received 3000-4000 impulses of electrohydraulic shockwaves at an energy flux density of 0.4 mJ/mm^2 (-6dB). On average patients underwent 1.9 times ($\pm 1.3 \text{ SD}$) surgical interventions prior to ESWT displaying the rather negatively selected cohort and its limited therapy responsiveness. In 88.5% of patients receiving ESWT complete bone healing was observed after six months irrespective of underlying pathology. The multivariant analysis showed that time of application is important for therapy success. Patients achieving healing received ESWT earlier: mean number of days between last surgical intervention and ESWT (healed - $355.1 \text{ days} \pm 167.4 \text{ SD}$ vs. not healed - $836.7 \text{ days} \pm 383.0 \text{ SD}$; $p < 0.0001$). ESWT proved to be a safe, effective and non-invasive treatment modality in tibial non-unions recalcitrant to standard therapies. The procedure is well tolerated, time-saving, lacking side effects, with potential to significantly decrease health care costs. Thus, in our view, ESWT should be considered the treatment of first choice in established tibial non-unions.

Study Performance: **orthogold280**



1.2.15. *Extracorporeal Shockwave Therapy (ESWT) Ameliorates Healing of Tibial Fracture Non-Union Unresponsive to Conventional Therapy (Mittermayr et al., 2015)*

AUVA Trauma Center Meidling Vienna, Austria; Ludwig Boltzmann Institute, Vienna, Austria.

Introduction: Tibial non-unions are common cause of demanding revision surgeries and are associated with a significant impact on patients' quality of life and health care costs. Extracorporeal shockwave therapy (ESWT) has been shown to improve osseous healing *in vitro* and *in vivo*. The main objective of present study was to evaluate the efficacy of ESWT in healing of tibial non-unions unresponsive to previous surgical and non-surgical measures.

Methods: A retrospective multivariant analysis of a prospective open, single-center, single-arm, clinical trial of patients suffering from tibia non-union was conducted. Fifty-six patients with 58 eligible fractures who met the FDA criteria for non-unions characterized as being at least 9 months old and lacking any radiological signs towards osseous healing over the last 3 months were included. All patients received 3000 to 4000 impulses of electrohydraulic generated extracorporeal shockwaves at the fracture site at an energy flux density of 0.4mJ/mm^2 (-6db) and a frequency of 4 Hz.

Results: Six patients with six fractures were lost in follow up and excluded from the analysis. On average patients underwent 1.9 times (± 1.3 SD) previous surgical interventions prior to ESWT displaying the rather negatively selected cohort and its limited therapy responsiveness. In the 88.5% of the ESWT treated patients we observed complete bone healing after six months irrespective of fracture location,

underlying pathology and importantly presence of infection. The multivariate analysis showed that time of application is important for success of the therapy. Patients achieving successful healing received ESWT earlier: mean number of days between last surgical intervention and first ESWT (healed -355.1 days ± 167.4 SD vs. not healed -836.7 days ± 383.0 SD; $p < 0.0001$).

Discussion:

ESWT proved to be a safe, effective and non-invasive treatment modality in patients suffering from tibial non-unions recalcitrant to standard therapies. The procedure is well tolerated, time-saving, lacking serious side effects, with potential to significantly decrease health care costs associated with tibial non-unions. Thus, in our view, ESWT should be considered the treatment of first choice in established tibial non-unions.

18th International Congress of the ISMST 2015, Mendoza, Argentina. Abstract No. 21.

Study Performance: **Derma**gold180, **Ortho**wave280

1.2.16. *Combined Treatment of Scaphoid Non-Union by Surgery and Additional Extracorporeal Shockwave Therapy (ESWT) (Quadlbauer et al., 2013)*

AUVA Trauma Hospital Lorenz Böhler - European Hand Trauma Center; AUVA Trauma Hospital Meidling; (3) Ludwig-Boltzmann-Institute for experimental und clinical traumatology, Vienna; Austria.

Introduction: Non-union of the scaphoid is even today a challenge for the treating hand surgeon. Main cause of a scaphoid non – union is the overlooked fracture with an inadequate immobilization or a fracture in the proximal third of the scaphoid. Through its specific retrograde blood supply, with entrance of nutritive blood vessels in the distal pole the proximal pole is only supplied by terminal blood vessels. However, as a consequence scaphoid non-union lead to an osteosclerosis at the fracture surfaces and tilting of the fracture ("humpback – deformity"). Tilting of the fracture and instability of the wrist causes a change in wrist biomechanics and leads to wrist arthritis. These changes

consequently result at the end in a carpal collapse the so-called SNAC – wrist. Several methods for treating scaphoid non-union are available, like sole bone graft in the technique according to Matti–Russe additional stabilization through a headless bone screw or angle stable plate. In the last decades extracorporeal shockwave (ESWT) established in the treatment of non-union. Schaden et. al reported a healing rate of delayed union or nonunion treated by ESWT of 81 %. However, the mechanism of shockwave therapy is not fully understood, there is good evidence that it leads to an angio- and vasculogenesis in the treated tissue which causes a persisting increase of blood supply. It was also shown in recent publications that shockwaves have a positive influence on the migration and even differentiation of stem cells. To our knowledge there is no publication that proves the effects of combined therapy of scaphoid non-union by surgery with headless bone screw or plate and additional extracorporeal shockwave therapy.

Methods: All scaphoid non-unions, treated by operation and additional ESWT had been read out of the archive of the AUVA (Allgemeine Unfallversicherungsanstalt - the Austrian Workers' Compensation Board), anonymized by the patient's number and had been analyzed retrospectively. For statistical analysis age, gender, range of motion (ROM), date of accident, date of surgery, last follow up, surgical technique was investigated. All fractures had been classified by the Herbert classification. The last CT was analyzed to judge bony bridging and signs of arthritis. An existing DISI – deformity, SNAC – wrist or humpback deformity had been documented.

Results: With a combined therapy of surgery and additional ESWT in all cases fracture union was achieved. DISI – deformity, SNAC – wrist or humpback deformity wasn't found in any case.

Discussion: In a high percentage ESWT leads to union of delayed or non - union fractures and increases the union rates in combination with surgery in scaphoid non-unions.

Conclusion: Combined therapy of scaphoid non-union by surgery and additional ESWT should be considered as standard therapy in scaphoid non-unions.

16th ISMST Congress in Salzburg, Austria, Abstract No. P50.

Study Performance: **orthogold280**

1.2.17. ESWT: An Extraordinary Tool for Tissue Regeneration and Remodeling (D'Agostino et al., 2013)

Shock Wave Therapy & Research Unit, Rehabilitation Department - IRCCS Istituto Clinico Humanitas, Milano, Italy.

Introduction: Regenerative Medicine nowadays represents the new frontiers of ESWT. The authors propose some interesting case reports supporting this argument, by showing some unexpected therapeutical results that suggest new perspectives and insights about this topic.

Methods: Case A and B: two patients, with tibial fracture delayed healing, both presenting also skin ulcers, distally to the fracture site.

Case C: a sportsman, with painful swelling of the distal calf (muscular and cutaneous fibrosis, due to a deep wound).

Case D: A young woman with hip osteonecrosis.

Case E: A woman with delay of femoral fracture healing and extensive skin fibrosis of the lower limb (crash trauma --> skin graft).

All patients were treated with different ESWT protocols, according to each disease.

Results: The use of ESWT resulted in these outcomes:

Case A and B: bone healing, and surprisingly, a faster repair of the ulcers, away from the fracture site and therefore not directly treated;

Case C: resolution of pain and swelling, as well as reduction of muscular fibrosis.



Case D: arrest of necrotic evolution and bone remodeling appearance (with a trophic effect) at medium-long term follow-up (> 5 y).

Case E: besides bone healing, unexpected hair regrowth and reactivation of sweating, reduction of skin fibrosis and tactile hypersensitivity. All results were documented by clinical and instrumental data (including photos).

Discussion: These case reports would suggest some positive changes after ESWT: Real stem cell mobilization “in vivo”, with effects at a distance. A regenerative effect also on intact tissues (remodeling action). The authors will discuss in detail the regenerative potential of ESWT that seems to be even more extraordinary than believed and proven. It is effective also on already healed or “intact” tissues (remodeling effect).

Conclusion: We expect that the use of ESWT will be further encouraged as a safe and versatile therapy, both alone and associated to other treatment tools in the field of Regenerative Medicine. New studies will be able to widen the list of therapeutical indications, especially in the field of post – traumatic and complicated clinical cases.

16th ISMST Congress in Salzburg, Austria. Abstract No. P29.

Study Performance: **orthogold100**

1.2.18. Development of a Prognostic Naïve Bayesian Classifier for Successful Treatment of Nonunions (Stojadinovic et al., 2011)

Walter Reed Army Medical Center, Washington, DC 20307, USA.

Background: predictive models permitting individualized prognostication for patients with fracture nonunion are lacking. The objective of this study was to train, test, and cross-validate a Bayesian classifier for predicting fracture-nonunion healing in a population treated with extracorporeal shock wave therapy.

Methods: prospectively collected data from 349 patients with delayed fracture union or a nonunion were utilized to develop a naïve Bayesian belief network model to estimate site-specific fracture-nonunion healing in patients treated with extracorporeal shock wave therapy. Receiver operating characteristic curve analysis and tenfold cross-validation of the model were used to determine the clinical utility of the approach.

Results: predictors of fracture-healing at six months following shock wave treatment were the time between the fracture and the first shock wave treatment, the time between the fracture and the surgery, intramedullary stabilization, the number of bone-grafting procedures, the number of extracorporeal shock wave therapy treatments, work-related injury, and the bone involved ($p < 0.05$ for all comparisons). These variables were all included in the naïve Bayesian belief network model.

Conclusions: a clinically relevant Bayesian classifier was developed to predict the outcome after extracorporeal shock wave therapy for fracture nonunions. The time to treatment and the anatomic site of the fracture nonunion significantly impacted healing outcomes. Although this study population was restricted to patients treated with shock wave therapy, Bayesian-derived predictive models may be developed for application to other fracture populations at risk for nonunion.

Study Performance: **orthowave280**

1.2.19. Quality Control of ESWT in the Treatment of Non-Union Fractures (Schaden et al., 2011)

Trauma Centre Meidling, Vienna, Austria.

Introduction: Since December 1998 delayed and non-union fractures have been treated with ESWT on a regular basis in the AUVA Trauma Centre Meidling. Up to December 2009 a total of 1611 patients were treated and 70 parameters were documented for each patient. The data set includes demographic data, medical history, treatment parameters, side effects, and follow-up treatment as well as 3 and 6-month results. Since 153 (9,5%) patients were lost to follow-up, data for only 1458 patients are available.

Methods: Because the data were collected in a linked access database some important correlations can be made immediately. The database will be demonstrated during the presentation and the audience will have the opportunity to ask questions concerning age of the patients, age of the non-unions, treatment parameters, etc. in correlation to the outcome (3 and 6-month results).

For example,

Question: “What was the healing rate in patients over 80 years of age that received ESWT for their non-unions?” Answer: n = 50 (14 male/34 female: mean age: 83.8 (range: 80-93); 47 fractures / 3 osteotomies; metaphyseal = 27 / diaphyseal = 23; healing rate after 3 months: 32 (64%); after 6 months: 42 (84%).

Results: The overall healing rate was 77% (1120). Only minor side-effects, such as temporary superficial haematoma, petechial bleedings and reddening of the skin, were observed. None of them had a clinical impact and disappeared after 3 to 5 days without treatment.

Discussion: The quality control facilitated by collecting these data enabled us to optimize treatment parameters. The treatments were performed by a total of 25 trauma surgeons and there were no significant differences in the outcomes between the physicians.

Conclusion: These results prove that ESWT for the treatment of delayed and non-healing fractures is not only efficient and safe but has practically no learning curve and is easily reproducible.

14th ISMST congress 2011 in Kiel, Germany, Abstract No. 28.

Study Performance: **orthowave280**

1.2.20. ESWT for Non-Union Fractures – Economic Aspects (Schaden et al., 2011)

Trauma Centre Meidling, Vienna, Austria.

Introduction: Incidence of non-unions in Austria:

Between 2005 and 2009 a total of 224,749 fractures were documented in all 7 AUVA Trauma Centers in Austria. During the same time period, 5.706 non-unions were registered. This indicates that 2.53% of fractures develop in a non-union. Throughout Austria 4000.000 fractures are reported annually, thus approximately 10.000 non-unions per year are to be expected.

Methods:

Traditional Therapy:

Data from health insurance companies show that surgical treatment of non-unions is successful in 68% of patients after one surgical procedure, in 23% after two and in 7% after three. While the remaining 2% of non-unions end in amputation.

Shockwave therapy:

Based upon our experience, 70% of non-unions are suitable for ESWT (i.e. 7.000 patients per year).

Results: The estimated cost of one surgical procedure for a non-union is at least 10.000, thus surgical treatment of all non-unions in Austria burdens the health care system by approximately 100 MIO per year. If the 7.000 suitable patients were offered ESWT, 75% could expect bony healing. Calculated at



1.000 per ESWT treatment, the total cost to heal 5.250 patients (75% of 7.000) would be 8.75 MIO. The remaining 25% would require surgical treatment at a total cost of 25 MIO.

Discussion: Based upon these estimates, more than 66 MIO per year could be saved in Austria by treating all suitable non-unions with EWT. This is in addition to the cost savings from shorter rehabilitation time and less sick leave, which are not included in this calculation.

Conclusion: As recently published peer reviewed articles prove, ESWT is as efficient as surgery but with less complications and shorter rehabilitation time; therefore, it is perplexing why less than 1% of non-unions in Europe receive this treatment option.

14th ISMST congress 2011 in Kiel, Germany, Abstract No. 29.

Study Performance: **orthowave280**

1.2.21. ESWT in Foot Navicular Stress Fracture of a High Performance (Sergio Abello, Carlos Leal, 2011)

Ortomec feet center, Bogota, Columbia.

Introduction: We present the case of a 16-year old competitive Olympic female gymnast with a history of foot problems. After athletic training she experienced pain on the medial side of her right foot and was initially diagnosed with Posterior Tibial Tendon Tendinitis after normal X-rays. She received physical therapy and medication for 3 months with no results. She came to our foot and ankle clinic and after a physical evaluation we suspected a deeper bone or joint pathology and ordered an MRI. The results clearly indicated a navicular bone stress fracture.

Methods: We proceeded to treat the patient with ESWT, using a single session under sedation of 2000 pulses at 0.25 mJ/mm² focused waves and a frequency of 4 Hz. The procedure was done under X-ray fluoroscopy from dorsal to plantar with an Orthogold 100 device and an OE050 focused applicator. After the procedure, the patient was in a cast of 6 weeks. After removing the cast, the patient underwent physical therapy and muscle balance rehabilitation.

Results: Both pain and motion improved, and the control MRI showed complete healing of the lesion.

Discussion: Even though this is a case report, we found ESWT to be the crucial variable for recovery in this patient's final outcome. With no complications related to the procedure, it was an excellent option for this high-performance athlete, enabling full recovery of her symptoms after two months of treatment.

Conclusion: We are able to recommend ESWT in these rare cases of foot stress fracture.

14th ISMST Congress in Kiel, Germany, Abstract No. 26.

Study Performance: **orthogold100**

1.2.22. Shock Wave Therapy Compared with Intramedullary Screw Fixation for Nonunion of Proximal Fifth Metatarsal Metaphyseal-Diaphyseal Fractures (Furia et al., 2010)

Evangelical Community Hospital, Milton S. Hershey Medical Center, Hershey, Pennsylvania 17033, USA.

Background: The current "gold standard" for treatment of chronic fracture nonunion in the metaphyseal-diaphyseal region of the fifth metatarsal is intramedullary screw fixation. Complications with this procedure, however, are not uncommon. Shock wave therapy can be an effective treatment for fracture nonunions. The purpose of this study was to evaluate the safety and efficacy of shock wave therapy as a treatment of these nonunions.

Methods: Twenty-three patients with a fracture nonunion in the metaphyseal-diaphyseal region of the fifth metatarsal received high-energy shock wave therapy (2000 to 4000 shocks; energy flux density per pulse, 0.35 mJ/mm²), and twenty other patients with the same type of fracture nonunion were treated with intramedullary screw fixation. The numbers of fractures that were healed at three and six months after treatment in each group were determined, and treatment complications were recorded.

Results: Twenty of the twenty-three nonunions in the shock wave group and eighteen of the twenty nonunions in the screw fixation group were healed at three months after treatment. One of the three nonunions that had not healed by three months in the shock wave group was healed by six months. There was one complication in the shock wave group (post-treatment petechiae) and eleven complications in the screw-fixation group (one refracture, one case of cellulitis, and nine cases of symptomatic hardware).

Conclusions: Both intramedullary screw fixation and shock wave therapy are effective treatments for fracture nonunion in the metaphyseal-diaphyseal region of the fifth metatarsal. Screw fixation is more often associated with complications that frequently result in additional surgery.

Study Performance: **orthowave280**

1.2.23. Shock Wave Therapy Versus Intramedullary Screw Fixation for Nonunion of the Proximal Fifth Metatarsal Metaphyseal Diaphyseal (Jones) Fracture (Furia et al., 2010)

SUN Orthopedics and Sports Medicine. Chief Foot and Ankle Division, Dep. of Orthopedics. AUVA Trauma Center Meidling, Austria. Ludwig-Boltzmann-Institute for Experimental and Clinical Traumatology, 1090 Vienna, Austria

Introduction: The current “gold standard” for treatment of chronic fracture nonunion of the fifth metatarsal metaphyseal diaphyseal region is intramedullary screw fixation (ISF). Complications with this procedure, however, are not uncommon. Shock wave therapy (SWT) can be an effective treatment for fracture nonunions. The purpose of this study was to evaluate the safety and efficacy of SWT as a treatment for fracture nonunions of the fifth metatarsal metaphyseal diaphyseal region.

Methods: Twenty-three patients with a fracture nonunion of the fifth metatarsal metaphyseal diaphyseal region received high-energy SWT (SWT Group; 2000 to 4000 shocks; energy flux density per pulse, 0.35mJ/mm²). Twenty patients with a fracture nonunion of the fifth metatarsal metaphyseal diaphyseal region were treated with ISF. Evaluation was by determination of the number of fractures healed at 3- and 6-months post-treatment and by incidence of complications.

Results: 20/23 nonunions in the SWT group and 18/20 nonunions in the ISF group were healed 3 months post-treatment. 21/23 nonunions in the SWT group and 18/20 nonunions in the ISF group were healed 6 months post-treatment. There was one complication in the SWT group (one case of post-treatment petechiae) and 11 complications in the ISF group (1 refracture, 1 cellulitis, and 9 cases of symptomatic hardware).

Discussion: The present study evaluated the effects of SWT on a series of patients with a nonunion of a proximal fifth metatarsal metaphyseal diaphyseal fracture who had not responded to nonoperative management. The outcome for the entire population was evaluated and compared to a group of similar patients treated with ISF. Unlike prior studies, and one of the strengths of this trial, the patient groups were homogenous.

Eight-seven percent (20/23) of the SWT fractures and 90% (18/20) of the ISF fractures were healed 3 months post-treatment; 91% (21/23) of the SWT fractures and 90% (18/20) of the ISF fractures were healed 6 months post-treatment. SWT was well tolerated and yielded only one complication. ISF yielded 11 complications including 9 cases of symptomatic hardware that required a second surgical procedure and one refracture that required additional immobilization.



Conclusion: Both ISF and SWT are effective treatments for fracture nonunions of the fifth metatarsal metaphyseal diaphyseal region. ISF is associated with complications that frequently result in additional surgery.

13th ISMST Congress in Chicago, USA. Abstract No. 32.

Study Performance: **orthowave280**

1.2.24. *Extracorporeal Shockwave Therapy for Non-Unions and Delayed Healing Fractures (A. Valentin et al., 2007 / 2008)*

Trauma Centre Meidling, Vienna, Austria.

Introduction: The objective of every fracture treatment is to reunite the fracture fragments in an anatomical position and completely restore the function of the injured section of the skeleton as quickly as possible. Despite today's sophisticated technologies and good primary treatment, 1-3% of all bone fractures develop into pseudarthrosis. Surgical treatment with debridement of the pseudarthrotic tissue, cleaning of the fragment edges, insertion of autologous spongiosa and stabilization with osteosynthesis material is considered the "gold standard" for the treatment of pseudarthrosis. However, these surgical procedures are extremely traumatic for the patient, costly, time-consuming, and are associated with a high rate of complications. Therefore, after successful pilot studies, in December 1998 the Trauma Centre Meidling started to treat non-unions regularly with shockwave therapy. Different devices were used and success rates between 63% and 75% were generated. Since August 2005 we have used the Orthowave 280c, Tissue Regeneration Technologies (manufactured by MTS Europe GmbH, Konstanz, Germany).

Methods: From the start of the study, more than 50 patient-specific data items were stored in a database developed specially to permit the combination of a broad range of parameters. This database structure serves as the basis for quality assurance measures and enables the researchers to determine the optimal treatment parameters and other important criteria. This database containing documentation of the treatment of pseudarthrosis with ESWT is made available to all interested parties free of charge; it can be ordered from the authors. Treatment was basically envisaged as a single treatment. Depending on the region to be treated, shockwave therapy was administered under general, regional or local anesthesia. Thus far, 527 patients have been treated. As of March 2008, results of 349 patients with complete follow up are available. The patients, referred from 45 different hospitals, consisted of 114 females (33%) and 235 males (67%). The mean age was 49.0 years with a range from 16-91 years. The average delay between the injury or the last operation and the shockwave therapy was 11.7 months (in 241 / 69% patients more than 6 months, in 108 / 31% patients between 3 and 6 months / delayed healing). Eighteen of the non-unions were infected. Depending on the localization, between 2,000 and 4,000 pulses were applied (1,000 pulses per treatment location). We used an energy flow density (EFD) of 0.35 mJ/mm² for all bone treatments. For evaluation, the bony consolidation of the fracture/non-union was observed on plain radiography or CT. Following shockwave therapy the pseudarthrosis is immobilized like a fresh fracture. This is usually carried out with a plaster cast or plastic splint; in 3 patients with especially mobile tibia non-unions, an external fixator was used. Fixation is not necessary when the pseudarthrosis has been treated with appropriate osteosynthesis material and this material exhibits no signs of loosening upon clinical or radiological examination. It can be assumed that the healing process is initially accompanied by neovascularization; for this reason, we try to prevent micro movements of the non-union during the first 3-4 weeks after treatment to preclude tearing of the new capillaries. It may be necessary, in some cases, for the patients to avoid full weight bearing on the affected extremity during this period. The Abstracts ISMST

11th International ISMST Congress Juan les Pins 2008 - 37 - patient's cooperation must be elicited by a detailed briefing since most patients are asymptomatic directly after the treatment, owing to the analgesic effects of the shockwaves, and want to put their full weight on the affected extremity again. A pseudarthrosis gap with a width greater than 5 mm shows a poor prognosis. In cases where bony remodeling of the non-union could not be demonstrated after 3 to 6 months, patients were given the option of surgical repair. Numerous patients, especially those who had undergone multiple operations previously, refused this offer. This led to a relatively high number (15.9%) of repeated treatments. In exceptional cases (9), more than two treatments were carried out. The group of patients undergoing repeat ESWT included patients for whom a complicated pseudarthrosis operation was contraindicated for internal reasons or could have been carried out only at considerable risk to the patient.

Results: Osseous union was achieved in 282 (81%) of the pseudarthroses. No complications occurred other than the adverse reactions that have already been observed following shockwave therapy (i.e. local swelling, petechial bleeding and hematoma). Even though the mechanism of action of shockwave therapy has not yet been fully explored, we are convinced that ESWT is an effective, inexpensive and time-saving therapeutic modality with an almost zero rate of complications. Therefore, in Austria, ESWT is considered as the therapy of first choice for non-unions and delayed unions that do not require surgical realignment.

10th IMST Congress in Toronto, Abstract No. 29 and at the 11th ISMST Congress in Juan le Pins, France Abstract No. 40.

Study Performance: **orthowave280c** / **orthogold280**

1.2.25. Extracorporeal Shock Wave Therapy of Nonunion or Delayed Osseous Union (Schaden et al., 2001)

Trauma-Center Meidling, Vienna, Austria.

One hundred fifteen patients with nonunions or delayed fracture healing were treated with high-energy shock waves. After shock wave treatment, immobilization of the fracture also was done. The followup was at least 3 months and as long as 4 years. In 87 patients (75.7%), one treatment with shock waves resulted in bony consolidation with a simultaneous decrease in symptoms. Besides negligible local reactions (swelling, hematomas, petechial hemorrhages), no complications were observed. The treatment was noninvasive, and personnel and technical requirements were not problematic. The authors concluded that the application of extracorporeal shock wave therapy should be the first choice of treatment for patients with nonunions and delayed bone fracture healing.

Study Performance: **orthowave280**

1.3. Orthodontics

1.3.1. Comparative Study Between the Effect of Shockwave Therapy and Low-Intensity Pulsed Ultrasound (LIPUS) on Bone Healing of Mandibular Fractures (Clinical & Radiographic Study) (Ahmed et al., 2022)

Oral and Maxillofacial Surgery Department, Faculty of Dentistry, Alexandria University, Egypt.

Background/Aim: Low-intensity pulsed ultrasound (LIPUS) and extracorporeal shock wave therapy (ESWT) are the different forms of acoustic mechanical waves that might promote bone healing by stimulating bone growth in long or other bones .the aim of this study is to evaluate the effect of



adjuvant LIPUS and ESWT in healing of patients with fresh mandibular fractures. **Subjects and Methods:** this study was a randomized controlled clinical trial, twenty one patients (12 males, 9 females) aged from 20 to 40 years with fresh mandibular fractures treated with closed reduction and maxillary mandibular fixation (MMF) were prospectively enrolled into this study with ethical approval and informed consent. Those patients were randomly assigned in three treatment groups, each of seven patients. Group I received a single treatment with 4000 impulses of focused ESWT, group II received 18 sessions of LIPUS for 20 min while group III received neither represented the control group. Clinical assessment together with radiographic follow-up using cone beam computed tomography (CBCT) at 1.5 and 3 months were done for all patients postoperatively. **Results:** there was statistically significant difference in bone density between three groups in different times after six weeks and after three months as bone density higher in group I (ESWT) than in groups II, III. **Conclusions:** Focused ESWT appeared to be more effective than LIPUS or nothing as an adjuvant treatment of adults with fresh mandibular fractures.

Study Performance: **orthowave180c**

1.3.2. Effect of Extracorporeal Shockwave Therapy (ESWT) on Pulpal Blood Flow After Orthodontic Treatment: a Randomized Clinical Trial (Falkensammer et al., 2016)

Department of Vascular and Endovascular Surgery, Wilhelminenhospital, Vienna, Austria; Sigmund Freud Private University, Medical School, Vienna, Austria.

Objectives: The effect of non-invasive extracorporeal shockwaves on pulpal blood flow in orthodontic patients who have undergone active treatment was investigated.

Materials and methods: Seventy-two adult patients were enrolled in the clinical trial and allocated by block randomization to a treatment or a placebo group at a 1:1 ratio. The patients were required to be otherwise healthy. Blinding was performed for the subjects and the outcome assessor. The region of interest was the mandibular incisors and canines, which were vital, unrestored, and had experienced no trauma. The active treatment group received a single shockwave treatment with 1000 impulses at 0.19-0.23 mJ/mm² while the placebo group was treated with a deactivated shockwave applicator but acoustic sham. Pulpal blood flow was evaluated four times over a period of 6 months starting from the day of bracket removal, using a laser Doppler device.

Results: Thirty patients were evaluated in each group. Orthodontic patients who have undergone active treatment tend to have high levels of pulpal blood flow which decrease over a period of 6 months. Pulpal blood flow did not differ significantly over 6 months between the placebo and treatment group. Shockwave treatment was associated with no significant effect in respect of tooth type, age, sex, or mean blood pressure, and had no unintended pernicious effects.

Conclusions: Extracorporeal shockwaves had no statistically significant effect on pulpal blood flow. Multiple applications of ESWT in a pathological setup may be needed in future studies to demonstrate significant differences.

Clinical relevance: The absence of any adverse effects justifies further principal investigations of the use of shockwave treatment in the oral cavity.

Study Performance: **orthogold100** device with applicator OE050

1.3.3. Impact of Extracorporeal Shockwave Therapy on Tooth Mobility in Adult Orthodontic Patients: a Randomized Single-Center Placebo-Controlled Clinical Trial (Falkensammer et al., 2015)

Department of Orthodontics, University Clinic of Dentistry, Medical University of Vienna, Vienna, Austria.

Aim: This RCT investigated the effect of non-invasive extracorporeal shockwaves on tooth mobility in orthodontic patients after active treatment.

Materials and methods: Seventy-two adult patients were included in the study. Immediately after active orthodontic treatment, patients were assigned to a treatment or a placebo group based on block randomization. The orthodontic patients were required to be otherwise healthy. The region of interest was the anterior portion of the mandible. The treatment group received a single shockwave treatment with 1000 impulses while the placebo group was treated with an acoustic sham. Tooth mobility was evaluated over a period of 6 months using a Periotest and manual testing. Pocket probing depths, bleeding on probing and the irregularity index were also assessed.

Results: Tooth mobility reduced significantly over 6 months in both groups, but shockwaves achieved significantly more rapid reduction on manual testing. Probing depth was significantly reduced while the irregularity index remained stable. Bleeding on probing was significantly reduced in the treatment group. No anti-inflammatory effect could be derived due to possible initial group differences.

Conclusions: The mobility of teeth aligned by orthodontic treatment reduces over time. Shockwave treatment appeared to reduce tooth mobility more rapidly.

Study Performance: **orthogold100** device with applicator OE050

1.3.4. Impact of Extracorporeal Shock Wave Therapy (ESWT) on Orthodontic Tooth Movement - a Randomized Clinical Trial. (Falkensammer, Arnhart, et al., 2014)

Department of Orthodontics, University Clinic of Dentistry, Medical University of Vienna, Vienna, Austria.

Objectives: This randomized clinical trial investigated the effect of extracorporeal shock waves on the amount of orthodontic tooth movement and periodontal parameters.

Material and methods: Twenty-six adult orthodontic patients participated in this clinical trial; all of them receiving lower second molar mesially directed movement. The fixed orthodontic device included superelastic coil springs (200 cN) and miniscrews as temporary anchorage device. The active treatment group received a single shock wave treatment with 1,000 impulses in the region of tooth movement. The placebo group was treated with deactivated shock wave applicator with an acoustic sham. The study period lasted 4 months with a monthly data exploration.

Results: No statistically significant difference in posterior-anterior tooth movement between the treatment and placebo group was seen during observation period. Gender had no significant influence on tooth movement in either group. No significant difference occurred in mesio-distal tipping and rotation, but a significant difference ($p = 0.035$) in bucco-lingual tipping of the molars was found. Periodontal status of the patients (sulcus probing depth, gingival index) did not significantly differ in both groups. The plaque index showed a significant difference ($p = 0.003$).

Conclusions: Single application of extracorporeal shock wave treatment was associated neither with a statistically significant acceleration of tooth movement nor with an altered periodontal status in vivo.

Clinical relevance: Shock waves showed no harmful effects in the investigated area. Their clinical use for lithotripsy during orthodontic therapy might be permitted.

Study Performance: **orthogold100** device with applicator OE050



1.3.5. *Impact of Extracorporeal Shock-Wave Therapy on the Stability of Temporary Anchorage Devices in Adults: a Single-Center, Randomized, Placebo-Controlled Clinical Trial.*
(Falkensammer, Rausch-Fan, et al., 2014)

Department of Orthodontics, University Clinic of Dentistry, Medical University of Vienna, Vienna, Austria.

Introduction: In this randomized, placebo-controlled clinical trial, we investigated the effect of noninvasive extracorporeal shock waves on the stability of temporary anchorage devices (TADs) under orthodontic loading.

Methods: Thirty adult orthodontic patients of the Bernhard Gottlieb University Clinic in Vienna, Austria, were enrolled in this clinical trial and allocated by block randomization (size, 4) in a 1:1 ratio to either the treatment or the placebo group. Randomization was performed with software, and the allocations were concealed in sealed envelopes. Eligibility criteria included healthy adult patients with mesially directed orthodontic movement of the mandibular second molar into the extraction site of the mandibular first molar. The fixed orthodontic devices included active superelastic coil springs (200 cN) and TADs in the mandibular alveolar bone. Blinding was performed for the subjects and the outcome assessor. The treatment group received 1 shock-wave application with 1000 impulses at 0.19 to 0.23 mJ per square millimeter in the region of the TADs. The placebo group was treated with a deactivated shock-wave applicator and acoustic sham. The TADs positions were evaluated at placement and after 4 months. The reliability and precision of the impression process of the TADs were evaluated in an in-vitro model.

Results: Thirteen participants finished the investigation successfully in the treatment group but only 12 finished in the placebo group because 1 TAD loosened. The difference of the total TAD displacement for the 4-month time period between the placebo and treatment groups was 0.17 ± 0.95 mm (95% CI: -0.96, 0.62). No statistically significant difference between the 2 groups was found when sex was evaluated. Primary stability of the TADs as measured by placement torque, amount of tooth movement, and age of the patients did not influence displacement of the TADs. The reliability and precision of TAD impressions were confirmed. No unintended pernicious effects occurred after shock-wave treatment during the study period.

Conclusions: A single application of extracorporeal shock-wave treatment did not improve the stability of the TADs during orthodontic loading. Sufficient interradicular space should be provided to minimize the risk of periodontal and dental root defects.

Study Performance: **orthogold100** device with applicator OE050

2. Dermatology

2.1. Acute Wounds and Burns

2.1.1. *Prospective Randomized Phase II Trial of Accelerated Reepithelialization of Superficial Second-Degree Burn Wounds Using Extracorporeal Shock Wave Therapy* (Ottomann et al., 2012)

Unfallkrankenhaus Berlin, Zentrum für Schwerbrandverletzte mit Plastischer Chirurgie, Berlin, Germany.

Background: As extracorporeal shock wave therapy (ESWT) can enhance healing of skin graft donor sites, this study focused on shock wave effects in burn wounds.

Methods: A predefined cohort of 50 patients (6 with incomplete data or lost to follow-up) with acute second-degree burns from a larger study of 100 patients were randomly assigned between December 2006 and December 2007 to receive standard therapy (burn wound debridement/topical antiseptic therapy) with (n = 22) or without (n = 22) defocused ESWT (100 impulses/cm at 0.1 mJ/mm) applied once to the study burn, after debridement. Randomization sequence was computer-generated, and patients were blinded to treatment allocation. The primary endpoint, time to complete burn wound epithelialization, was determined by independent, blinded-observer. A worst-case scenario was applied to the missing cases to rule out the impact of withdrawal bias.

Results: Patient characteristics across the 2 study groups were balanced ($P > 0.05$) except for older age (53 ± 17 vs. 38 ± 13 years, $P = 0.002$) in the ESWT group. Mean time to complete ($\geq 95\%$) epithelialization (CE) for patients that did and did not undergo ESWT was 9.6 ± 1.7 and 12.5 ± 2.2 days, respectively ($P < 0.0005$). When age (continuous variable) and treatment group (binary) were examined in a linear regression model to control the baseline age imbalance, time to CE, age was not significant ($P = 0.33$) and treatment group retained significance ($P < 0.0005$). Statistical significance ($P = 0.001$) was retained when ESWT cases with missing follow-up were assigned the longest time to CE and when controls with missing follow-up were assigned the shortest time to CE.

Conclusions: In this randomized phase II study, application of a single defocused shock wave treatment to the superficial second-degree burn wound after debridement/topical antiseptic therapy significantly accelerated epithelialization. This finding warrants confirmation in a larger phase III trial.

Study Performance: **dermagold180c**

2.1.2. Prospective Randomized Trial of Accelerated Re-epithelialization of Skin Graft Donor Sites Using Extracorporeal Shock Wave Therapy (Ottomann et al., 2010)

Unfallkrankenhaus Berlin, Zentrum für Schwerbrandverletzte mit Plastischer Chirurgie, Berlin, Germany.

Background: Extracorporeal shock wave therapy may enhance revascularization and repair of healing soft tissue.

Methods: Between January 2006, and September 2007, 28 patients with acute traumatic wounds and burns requiring skin grafting were randomly assigned in a 1:1 fashion to receive standard topical therapy (nonadherent silicone mesh [Mepitel, Mölnlycke Health Care] and antiseptic gel [polyhexanide/octenidine]) to graft donor sites with (n = 13) or without (n = 15) defocused extracorporeal shock wave therapy (ESWT, 100 impulses/cm² at 0.1 mJ/mm²) applied once to the donor site, immediately after skin harvest. The randomization sequence was computer generated, and the patients were blinded to treatment allocation. The primary endpoint was time to complete donor site epithelialization and was determined by an independent blinded observer.

Results: Statistical tests indicated no unbalanced distribution of subject characteristics across the two study groups. Mean times to complete graft donor site epithelialization for patients who did and did not undergo ESWT were 13.9 ± 2.0 days and 16.7 ± 2.0 days, respectively ($p = 0.0001$).

Conclusions: For centers that apply nonadherent gauze dressings and topical antiseptics to skin graft donor sites, application of a single defocused shock wave treatment immediately after skin graft harvest can significantly accelerate donor site epithelialization.

Study Performance: **dermagold180c**

2.1.3. Accelerated Reepithelisation of IIb° Scald Through Extracorporeal Shock Wave Therapy (Ottomann et al., 2009)



Unfallklinik Berlin, Zentrum für Schwerbrandverletzte mit Plastischer Chirurgie, Berlin, Germany.

Based on the observation that, in addition to consolidation of osseous tissue, extracorporeal shock wave therapy (ESWT) effectuates a healing of skin lesions lying in the path of said shock waves, the effect of ESWT on partial thickness (IIa°) thermal lesions was studied by the Centre for Severely Burned Patients with Plastic Surgery at the Unfallklinik in Berlin in conjunction with the International Centre for Extracorporeal Shock Wave Therapy in Berlin. This took place within the framework of a clinical study to demonstrate the effects of extracorporeal shock wave therapy on superficial (IIa°) (IIb°) thermal lesions. Shock waves are small, high pressure sonic pulses and are characterised by a mixture of sound waves with a wide frequency spectrum. The application of shock waves was carried out once during the 24-hour period post trauma. Shock waves with an energy density of 0.1–0.14 mJ/m² using 100 impulses per cm² were applied. We present a case study of a 89 year old female patient with a IIb° scald on her buttock. The ESWT resulted in a complete reepithelisation on day 12 post trauma. Extracorporeal shock wave therapy presents a new complementary method of treatment of thermal lesions that leads to a significantly reduced healing period due to an accelerated rate of reepithelisation.

Study Performance: **dermagold180c**

2.1.4. Accelerated Healing of IIa-Burns Under the Influence of ESWT (Ottomann et al., 2008)

Unfallklinik Berlin, Zentrum für Schwerbrandverletzte mit Plastischer Chirurgie, Warenerstraße 7, 12683 Berlin, Germany.

Introduction: Introduction: Musculoskeletal shockwave therapy increases blood flow in tissues and results in neoangiogenesis. In a study carried out on animals, enhanced tissue regeneration was observed in adipocutaneous flaps. The aim of our conducted clinical study was to demonstrate reduced duration of healing after shockwave therapy on IIa° burn wounds.

Methods: Material and Methods: We carried out a prospective, randomized non-blinded clinical study. Musculoskeletal shockwave therapy was applied within 24 hours post-trauma. Shockwaves with an energy level of 0.1-0.14 mJ/mm² were used. Fifty patients with superficial second-degree thermal lesions (burns and scalds) were selected, twenty-five patients from this group received ESWT treatment, twenty-five patients served as the control group. All participating patients, i.e. patients given ESWT as well as those of the control group, received identical dressings made of perforated silicon layer (Mepitel®) in combination with polyhexanide. Main objective criterion was the time to complete reepithelization, secondary objective criterion was the incidence of side effects.

Results: Results: The group treated with ESWT resulted in a significantly shortened time of reepithelization (minus 2.48 days) compared to the control group. No side effects were observed.

Discussion: The presently available publications discussing the positive effects of ESWT, especially on skin/soft tissue, underscore the results of our own study, in which a highly significant shortened period of reepithelization of skin donor sites via ESWT could be verified. Because ESWT is still in its early stages as a treatment for chronic wounds and skin lesions, the actual mechanism is purely hypothetical.

11th ISMST Congress in Juan le Pins, France Abstract No. 73.

Study Performance: **orthowave180c**

2.2. Chronic Wounds and Ulcers

2.2.1. *Low Intensity Shockwave Treatment Modulates Macrophage Functions Beneficial to Healing Chronic Wounds* (Holsapple et al., 2021)

School of Medicine, Medical Sciences & Dentistry, Institute of Medical Sciences, University of Aberdeen, Foresterhill Road, Aberdeen AB25 2ZD, UK.

Department of Vascular Surgery, NHS Grampian, Foresterhill Road, Aberdeen AB25 2ZN, UK.

Extracorporeal Shock Wave Therapy (ESWT) is used clinically in various disorders including chronic wounds for its pro-angiogenic, proliferative, and anti-inflammatory effects. However, the underlying cellular and molecular mechanisms driving therapeutic effects are not well characterized. Macrophages play a key role in all aspects of healing and their dysfunction results in failure to resolve chronic wounds. We investigated the role of ESWT on macrophage activity in chronic wound punch biopsies from patients with non-healing venous ulcers prior to, and two weeks post-ESWT, and in macrophage cultures treated with clinical shockwave intensities (150-500 impulses, 5 Hz, 0.1 mJ/mm²). Using wound area measurements and histological/immunohistochemical analysis of wound biopsies, we show ESWT enhanced healing of chronic ulcers associated with improved wound angiogenesis (CD31 staining), significantly decreased CD68-positive macrophages per biopsy area and generally increased macrophage activation. Shockwave treatment of macrophages in culture significantly boosted uptake of apoptotic cells, healing-associated cytokine and growth factor gene expressions and modulated macrophage morphology suggestive of macrophage activation, all of which contribute to wound resolution. Macrophage ERK activity was enhanced, suggesting one mechanotransduction pathway driving events. Collectively, these in vitro and in vivo findings reveal shockwaves as important regulators of macrophage functions linked with wound healing. This immunomodulation represents an underappreciated role of clinically applied shockwaves, which could be exploited for other macrophage-mediated disorders.

Study Performance: **dermagold100**

2.2.2. *Extracorporeal Shock Wave Therapy (Eswt) For the Treatment of Chronic, Non-Healing Wounds_A Case Series* (Marcus, 2020)

Center for Vascular Intervention (CVI), Atlanta, GA.

Objective: Extracorporeal shock wave therapy (ESWT) is a non-invasive therapy that involves generating shock waves (transient pressure disturbances that propagate rapidly in 3-dimensional space) outside the body and transmitting the acoustic energy inside the body to induce therapeutic effects. This case series examines the effectiveness of ESWT in treating chronic wounds of varying etiologies.

Method: In this retrospective case series, ESWT was applied to chronic, non-healing wounds. Patients were treated at a single center between December 2019 and March 2020. The criterion for application of ESWT was lack of progress toward wound healing despite standard treatments.

Results: We assessed six patients aged between 52 to 81 years old. Two patients had surgical wounds, three patients had leg ulcers of various etiologies, and one had a diabetic foot ulcer (DFU). All patients experienced progressive healing over multiple ESWT sessions. All six patients experienced complete wound closure following six to eleven applications of ESWT applied approximately once a week.

Conclusion: This series presents the effective use of ESWT in the treatment of chronic wounds of various etiologies.



Study Performance: **dermagold100**

2.2.3. The Role of Extracorporeal Shock Wave Therapy and Manual Lymphatic Drainage in Chronic Ulcers Treatment (Saggini et al., 2016)

Physical and Rehabilitation Medicine, Department of Medical Oral and Biotechnological Sciences, Director of the School of Specialty in Physical and Rehabilitation Medicine, "Gabriele d'Annunzio" University, Chieti, Pescara, Italy National Coordinator of Schools of Specialty in Physical and Rehabilitation Medicine.

Introduction: Chronic wounds are a major, functionally-limiting medical problem impairing quality of life for millions of people each year. Extracorporeal shock wave therapy (ESWT) may accelerate and improve wound repair. Some authors investigated the optimal session number of ESWT in rat models.

Aim: Purpose of this study was to verify the effectiveness of two temporal modalities of ESWT administration in chronic ulcers.

Materials and methods: 84 subjects with chronic ulcers were enrolled. They were divided into 2 groups according to the absence or presence of associated lymphedema. Each group was divided with a stratified randomization into two subgroups receiving the same total energy of ESWT (2640 Mj) but with different temporal modality during the week.

Results: Our results show, at the end of the 5 weeks treatment, a statistically significant reduction of wounds area and pain in the groups which received the ESWT fractioned in 2 weekly steps (2 x 1320 Mj) and reduction of limb circumference in subjects with lymphedema.

Discussion: By fractioning energy in 2 weekly steps probably there is greater regenerative activation. This type of application cannot be generalized, it could be a best choice in diabetic ulcers, even in the presence of lymphedema. The knowledge relative to the efficacy of ESWT in treatment of chronic wounds has had over the years a consolidation process, instead the modulation of time treatment can be considered as a new border for clinical studies.

Study Performance: **dermagold100**

2.2.4. 10-Year Experience in the Treatment of Sub-Acute and chronic Wounds with Extracorporeal Shockwave Therapy in the Trauma Center Meidling, Vienna, Austria (Dahm et al., 2015)

AUVA Trauma Center Meidling, Vienna, Austria. Ludwig Boltzmann Institute for Experimental and Clinical Traumatology – AUVA Research Center, Vienna, Austria. Austrian Cluster for Tissue Regeneration, Vienna, Austria.

Introduction:

There is accumulating evidence showing clinical efficacy of extracorporeal shockwave therapy in the management of chronic and delayed healing wounds. In August 2004 we initiated an open clinical study in the AUVA Trauma center Meidling, Vienna, Austria intending to treat patients with such non-healing wounds of different etiologies. During the past 10 years of ESWT in this indication we could show the great potential and efficacy of this non-invasive treatment modality.

Methods:

Patients with chronic or delayed healing wounds are recruited during routine clinical work or are referred to our hospital specifically dedicated to ESWT. Between August 2004 and December 2014 patients of both sexes with soft tissue wounds of different etiology persistent longer than 1 month (mean: 74.7 days \pm SD: 182) were included. The primary outcome measure was rate of wound closure.

Results:

Until December 2014, 824 patients could be included in the analyses which were treated with unfocused extracorporeal shock waves (male: 59%, female: 41%). Mean age was 57.58 years \pm 20.05 (SD). Wound distribution concentrated on the lower extremity 79.9%) followed by the upper extremity (16.4%). In the analyzed cohort posttraumatic wounds were treated most frequently (81%). However, irrespective of etiology, we achieved complete healing in 72% of the wounds treated with defocused ESWT (0.1 mJ/mm², 3 to 5 Hz) which is comparable with the results of 2014. On average complete healing was seen after 47 days (mean \pm 45 SD) following the first ESWT receiving 3 \pm 2 treatments (mean \pm SD; min-1 and max-11).

Discussion:

During the last 10 years of treating chronic and sub-acute wounds of different etiology with extracorporeal shockwaves we could show consistently excellent results. The healing outcome seems to be independent of the treating interval therefore treatment intervals of 2 and 3 weeks are recommended. Interestingly, patients suffering from non-healing wounds with diabetes in the medical history respond as good as wounds in patients without diabetes.

18th ISMST Congress in Mendoza, Argentina. Abstract No. 28.

Study Performance: **DermaGold180c**

2.2.5.Effectiveness of Extracorporeal Shock Wave Lithotripsy to Treat Dystrophic Calcinosis Cutis Ulcers (Delgado-Márquez et al., 2015)

Departamento de Dermatología, Hospital 12 de Octubre, Madrid, España.

We report the case of a 78-year-old woman with a history of hypertension, deep vein thrombosis, valvular heart disease treated with coumarin, osteoporosis, and overlap syndrome. In addition, she had diagnostic findings consistent with systemic lupus erythematosus (pleuropericarditis, lupus erythematosus panniculitis, subacute cutaneous lupus erythematosus, malar rash, oral ulcers, arthritis, leukopenia and thrombocytopenia, meningitis, and positive tests for antinuclear antibodies and antiribonucleoprotein antibodies) as well as with scleroderma (sclerodactyly, severe Raynaud syndrome, esophageal disease, interstitial pulmonary disease, and a positive test for anticentromere antibodies). The patient presented to our dermatology service in 2002 because of bouts of erythema and pain in her right leg. Biopsy findings at that time were reported as consistent with lupus erythematosus panniculitis and dermal sclerosis...

... To our knowledge, ours is the first case of an ulcer caused by dystrophic calcification and treated using unfocused shock waves, with excellent results. We wish to highlight the effectiveness of this treatment in terms of pain reduction and epithelialization, and underscore its ease of application, safety, and tolerability.

Study Performance: **dermagold100**

2.2.6.Influence of Treatment Frequency on Healing Outcome in Subacute and Chronic Wounds (Mittermayr et al., 2014)

AUVA Trauma Center Meidling, Vienna, Austria. Ludwig Boltzmann Institute for Experimental and Clinical Traumatology – AUVA Research Center, Vienna, Austria. Austrian Cluster for Tissue Regeneration, Vienna, Austria.



Introduction: We could show in our open prospective study in the retrospective data analysis that extracorporeal shock wave therapy has great potential in the treatment of delayed or non-healing wounds. Detection of differences in outcome based on the treatment frequency has major impact in adequately planning therapy sessions.

Methods: In our open study patient study enrollment is done during routine clinical work. Between August 2004 and April 2014 patients of both sexes with sub-acute and chronic soft tissue wounds of different etiology were included. The primary outcome measure was complete wound healing based on treatment frequency.

Results: Until April 2014 we already included 850 patients. 661 patients were analyzed with respect to ESWT frequency. Similar as previously found we could not detect differences in healing outcome when wounds were treated with extracorporeal shockwaves weekly (n=176), every 2 (n=183) or every 3 (n=37) weeks. (complete healing in 74, 73, and 76%, respectively). However, applying shockwaves only every 4 weeks complete healing was only observed in 69% of the patients (n=30). Interestingly, these lower number encounters not to more frequently not healed wounds but rather to patients missing follow up (20% in comparison to 9% (weekly) 14% (every 2 weeks), and 11% (every 3 weeks).

Conclusion: In the open clinical trial performed in the trauma Center Meidling since 2004 we could show consistently excellent results in treating sub-acute and chronic wounds with ESWT without observing any clinically relevant adverse effects. Due to comparable high percentage of missing patients in the follow up period then shock waves were applied only every 4 weeks, ESWT repetition within 3 weeks is recommended.

17th ISMST Congress in Milano, Italy. Abstract No. 62.

Study Performance: **dermagold100**

2.2.7. Shockwave Medicine and Leprosy - The Ultimate Challenge for Skin Regeneration by Mechanotransduction (Leal et al., 2014)

Fenway Medical Shockwave Medicine Center Unit, Bogota DC, Colombia

Introduction: Leprosy, also known as Hansen's disease, is one of the oldest chronic infectious conditions known to mankind. It is caused by the Mycobacterium Leprae, a germ that attacks primarily the peripheral nerve system and may remain asymptomatic for years. The presence of skin granulomas, limb amputations, face and eye deformities have caused the largest historical social stigma in the world. The main problem of these patients, apart from the social stigma, is the presence of plantar perforating ulcers. These are chronic deep ulcerations of the anesthetic sole of the foot that are usually resistant to all treatments local or systemic. Plantar anesthesia, unprotective walking and poor quality of scars make these lesions usually recurrent. Unfocused Extracorporeal Shockwave Treatments (ESWT) has become a proven therapeutic tool in the treatment of diabetic foot. These patients suffer from similar chronic ulcers with a neuropathic, hypovascular, hyporegenerative infectious background, and has shown excellent results in the past decade. We hypothesize that the use of ESWT may have a similar result as in diabetic foot, improving plantar ulcer healing in patients with Leprosy.

Methods: We performed a blinded randomized clinical case control trial in forty patients with diagnosed Hansen's disease from the Sanatorio de Agua de Dios in Cundinamarca, Colombia. In order to standardize the outcomes, patients with plantar ulcers under 10mm² were chosen from the Hospital's database. Patients were randomized in two groups of 20. All patients were non-reactive, and had previously completed more than one year of multidrug anti-leprosy therapy. All were informed of this experimental trial, of possible results and complications, and signed an informed

consent. The ethics committee of the Sanatorio de Agua de Dios approved the study. The cases group received four sessions of unfocused electrohydraulic shockwaves at a bi-weekly interval. We used the ISMST approved protocol, applying 350 shockwaves x 10 times the size of the ulcer in square mm on each session, with a certified unfocused electrohydraulic ESWT device (Dermagold 100 – MTS Germany). Both the cases and the control groups received the exact same regular treatment according to the Hospital Protocol, with wound lavage, debridement and local agents. All patients were evaluated by direct ulcer measurement in width and length, and a digital photography record was performed. The ulcers were described and recorded by our plastic surgeon. Patients were followed up and photographed every two weeks during treatment, and then at 3, 4 and 6 months. The digital photographs of the ulcers of cases and controls were measured at the end of the study by three blinded MD's who did not know if the patients were treated or not with ESWT. The clinical measurements were analyzed separately from the photographic measurements. We considered excellent results in a complete wound closure, good if healing was over 50% of the original size, fair if under 50% and poor if no change or increase in size was documented. We also measured subjectively the depth of the wound as deep or superficial if the edges of the ulcer were lower or higher than 3 mm. Any adverse effects were recorded. The study was done independently with no financial or material support from the manufacturers of ESWT devices or implants.

Results: We were able to follow up for six months a total of 16 cases and 15 controls, and there were no significant differences between the two groups in terms of demographics and clinical data. All ulcers under 1 mm² were excluded from the ESWT and control groups by the data analysis team. The average wound size in the ESWT group was 587mm² and the control group was 596mm². The proportions of ulcers that healed in six months in the ESWT and control groups were 63% and 12%, respectively. We had a complete closure in 6/16 patients of the ESWT group, and 1/15 patients with complete closure in the control group. Out of the patients with complete wound closure in the ESWT group, 34% healed after one month, 16% after two months and 50% after four months. The only patient with complete wound closure in the control group healed after 3 months. In the ESWT group we had 75% of good or excellent results after six months, while in the control group we had 20%. The depth of the ulcers, the aspect and vascularity of the wounds improved from deep to superficial in 65% of the ESWT group and 12% in the control group. All these results were statistically significant ($p > 0.05$). Subjectively, patients in the ESWT group reported increased sensitivity in the treated area, and pain control in the adjacent areas. Fluid wound drainage also decreased in the ESWT group, as reported by patients and nursing personnel. All patients reported the treatment as satisfactory in the ESWT group. We did not have any adverse effects or complications in either group.

Conclusion: The use of shockwave therapy in the treatment of chronic plantar ulcers in Leprosy patients showed excellent results in this case-controlled blinded RCT. There is a clear evidence of a positive influence of mechanotransduction stimulation in improving healing of these very complicated skin conditions. Some patients have these ulcers for more than 15 years and were surprised that finally something worked for them. Our results are very encouraging, especially this being the first study of ESWT for Leprosy patients. We found that the use of unfocused electrohydraulic ESWT improved significantly wound closure in chronic leprosy patients, with 51% better results than in controls. This was the only single different intervention in the treatment group. We did find also an improvement in wound drainage and the depth of the ulcers. Pain also improved in most of the patients. We believe that leprosy ulcers may need a larger number of sessions, as they are deeper than diabetic ulcers. All patients with ulcers under 1 mm² healed in the ESWT and control groups and were excluded from the study. We also treated 6 patients with larger ulcers and the results were similar. We expect to continue this research line with larger ulcers and in more patients. The general perception in our patients and the Agua de Dios community was extremely favorable, generating a social wave of demands for ESWT



treatments. With this statistically solid results and subjective data, we are optimistic in being able to offer a non-invasive option with shockwave medicine for a large and suffered population of the world.

17th ISMST Congress in Milano, Italy.

Study Performance: **dermagold100** with applicator OP155

2.2.8. The Role of ESWT and Manual Lymphatic Drainage in the Treatment of Grade II Chronic Ulcers (Saggini et al., 2014)

"G. d'Annunzio" University, Chieti, Italy.

Introduction: The purpose of this study was to verify the effectiveness of two temporal modalities of ESWT administration in chronic ulcers and compare them to each other and to the combined therapy with manual lymphatic drainage in presence of Lymphedema.

Methods: 28 patients with stage II chronic ulcers were evaluated and treated. They were divided into 2 groups (A and B) of 14 subjects according to the absence or presence of associated lymphedema. Each group was then randomly divided into two subgroups (A-I, A-II, B-I, B-II) who made ESWT at different weekly frequency; subjects with lymphedema also underwent manual lymphatic drainage.

Results: At the end of the 5 weeks treatment (T1) we found: In group A-I reduction of wound dimensions from 1.87 (T0) to 0.77; reduction of the subjective pain from 5,7 (T0) to 1.8. In group A-II reduction of wound dimensions from 1.69 (T0) to 0.45; reduction of the subjective pain from 5,1 (T0) to 0.5. In group B-I reduction of wound dimensions from 2.83 (T0) to 1.88; reduction of the subjective pain from 5,5 (T0) to 2.9. In group B-II reduction of wound dimensions from 2.71 (T0) to 1.54; reduction of the subjective pain from 5,3 (T0) to 2.3.

Discussion: We found a significative reduction of wound dimension and subjective pain in all groups ($p < 0.05$). In terms of absolute value, the best results were found in group A-II and B-II, who performed the treatment with ESWT twice a week and 500 pulses per session also even using the lymphaptic drainage.

Conclusion: Our results show that it is preferable to administer ESWT in chronic ulcers with fractionated energy in 2 weekly steps; probably in this way there is greater regenerative activation. The results obtained in subjects with lymphedema, where the presence of edema represents a delay element for healing, can encourage us in confirming that the healing process is based on angiogenesis, that is very important to promote drainage, but above all to confirm that shock waves are crucial in reactivating and accelerating the healing process of chronic wounds.

17th ISMST Congress in Milano, Italy. Abstract no. 60.

Study Performance: **dermagold100**

2.2.9. Chronic Ulcers: Treatment with Unfocused Extracorporeal Shock Waves (Saggini et al., 2013)

Physical and Rehabilitation Medicine, Department of Medical Oral and Biotechnological Sciences, Director of the School of Specialty in Physical and Rehabilitation Medicine, "Gabriele d'Annunzio" University, Chieti, Pescara, Italy National Coordinator of Schools of Specialty in Physical and Rehabilitation Medicine.

The aim of this study was to evaluate the efficacy of the treatment of chronic ulcers with unfocused shock waves. Between March 2009 and February 2012, we studied a group of 124 patients, aged

between 28 and 80 years, with serious wounds arisen over three months and who met the inclusion criteria for treatment. The patients were randomly divided into groups A and B, both treated with unfocused ESWT but with an average energy density for each impulse equal to 0.10 mJ/mm² in group A (total energy equal to 1.7 mJ for each shot) and an average energy density for each impulse equal to 0.04 mJ/mm² in group B (total energy equal to 3.3 mJ for each shot). The pulses were administered at a frequency of 4 Hz in both groups. Wounds were classified according to: location, width, length, percentage of granulation tissue, necrotic tissue, fibrous tissue, presence of bacterial exudation and pain (assessed by VAS). Their evolution was monitored by photo capture. The patients were treated with a frequency of 1 session every 7 days for 7 weeks. During the treatment period, the possible occurrence of side effects was monitored. Before treatment the wounds in group A had an average area equal to 3.85 cm² and the average value of the VAS pain scale was equal to 5.8 (range 2–9); the wounds in group B had an average area equal to 3.4 cm² and the average value of the VAS pain scale was equal to 5.7 (range 3–9). At the end of the treatment protocol the mean area in group A decreased by 80% (final mean area 0.93 cm²), and the average pain on VAS scale dropped by 79%; the mean area in group B decreased by 67% (final mean area 1.2 cm²) and the average score on VAS scale dropped by 48%. None of the treated patients experienced adverse reactions to treatment. None of the treated wounds developed infection during treatment. In conclusion, shock waves can act on difficult wounds, stimulating the reparative physiological process; therefore, it represents an effective and safe procedure to accelerate the healing process, reducing the operating costs and avoiding more complex interventions.

Study Performance: **dermagold100**

2.2.10. Shock Wave Therapy for Systemic Sclerosis (Belloli et al., 2013)

Rheumatology Unit, Department of Traslational Medicine, IRCCS Istituto Clinico Humanitas, University of Milan, Via Manzoni 56, 20089, Rozzano, Milan, Italy.

We studied the effects of ESWT in 8 SSc female patients who received 4 consecutive ESWT sessions (Dermagold– MTS Germany defocused lithotripter device, 10.000 shots/ session applied at the energy level of 0.06 mJ/mm², frequency of 5 Hz), weekly applied to both hands and to one forearm, keeping the contralateral forearm as control.

... In conclusion, ESWT might represent a non-invasive, effective and safe strategy for ischemic conditions, including SSc. However, more studies are needed to further clarify the underlying mechanisms, since other systems than the complex interaction between endothelium, VEGF and angiogenesis may be involved.

Study Performance: **dermagold100**

2.2.11. Unfocused Shockwave Treatment of Skin injuries (Rerez Gomez et al., 2012)

Unitron, Valencia, Carabobo, Venezuela.

Introduction: Skin ulcers and vicious scars are produced by means of fibrotic and inflammatory changes of the dermis, and a mix of fibrous outskirts and thrombosis of small and superficial blood vessels, that cause ischemia. Extracorporeal Shockwave Treatments (ESWT) have been recently used for chronic skin injuries, based on the principles of the good results in managing different Musculoskeletal conditions. ESWT produces analgesia, anti-inflammatory effects, increase of vascularization, angiogenesis activation, and osteogenesis. Our objective was to determine the efficacy of shock waves for medical use in the treatment of chronic skin lesions.



Methods: We performed a prospective case series study that included 7 patients with chronic skin injuries of skin that received treatment with unfocused ESWT. We used an unfocused applicator with an electrohydraulic generator. (Dermagold100 - MTS). We used a protocol with 350 + 100 shockwaves/cm², with an intensity of 0.01 to 0.03 mJ/mm². We measured skin closure with a ruler and caliper. 28.5% of our patients had injuries of 2-3 cm². 14.2%, injuries were of 3.1-4 cm², and 57%, injuries were bigger than 4.1 cm². 42.8% of our patients had diagnosed diabetes mellitus, 14,4%, varicose syndrome, 14,4%, lower limb palsy, 14.4%, rheumatoid arthritis, and 14.4% had no previous medical issue.

Results: The recovery of our patients was good or excellent in 85.7%. Only one patient in our seven cases series did not show skin lesion healing. This was a ten-year-old skin ulcer. Only 14.4% of our cases showed wound closure after one session. We had no complications during the study period.

Conclusion: In our case series we found encouraging results that have also been observed in previous studies and reports in the literature. ESWT showed effectiveness in the treatment of our patients in over 85% of the cases, reducing healing time and improving wound closure with no complications. Further studies must be performed, as this pilot trial shows excellent findings similar to other published experiences.

15th ISMST Congress in Cartagena, Colombia. Abstract No. P30.

Study Performance: **dermagold100**

2.2.12. Defocused ESWT for Chronic Skin Lesions – Treatment Interval Does Not Seem to Influence Healing Outcome (Mittermayr et al., 2011)

AUVA Trauma Center Meidling, Vienna, Austria. Ludwig Boltzmann Institute for Experimental and Clinical Traumatology – AUVA Research Center, Vienna, Austria.

Introduction: Chronic or delayed healing wounds are a significant burden to both the healthcare system and the patient, often requiring protracted, intensive and quality-of-life-altering treatment. Due to multiple factors (e.g. longer life span, higher rate of co-morbidities such as diabetes) the incidence of chronic wounds is increasing worldwide. We show in our open study that extracorporeal Shockwave Therapy has great potential in the treatment of non-healing wounds. Additionally, different treatment intervals were tested and results are presented.

Methods: In our open study patient enrolment is done during routine clinical work. Between August 2004 and April 2011 patients of both sexes with soft tissue wounds of different etiology persistent longer than 1 month were included. The primary outcome measure was rate of wound closure. Secondly, the different treatment intervals (1, 2, and 3 weeks) were analyzed and compared.

Results: As of April 2011, 590 patients were treated with unfocused extracorporeal shock waves (male: 59%, female: 41%) and were included in this analysis. Mean age was 57.3 years ± 21.1(SD). Wounds of the lower extremities were treated most often followed by the upper extremities. In total 70% of the wounds treated with defocused ESWT healed completely (2010: 71%). Wounds unresponsive to ESWT were observed in 8% of treated patients which was minimally higher than in 2010 (6%). The percentage of patients who were lost to follow-up was 17%, a slight increase compared to 2010 (16%). Wounds which received only one treatment (191 patients) completely healed in 64% of patients. In this subgroup we experienced the highest rate of patients who were lost to follow-up (26%). Wounds which did not heal after 1 treatment were observed in 7% of patients. The main reasons for discontinuing ESWT in the wounds which did not heal after 1 session were: treatment in other hospitals; surgery; and patient refusal (in 3 cases). All other patients had 2 or more (maximum 11) treatments. Wounds treated in one-week interval completely healed in 74% of patients. Similar results were found in

patients which received ESWT every two weeks (72% completely healed) and every three weeks (69% completely healed). No substantial differences were observed in the number of patients who were lost to follow-up (around 12%) or in wounds unresponsive to ESWT (around 10%).

Conclusion: In our open study at Trauma Center Meidling we show consistently excellent results in treating sub-acute and chronic wounds with ESWT. The healing outcome seems to be independent of the treatment interval. Furthermore, the different intervals do not seem to have an influence on patient compliance.

14th ISMST Congress in Kiel, Germany. Abstract No. 39.

Study Performance: **DermaGold100**

2.2.13. *The Influence of Comorbidities and Etiologies on the Success of Extracorporeal Shock Wave Therapy for Chronic Soft Tissue Wounds: Midterm Results* (Wolff et al., 2011)

Department of Surgery, Austrian Armed Forces Hospital-Vienna, Vienna, Austria.

Possible effects of comorbidities and of different wound etiologies on the success of extracorporeal shock wave therapy (ESWT) of chronic soft tissue wounds were investigated. From September 2003 until February 2007, 282 patients, being previously treated unsuccessfully were enrolled. Treatment consisted of ESWT occurring at defined intervals. At each treatment session a wound bed score was recorded, also at initial presentation a detailed patient history and wound etiology. Observed comorbidities were pooled according to the chapters of the ICD-10 system. Two hundred fifty-eight patients were analyzed (91.49%) and underwent follow-up for a median of 31.8 months. Wound closure occurred in 191 patients (74.03%) by a median of two treatment sessions. No wound reappeared at the same location. A multivariate logistic regression model showed that pooled comorbidities and wound etiologies did not have a significant influence on success. Comorbidities and wound etiologies have surprisingly no significant influence on the success of ESWT.

Study Performance: **orthowave180c**

2.2.14. *Prospective Trials of ESWT for Soft Tissue Indications* (Stojadinovic et al., 2011)

Combat Wound Initiative Program, Walter Reed Army Medical Center, Washington, D.C.; Unfallkrankenhaus Berlin, Zentrum für Schwerbrandverletzte mit Plastischer Chirurgie, Berlin, Germany; Internationales Zentrum für Stosswellentherapie, Berlin, Germany; Boston Biostatistics Research Foundation, Framingham, MA; AUVA-Trauma Center Meidling, Vienna, Austria.

Introduction: The collaborative, multi-disciplinary Combat Wound Initiative (CWI) Program has partnered with leaders in wound care and research to provide state-of-the-art, complex wound care through targeted clinical and translational research, incorporating advanced technology and treatment, tissue banking, and bioinformatics. The CWI has advanced prospective non-randomized and prospective randomized trials (PRT) testing extracorporeal Shockwave Therapy (ESWT) for soft tissue indications to provide evidence basis to further advance wound care.

Methods: The CWI has partnered with leaders in the field of ESWT to conduct three clinical trials: (1) prospective single arm trial testing feasibility and safety of low-energy, defocused ESWT for complex, non-healing, soft-tissue wounds – 208 patients treated with wound debridement, outpatient ESWT [100-1000 pulses/cm² at 0.1 mJ/mm², q 1-2 wks. over mean 3 treatments], and moist dressings; (2) PRT comparing standard topical therapy alone (non-adherent silicone mesh and antiseptic gel, n=15)



to standard therapy with ESWT (100 pulses/cm² at 0.1 mJ/mm², applied once to the donor site, immediately after skin harvest; n=13) to split thickness skin graft (STSG) donor site; (3) PRT comparing standard topical therapy alone (as above, n=22) to standard therapy with ESWT (100 impulses/cm² at 0.1 mJ/mm², applied once to the burn wound, immediately after debridement, n=22) to superficial 2nd degree, IIa° burns.

Results: (1) complete wound epithelialization occurred in 75% of patients during mean follow-up period of 44 d; there was no ESWT-related toxicity, infection, or wound deterioration; (2) mean healing time was significantly more rapid in ESW-treated STSG donor sites than those treated with standard therapy alone (14 ± 2 vs. 17 ± 2 days, $p = 0.0001$); (3) in patients with superficial 2nd degree, IIa° burns, mean time to complete epithelialization was significantly accelerated in the ESW-treated group (10 ± 2 and 13 ± 2 days).

Discussion: Low-energy, defocused ESWT is a safe and effective adjunct to standard therapy for accelerating skin graft donor site and superficial second degree burn re-epithelialization.

Conclusion: Extracorporeal Shockwave Therapy is a feasible, safe and effective method to enhance the healing of both split thickness skin graft donor sites and superficial 2nd degree (IIa°) burns.

14th ISMST Congress in Kiel, Germany. Abstract No. 42.

Study Performance: OW180c **DermaGold100**

2.2.15. *Combat Wound Initiative Program* (Stojadinovic et al., 2010)

Walter Reed Army Medical Center, Department of Surgery, 6900 Georgia Avenue NW, Washington, DC 20307, USA.

The Combat Wound Initiative (CWI) program is a collaborative, multidisciplinary, and interservice public-private partnership that provides personalized, state-of-the-art, and complex wound care via targeted clinical and translational research. The CWI uses a bench-to-bedside approach to translational research, including the rapid development of a human extracorporeal shock wave therapy (ESWT) study in complex wounds after establishing the potential efficacy, biologic mechanisms, and safety of this treatment modality in a murine model. Additional clinical trials include the prospective use of clinical data, serum and wound biomarkers, and wound gene expression profiles to predict wound healing/failure and additional clinical patient outcomes following combat-related trauma. These clinical research data are analyzed using machine-based learning algorithms to develop predictive treatment models to guide clinical decision-making. Future CWI directions include additional clinical trials and study centers and the refinement and deployment of our genetically driven, personalized medicine initiative to provide patient-specific care across multiple medical disciplines, with an emphasis on combat casualty care.

Study Performance: **dermagold100**

2.2.16. *Randomized Control of Extracorporeal Shock Wave Therapy Versus Placebo for Chronic Decubitus ulceration* (Larking et al., 2010)

Institute of Neuropalliative Rehabilitation, Royal Hospital for Neuro-disability, West Hill, Putney, London, UK.

Objective: To assess whether extracorporeal shock wave therapy increases the rate of healing in chronic decubitus ulceration.

Design: Double-blind randomized cross-over study.

Setting: A large, long-stay hospital specializing in the management of people with complex neurological disabilities.

Subjects: The total population of available patients with chronic neurological conditions and chronic decubitus ulceration who met the inclusion criteria.

Interventions: Ulcers were randomized into receiving either the extracorporeal shock wave therapy or the placebo for a four-week period, followed by a two-week 'washout' period followed by a four-week period of the cross-over treatment/ placebo.

Main measures: Measurement of the area of the ulceration. For each observation the average of three measurements were taken.

Results: Nine ulcers (in eight patients) were included in the study: five on the buttocks/sacrum/trochanter and four on the feet/ankles. All those with static chronic ulcers showed improved healing starting 6-8 weeks after the start of extracorporeal shock wave therapy, whether treated first with the placebo or the therapy.

Conclusions: Extracorporeal shock wave therapy has a potential part to play in the treatment of chronic skin ulceration.

Study Performance: **orthowave180c**

2.2.17. *Extracorporeal Shockwave Treatment for Chronic Diabetic Foot Ulcers* (Wang et al., 2009)

Kaohsiung Medical University, Taiwan.

Background: This prospective study compared extracorporeal shockwave treatment (ESWT) with hyperbaric oxygen therapy (HBO) in chronic diabetic foot ulcers.

Patients and methods: Seventy-two patients with 72 chronic diabetic foot ulcers were randomly divided into two groups of similar demographics with 34 patients with 36 ulcers in the ESWT group and 36 patients with 36 ulcers in the HBO group. Patients in the ESWT group received 300 + 100/cm² impulses of shockwave at 0.11 mJ/cm (2) energy flux density every 2 wk for 6 wk, whereas patients in the HBO group received HBO daily for 20 treatments. The evaluations included clinical assessment of the ulcers with photo-documentation, blood flow perfusion scan, bacteriological examination, histological study, and immunohistochemical analysis.

Results: The overall results showed completely healed in 31%, improved in 58%, and unchanged in 11% for the ESWT group and 22% completely healed, 50% improved, and 28% unchanged for the HBO group. The ESWT group showed significantly better clinical results and local blood flow perfusion, higher cell concentration, and activity than the HBO group. On immunohistochemical analysis, the ESWT group demonstrated significant increases in endothelial nitric oxide synthase, vessel endothelial growth factor, and proliferation cell nuclear antigen expressions and a decrease in transference-mediated digoxigenin-deoxy-UTP nick end-labeling expression than the HBO group.

Conclusions: ESWT appears to be more effective than HBO in chronic diabetic foot ulcers.

Study Performance: **orthowave180**

2.2.18. *Summation of the Experiences Using Defocused ESWT for Chronic Lesions in the Trauma Center Meidling* (Mittermayr et al., 2009)

AUVA Trauma Center Meidling, Vienna, Austria. Ludwig Boltzmann Institute for Experimental and Clinical Traumatology – AUVA Research Center, Vienna, Austria.



Introduction: Treating complicated soft tissue wound conditions (delayed/non-healing wounds) is extremely challenging but extracorporeal shock wave therapy seems to have great potential in this field. We present the annual, almost traditional, update from our clinical ESWT experience between 2004 and 2008.

Methods: Patient study enrollment was done during routine clinical work between August 2004 and December 2008. Patients of both sexes with soft tissue wounds of different etiology persistent longer than 1 month were included. The primary outcome measure was rate of wound closure. Secondly, different correlation analyses (e.g. defect size, age, etiology) were performed.

Results: Through December 2008, 390 patients were treated with unfocused extracorporeal shock waves (male: 57%, female: 43%), primarily in an outpatient clinical setting. Mean age was 57.8 ± 20.2 (2008: 50.4 ± 18.0) in males and 61.6 ± 19.2 (2008: 71.7 ± 16.2) in females. As found in the analysis of 2008, the main wound location was the lower extremities (lower leg: 44.6%; foot: 13.9%) followed by the upper extremities. Patients who were treated due to wound healing disturbances (39.5%) and posttraumatic necrosis (31.3%) were most common, as they were last year, but percentages showed a slight increase over last year. In total 72% of the wounds treated with ESWT healed completely (2008: 69%). We were also able to see a slight decrease in non-respondent wounds (5.3% in 2009 vs. 5.9% in 2008). Fortunately, the percentage of patients who missed follow-up also decreased to 15.4% (23.7% in 2008). The mean of ESWT sessions was 2.9 times with a range from 1 to 15 sessions in total. The mean of total amount of applied pulses was 1,483 (range from 100 to 44,700). The healing time for wounds successfully treated with ESWT was a mean of 43.8 days (± 45). In recent analysis a correlation was found between greater wound size and non-healing wounds, as was found in 2008. Again, a correlation was also found between age and therapy responsiveness. The older the patient, the worse the prognosis of outcome with ESWT. First experiences (long term follow-up) with wounds which are healed in response to ESWT show smooth, good relocatable scars. In addition, in treating hypertrophic, algetic scars with shock waves we observed scar reduction concomitant with quality improvement and patient report of pain reduction.

12th ISMST Congress in Sorrento, Italy. Abstract No. 67.

Study Performance: **DermaGold100** Activator

2.2.19. Prophylactic Low-Energy Shock Wave Therapy Improves Wound Healing After Vein Harvesting for Coronary Artery Bypass Graft Surgery: A Prospective, Randomized Trial (Dumfarth et al., 2008)

Department of Cardiothoracic Surgery, Medical University of Vienna, Austria.

Background: Wound healing disorders after vein harvesting for coronary artery bypass graft surgery increase morbidity and lower patient satisfaction. Low-energy shock wave therapy (SWT) reportedly improves healing of diabetic and vascular ulcers by overexpression of vascular endothelial growth factor and downregulation of necrosis factor kappa B. In this study, we investigate whether prophylactic low-energy SWT improves wound healing after vein harvesting for coronary artery bypass graft surgery.

Methods: One hundred consecutive patients undergoing coronary artery bypass graft surgery were randomly assigned to either prophylactic low-energy SWT ($n = 50$) or control ($n = 50$). Low-energy SWT was applied to the site of vein harvesting after wound closure under sterile conditions using a commercially available SWT system (DermaGold; Tissue Regeneration Technologies, Woodstock, GA). A total of 25 impulses (0.1 mJ/mm^2 ; 5 Hz) were applied per centimeter wound length. Wound healing was evaluated and quantified using the ASEPSIS score. (ASEPSIS stands for Additional treatment,

presence of Serous discharge, Erythema, Purulent exudate, Separation of the deep tissue, Isolation of bacteria, and duration of inpatient Stay). Patient demographics, operative data, and postoperative adverse events were monitored.

Results: Patient characteristics and operative data including wound length (SWT 39 +/- 13 cm versus control 37 +/- 11 cm, $p = 0.342$) were comparable between the two groups. We observed lower ASEPSIS scores indicating improved wound healing in the SWT group (4.4 +/- 5.3) compared with the control group (11.6 +/- 8.3, $p = 0.0001$). Interestingly, we observed a higher incidence of wound healing disorders necessitating antibiotic treatment in the control group (22%) as compared with the SWT group (4%, $p = 0.015$). No SWT-associated adverse events were observed in the treatment group.

Conclusions: As shown in this prospective randomized study, prophylactic application of low-energy SWT improves wound healing after vein harvesting for coronary artery bypass graft surgery.

Study Performance: **dermagold180c**

2.2.20. Shock Wave Therapy to Improve Wound Healing After Vein Harvesting for CABG (Dumfarth et al., 2008)

Dept. Of Cardiothoracic Surgery, Medical University Vienna. Trauma Centre Meidling.

Introduction: Wound healing disorders after vein harvesting for CABG are an evident clinical problem. Extracorporeal shock wave therapy (SWT) has been shown to improve wound healing in patients with diabetic and vascular ulcers. It remains uncertain if prophylactic application of SWT can improve wound healing after vein harvesting.

Methods: In order to study the effect of prophylactic SWT we performed a prospective randomized trial. Eighty consecutive patients undergoing isolated CABG were randomized to either prophylactic SWT ($n=40$) or no treatment as control ($n=40$). SWT was applied after wound closure at the end of the operation under sterile conditions. A total of 25 impulses ($0.1\text{mJ}/\text{mm}^2$; 5Hz) were applied per centimeter wound length. Wound healing was evaluated using the ASEPSIS Score on postoperative days 3-7. Patient demographics, operative data and postoperative adverse events were monitored.

Results: Both groups were comparable with regard to patient characteristics, operative data and postoperative adverse events. Wound length (SWT: 41 ± 13 vs. control: 37 ± 11) was comparable between the two groups ($p=0.110$). The asepsis score showed improved wound healing in the SWT group (SWT: 5.1 ± 5.6 vs. control: 9.7 ± 8.1 , $p=0.009$). We observed no difference in use of antibiotics or in hospital stay. No adverse events were observed in the treatment group.

Conclusion: As shown in this prospective randomized study, prophylactic application of low energy extracorporeal shock wave therapy improves wound healing after vein harvesting for CABG.

11th ISMST Congress in Juan le Pins, France Abstract No. 70.

Study Performance: **Dermagold**

2.2.21. Clinical Experience with ESWT in Sub Acute and Chronic Wounds (Mittermayr et al., 2008)

Trauma Center Meidling, AUVA, Vienna, Austria. Ludwig-Boltzmann-Institute for Experimental and Clinical Traumatology – AUVA Research Center, Vienna, Austria. Austrian Cluster for Tissue Regeneration, Vienna, Austria.

Introduction: Sub-acute or chronic wounds of different etiology represent a major problem not only for the patient but also for the social system. The Trauma Centre Meidling started treating wounds



non-respondent to standard care with ESWT in August 2004. An update from the clinical ESWT experience between 2004 and 2007 is given.

Methods: Patient study enrollment was done during routine clinical work between August 2004 and December 2007. Patients of both sexes with soft tissue wounds of different etiology persistent longer than 1 month were included. The primary outcome measure was rate of wound closure. Secondary different correlation analyses (e.g. defect size, age, etiology) were also done.

Results: As of December 2007, 350 patients had been treated with unfocused extracorporeal shock waves (male: 56%, female: 44%), primarily in an outpatient clinical setting. Mean age was 50.4 (SD 18.0) in males and 71.7 (SD 16.2) in females. Main wound location was the lower extremity, followed by the upper extremity. Etiologically, wound healing disturbances (38.8%) and post-traumatic necrosis (28.9%) were most common. The overall complete healing rate was 69.2%. In addition, 5% of patients showed a healing rate greater than 50% and 2.1% of the patients a healing rate lower than 50% of initial wound size. The percentage of wounds that remained unchanged during ESWT (=non-healed) was 5.9%. The percentage of patients who missed follow-up was 23.7%. A correlation between greater wound size and non-healing wounds was found in the etiology of disturbed wound healing, whereas in the venous ulcers this was not found. A correlation was also found between age of the patient and therapy responsiveness.

Conclusion: ESWT for sub-acute and chronic wounds that are partly non-responsive to standard of care, shows clearly beneficial effects in terms of entire wound closure.

11th ISMST Congress in Juan le Pins, France Abstract No. 71.

Study Performance: **dermagold180c**

2.2.22. *ESWT in Chronic Decubitus Ulceration in Complex Neurological Disability (Larking et al., 2008)*

Institute of Neuropalliative Rehabilitation the Royal Hospital for Neurodisability West Hill Putney London SW15 3SW.

Introduction: Skin ulceration in complex neurological disabilities is often chronic causing pain, risk of septicaemia and limitation of activities leading to a decreased quality of life. Chronic ulcers are also expensive in terms of nursing time and financial cost of treatment. We have previously described provisional findings of a study of ESWT on chronic ulceration. This paper presents the final findings of the study.

Methods: A randomized double-blind cross-over study, with washout period, of ESWT and a placebo ESWT was used. All patients in a large long-stay hospital specializing in chronic neurological conditions were eligible for inclusion in the study. Patients were randomized into treatment with ESWT first or with the placebo ESWT head first. Treatment periods were weekly for four weeks. There was a two-week washout period between the two forms of 'treatment'. After six weeks the treatment methods crossed over. The machine used was the Orthowave 180c with two heads – one active and one inactive. The machine fired for both the ESWT and the placebo treatments thus the noise was the same for both treatment groups. The area and depth of the ulceration was recorded by tracing the outline of the ulcer onto an acetate sheet and measuring the area using a computerized grid system (Visitrak™ [Smith & Nephew]). For each observation the average of three measurements were taken.

Results: Fifteen ulcers (in 13 patients) were included in the study; eight were on the buttocks/sacrum/trochanter and seven were on the feet/ankles. Where there was some healing prior to the study (5) there was no evidence that the ESWT increased the rate of healing. Where there was small surface area ulceration but with a sinus present (3) there was no evidence of healing; but for

those with static chronic ulcers all showed improved healing after the start of ESWT. Where the placebo head was used first there was no healing until after the ESWT treatment started. After the research period those with sinuses were treated using a different technique of ESWT and there was some evidence that healing began to occur though this needs further study under research conditions. Some patients showed a deterioration in the size of the ulceration on starting ESWT. These were patients with undermined ulcers with vulnerable ischemic skin. There was then improved healing – thus the ESWT assisted debridement of the ulcers.

Discussion: It is uncertain why there was no effect of ESWT on those ulcers already showing healing, and this needs further study. The non-healing of the sinuses was probably due to the technique being used, and this needs further research. The main finding was that those ulcers that had not been healing prior to the study all improved, with some healing completely. Considering that some of these ulcers had been present for many months, or even years, this indicates that ESWT has a potential place in the treatment of chronic ulceration in people with complex neurological disabilities.

Conclusion: We were unable to demonstrate any benefit of ESWT on ulcers that were already healing or where there was a sinus present. In the latter case this was probably due to the technique being used. ESWT had a significant effect on healing of those ulcers that had not been showing any healing prior to the study.

11th ISMST Congress in Juan le Pins, France Abstract No. 69.

Study Performance: **orthowave180**

2.2.23. Blood Flow Perfusion and Molecular Response After ESWT in Chronic Skin Ulcers (Wang et al., 2008)

Chang Gung Memorial Hospital - Kaohsiung Medical Center, Chang Gung University College of Medicine, Taiwan.

Introduction: This prospective study evaluated the efficacy of extracorporeal shockwave treatment (ESWT) in chronic skin ulcers and compared with hyperbaric oxygen therapy (HBO), and investigated the antibacterial and regeneration effects.

Methods: 105 patients with 112 chronic skin ulcers were randomly divided into two groups. There were 60 patients with 67 ulcers in the ESWT group and 45 patients with 45 ulcers in the HBO group. Both groups showed similar demographic characteristics. Patients in ESWT group received shockwave treatment, whereas patients in HBO group received HBO therapy. Blood flow perfusion culture and sensitivity and biopsy were performed before and after treatment. The evaluations included clinical assessment, blood flow perfusion scan bacteriological study, histomorphological examination, and immunohistochemical analysis.

Results: The overall results showed: completely healed in 39%, improved in 51% and unchanged in 10% for the ESWT group; and 18% completely healed, 51% improved and 31% unchanged for HBO group ($P = 0.007$). ESWT group showed significantly better blood flow perfusion and considerably more active cell proliferation and concentration than HBO. On immunohistochemical analysis, ESWT group showed significant increases of eNOS, VEGF and PCNA expressions and decreases of TUNEL expression over the HBO group. The culture results revealed significant decreases in bacteria growth after treatment, but no difference was noted between the two groups.

Discussion: ESWT is more effective than HBO in treating chronic diabetic skin ulcers. ESWT significantly improves blood flow perfusion associated with increased angiogenesis, increases cell proliferation and decreases cell apoptosis.



Conclusion: ESWT is effective for treating chronic diabetic ulcers. The application of ESWT results in increased angiogenesis with improved blood flow perfusion molecular responses and tissue regeneration in chronic skin ulcers.

11th ISMST Congress in Juan le Pins, France Abstract No. 75.

Study Performance: [orthowave180](#)

2.2.24. *Non-Focused ESWT & Skin Ulceration in Complex Neurological Disabilities (Andrews et al., 2007)*

Institute of Neuropalliative Rehabilitation Royal Hospital for Neuro-disability West Hill Putney London SW15 3SW UK.

Introduction: Skin Ulceration in complex neurological disabilities is often slow to heal in spite of good nursing care. ESWT offers an opportunity for improving healing rates.

Methods: A blind cross-over study with washout-out period (2 weeks) between unfocussed ESWT and fake ESWT (both weekly for 4 weeks) was used to assess 15 patients with skin lesions secondary to chronic neurological disabilities (late stage multiple sclerosis and brain damage). Nearly all of the patients had cognitive impairment which complicated nursing care.

Results: Several patterns emerged. The ulceration of those with multiple sclerosis either did not heal or took a long time to heal. Some patients showed improvement during the fake- ESWT phase and this was usually rapid. Sinuses did not respond or responded very slowly to unfocussed ESWT.

Discussion: A cross-over study was used to evaluate the response to good nursing care, the Hawthorne and Pygmalion effects or the possibility that concomitant effects (such as the ultrasound gel) might confound the effect of ESWT. When healing occurs in chronic ulceration it is delayed but more rapid than the normal healing pattern. It is still unclear as to the frequency, the 'dosage' or the length of treatment period for optimal benefits from ESWT treatment. Treatment of sinuses may require a focused head for optimal benefit.

Conclusion: 1. A cross-over study design is essential to identify the effects of recovery associated with good nursing care. 2. The optimal 'dose', frequency and treatment period are yet to be identified. 3. Different types of ulceration require different forms of ESWT.

10th International Congress of the ISMST 2007 in Toronto, Canada, Abstract No. 67.

Study Performance: [orthowave180c](#)

2.2.25. *Shockwaves Induce Cellular Response in Diabetic Skin Ulcers (Wang et al., 2007)*

Chang Gung Memorial Hospital, Chang Gung University College of Medicine, Taiwan.

Introduction: Extracorporeal shockwaves were recently used for treatment of chronic diabetic skin ulcers. The preliminary data showed cell apoptosis in diabetic wounds before treatment and the reversal of cell apoptosis after shockwave treatment. This study was to evaluate the cellular responses in chronic diabetic skin ulcers before and after shockwave treatment.

Methods: There are 17 patients with 20 diabetic skin lesions in this study. The energy level of the shockwaves is between 0.03 mJ/mm² to 0.04 mJ/mm² energy flux density, and the focal size is up to 20 mm in diameter. The protocol of shockwave application consists of 300 shocks + 100 shocks/cm² of the size of the ulcer to be performed bi-weekly for a total of three sessions. Clinical assessments included size and depth of the lesion, epithelialization, local sepsis, arteriopathy and denervation before

and after treatment. Biopsies of the lesions were obtained before treatment and at 6 weeks after treatment. The specimens are subjected to histomorphological examination for tissue distributions, cell concentration, the types of cells with intact or disrupted cell membrane and the vascularity, and immunohistochemical analysis for detection of proliferation cell antigen (PCNA) to reflect cell replication, terminal deoxynucleotidyl transferase-mediated dUTP nick end-labelling (TUNEL) for cell apoptosis.

Results: Overall, 25% are healed, 50% improved and 25% are unchanged. Cell apoptosis was noted before treatment. After treatment, there was more active cell proliferation and less cell apoptosis.

Discussion: Shockwave treatment showed 75% satisfactory results in diabetic skin lesions. Reversal of cell apoptosis and enhancement in cell proliferation were observed after shockwave treatment.

Conclusion: Shockwaves appear effective in treating diabetic skin lesions. The cellular responses included the reversal of cell apoptosis and tissue regeneration.

10th International Congress of the ISMST 2007 in Toronto, Canada, Abstract No. 67.

Study Performance: **orthowave180c**

2.2.26. Extracorporeal Shockwave Therapy for Chronic Skin Lesions (Pusch et al., 2007)

Trauma Centre Meidling, Vienna, Austria.

Introduction: In treating infected non-unions connected with chronic skin lesions with ESWT, we observed a significant impact on wound healing. In most of the patients, extremely rapid healing of the wounds was observed. After successful animal trials, performed at the Department of Plastic and Reconstructive Surgery of the University of Innsbruck and the University of Kentucky, we continued our feasibility trial. We used the new parabolic therapy head which delivers almost flat shockwaves.

Methods: Since late 2004 we have treated 261 patients with chronic skin lesions by means of ESWT with the DermaGold® / MTS, Konstanz, Germany. All therapies were performed without any kind of anesthesia as an outpatient treatment. Depending on the surface of the defect, different numbers of pulses were applied. The patients were treated in an average of 3 sessions (1-10) depending to their tendency for regeneration and epithelialization.

Results: Of the 261 patients with skin lesions, 190 (72.8%) showed complete healing; 7 (2.7%) had more than 50% epithelialization; 16 (6.1%) had less than 50% epithelialization; 7 (2.7%) showed no improvement of the lesion; and 41 (15.7%) were lost to follow up. The treatment was tolerated by all patients without any kind of anesthesia. No adverse effects have been observed. In none of the cases was an increase of symptoms reported.

Discussion: After this successful pilot study evaluating the most efficient treatment parameters was completed, a prospective randomized trial to confirm our results commenced in April at Walter Reed Army Medical Center (WRAMC) in Washington, DC.

10th International Congress of the ISMST 2007 in Toronto, Canada, Abstract No. 70.

Study Performance: **DermaGold**

2.2.27. Shock Wave Therapy for Acute and Chronic Soft Tissue Wounds: a Feasibility Study (Schaden et al., 2007)

AUVA-Trauma Center Meidling, Vienna, Austria.



Background: Nonhealing wounds are a major, functionally-limiting medical problem impairing quality of life for millions of people each year. Various studies report complete wound epithelialization of 48 to 56% over 30 to 65 d with different treatment modalities including ultrasound, topical rPDGF-BB, and composite acellular matrix. This is in contrast to comparison control patients treated with standard wound care, demonstrating complete epithelialization rates of 25 to 39%. Extracorporeal shock wave therapy (ESWT) may accelerate and improve wound repair. This study assesses the feasibility and safety of ESWT for acute and chronic soft-tissue wounds.

Study design: Two hundred and eight patients with complicated, nonhealing, acute and chronic soft-tissue wounds were prospectively enrolled onto this trial between August 2004 and June 2006. Treatment consisted of debridement, outpatient ESWT [100 to 1000 shocks/cm² at 0.1 mJ/mm², according to wound size, every 1 to 2 wk. over mean three treatments], and moist dressings.

Results: Thirty-two (15.4%) patients dropped out of the study following first ESWT and were analyzed on an intent-to-treat basis as incomplete healing. Of 208 patients enrolled, 156 (75%) had 100% wound epithelialization. During mean follow-up period of 44 d, there was no treatment-related toxicity, infection, or deterioration of any ESWT-treated wound. Intent-to-treat multivariate analysis identified age ($P = 0.01$), wound size ≤ 10 cm² ($P = 0.01$; OR = 0.36; 95% CI, 0.16 to 0.80), and duration ≤ 1 mo ($P < 0.001$; OR = 0.25; 95% CI, 0.11 to 0.55) as independent predictors of complete healing.

Conclusions: The ESWT strategy is feasible and well tolerated by patients with acute and chronic soft tissue wounds. Shock wave therapy is being evaluated in a Phase III trial for acute traumatic wounds.

Study Performance: **dermagold180c**

2.2.28. Shock Wave Therapy to Improve Wound Healing After Vein Harvesting for CABG (Vögele-Kadletz et al., 2007)

University of Vienna, Dept. of Cardiothoracic Surgery Trauma Hospital Mediling.

Introduction: Wound healing disorders after vein harvesting for CABG are an evident clinical problem. Extracorporeal shock wave therapy (SWT) has been shown to improve wound healing in patients with diabetic and vascular ulcers. It remains uncertain if prophylactic application of SWT can improve wound healing after vein harvesting.

Methods: In order to study the effect of prophylactic SWT we performed a prospective randomized trial. Eighty patients undergoing isolated CABG were randomized to either prophylactic SWT ($n=40$) or no treatment as control ($n=40$). SWT was applied after wound closure at the end of the operation under sterile conditions. A total of 25 impulses (0.1mJ/mm^2 ; 5Hz) were applied per centimeter wound length. Wound healing was evaluated using the ASEPSIS Score on postoperative days 3-7. Patient demographics, operative data and postoperative adverse events were monitored.

Results: The groups were comparable with regard to patient demographics, operative data and postoperative adverse events. Wound length (SWT: 41 ± 13 vs control: 37 ± 11) was comparable between the two groups ($p=0.110$) as well. The asepsis score showed improved wound healing in the SWT group (SWT: 5.1 ± 5.6 vs. control: 9.7 ± 8.1 , $p=0.009$). We observed no difference in use of antibiotics or length of hospital stay. No adverse events were observed in the treatment group.

Conclusion: As shown in this prospective randomized study, prophylactic application of low energy extracorporeal shock wave therapy improves wound healing after vein harvesting for CABG.

10th International Congress of the ISMST 2007 in Toronto, Canada, Abstract No. 71.

Study Performance: **Dermagold**

2.2.29. Extracorporeal Shock Wave Therapy (ESWT) in Skin Lesions (Schaden et al., 2006)

AUVA-Trauma Center Meidling, Vienna. Zentrum für extracorporale Stosswellentherapie, Berlin.

Introduction

Since 1981 extracorporeal shock waves have been used very successfully for the disintegration of calcified deposits in the urethral system. Due to high efficacy and few side effects, this therapy soon became very popular around the world. Since 1990 (1) shock waves have also been used for a variety of orthopedic indications. The therapy proved effective, for example, for tendon insertion conditions such as fasciitis plantaris (heel spur) and tendinosis calcarea of the shoulder. Shock wave therapy is also widely used for radial epicondylitis (tennis elbow). Due to their few side effects, shock waves also gained ground for the treatment of pseudarthroses and delayed healing bone fractures (2). Non-invasive and virtually without complications, ESWT has also been used successfully in pilot studies for the treatment of osteochondritis dissecans (3) as well as aseptic bone necrosis (4, 5, 6). In Japan, shock waves were used successfully in animal trials (7) as well as in clinical trials (8) for the treatment of ischemia-induced myocardial dysfunction. Even skin flap survival in rats improved as a result of shock wave treatment (9).

When treating septic pseudarthroses (osteomyelitis), often linked to skin lesions (fistula formation, skin defects, etc.), bone tissue would consolidate and skin defects would heal particularly fast in many cases. By 1990 Haupt (10) had reported about the positive effects of shock waves in wound healing. In addition, Gerdesmeyer (11) found *in vitro* bactericidal effect of shock wave therapy. Encouraged by such findings, a pilot study on the treatment of skin lesions with ESWT was conducted.

Material and Methods

To conduct the study an OrthoWave® 180c (Dermagold™) from MTS was used. Since, most often, surface defects are involved, the shock wave head was modified in that the shock wave would no longer be focused but would be roughly plane to the treatment area. Low energy flow densities were used to treat the skin lesions. Due to the fact that the skin of all lithotripsy patients as well as that of all orthopedic patients receiving ESWT was exposed to defocused shock waves without any adverse effects reported, we could practically exclude all short- or long-term negative effects for our patients. Depending on the size of the defect, the number of pulses varied from a few (100) to several (1,000). No anesthesia was necessary, due to the defocusing of the shock wave. In principle, the treatment was performed on an outpatient basis except for those patients already admitted for other reasons. Between September 2004 and February 2006, 177 treatments were performed at the Trauma Center Meidling in Vienna on 175 patients (2 patients were treated in 2 areas). Median patient age was 61 years. The patient group was made up of 84 women and 91 men. At the same time, 23 patients (14 women and 9 men) were treated at Berlin's Center for Extracorporeal Shock Wave Therapy. Their average age was 52. The causes of skin lesions are listed in Table 1.

Table 1

Causes of skin lesions	Number
Post traumatic lesions	65
Disturbed wound healing	64
Venous ulcers	25
Arterial ulcers	28
Decubital ulcers	13
Burns	5
Total	200



Since no empiric data were available, treatments were carried out in part in weekly and in part in biweekly intervals. After the first treatment, the same bandage was used in principle as before to prove the effect of shock wave therapy. Only after the second or third treatment, when wound conditions had improved, were adequate dressings used.

Results

Table 2 lists of the results by lesion cause.

Table 2

Causes of skin lesions	Number	Healed	>50%	<50%	Dropout
Post traumatic lesions	65 (32.5%)	57 (88%)		4 (6%)	4 (6%)
Disturbed wound healing	64 (32.0%)	50 (78%)	4 (6%)	3 (5%)	7 (11%)
Venous ulcers	25 (12.5%)	9 (36%)	1 (4%)	6 (24%)	9 (36%)
Arterial ulcers	28 (14.0%)	19 (68%)	3 (11%)	2 (7%)	4 (14%)
Decubital ulcers	13 (6.5%)	9 (70%)	2 (15%)		2 (15%)
Burns	5 (2.5%)	5 (100%)			
Total	200 (100.0%)	149 (74.5%)	10 (5.0%)	15 (7.5%)	26 (13.0%)

>50% epithelialization over 50%

<50% epithelialization under 50%

In the beginning of the treatment, most of the treated skin lesions were to be considered as infected. Particularly striking was a lessening of the infection after the first treatment, the result perhaps of the bactericidal effect of shock waves. None of the patients received any antibiotics.

None of the patients experienced any worsening of the wound. Only one (female) patient dropped out after the first therapy because she expected it to fail. For the most part, dropouts involved the very old as well as a few decrepit patients who, after the improvement of their wound, preferred to avoid the strenuous transportation to the hospital.

Discussion

Based on the initial encouraging results of our pilot study, a completely novel potential of shock wave therapy has seemed to emerge. After these pilot studies, evaluating the most efficient treatment parameters, were completed, a prospective randomized IDE-trial to confirm our results in treating diabetic foot ulcers commenced in April 2006.

9th ISMST Congress in Rio de Janero, Brazil.

Study Performance: **dermagold180c**

2.3. Pathologic Scarring

2.3.1. Extracorporeal Shock Wave Therapy for Hypertrophic Scars (Chuangsuwanich et al., 2022)

Division of Plastic Surgery, Department of Surgery, Faculty of Medicine Siriraj Hospital, Mahidol University, Bangkok, Thailand.

Background: Hypertrophic scars cause aesthetic concerns and negatively affect the quality of life. A gold standard treatment for hypertrophic scars has not been established due to various responses of modalities. Extracorporeal shock wave therapy (ESWT) is a noninvasive and affects scar remodeling by fibroblast regulation. This study investigated the effectiveness of ESWT for hypertrophic scars.

Methods: Twenty-nine patients were enrolled. All patients underwent ESWT once a week for 6 consecutive weeks. Their scars were assessed using the Patient and Observer Scar Assessment Scale (POSAS), erythema index, melanin index, and scar pliability before treatment and again 4 weeks after treatment completion.

Results: Thirty-four hypertrophic scars in this study had persisted for between 6 months and 30 years. Most scars developed after surgical incision (55.88%). The chest and upper extremities were the predominant areas of occurrence (35.29% each). Most of the POSAS subscales and total scores were significantly improved 4 weeks after treatment ($p < 0.05$). Furthermore, the pain, itching, and pigmentation subscale were improved. The pliability, melanin index, and erythema index were also improved, but without significance. The patients were satisfied with the results and symptoms alleviation, although subjective score changes were insignificant. No serious adverse events were found. The patients reported pruritus in 62.5% and good pain tolerance in 37.5%. Subgroup analyses found no differences in scar etiologies or properties at different parts of the body.

Conclusion: The ESWT is a modality for hypertrophic scar treatment with promising results. Most of POSAS subscales were significantly improved.

Study Performance: **dermagold100**

2.3.2.Extracorporeal Shock Wave Treatment: An Emerging Treatment Modality for Retracting Scars of The Hands (Saggini et al., 2015)

Department of Medical Sciences, Oral and Biotechnology, "G. D'Annunzio" University, Chieti, Italy.

Prolonged and abnormal scarring after trauma, burns and surgical procedures often results in a pathologic scar. We evaluated the efficacy of unfocused shock wave treatment, alone or in combination with manual therapy, on retracting scars on the hands. Scar appearance was assessed by means of the modified Vancouver Scar Scale; functional hand mobility was evaluated using a range-of-motion scale, whereas a visual analogue score was implemented for detecting any improvements in referred pain. Additionally, biopsy specimens were collected for clinico-pathologic correlation. For each active treatment group, statistically significant improvements in modified Vancouver Scar Scale were recorded as early as five treatment sessions and confirmed 2 wk after the last treatment session. Analogous results were observed when assessing pain and range of movement. Histopathological examination revealed significant increases in dermal fibroblasts in each active treatment group, as well as in neoangiogenetic response and type-I collagen concentration.

Study Performance: **dermagold100**

2.3.3.Regenerative Model with ESWT in Atrophic and Retracting Scars (Saggini et al., 2014)

"G. d'Annunzio" University, Chieti, Italy.

Introduction: The aim of our study was to evaluate the efficacy of the treatment of hand scars with unfocused shock waves alone and in combination with manual therapy.

Methods: 40 patients with an history of surgical painful scars after hand surgery were treated between November 2012 and May 2013. Treatment consisted of 10 ESWT sessions (twice a week for 5 weeks). Subjects were randomly divided in 3 groups. Group A received unfocused ESWT; Group B received unfocused ESWT and Manual Myofascial Therapy; group C did not receive any treatment (control group).

Results: Group A: the mean scar vascularity before treatment (T0) was 2,3 and after(T1) 0,2 ($P < 0,05$); scar pigmentation was 2,4 at T0 and 0,5 at T1 ($P < 0,05$); scar height was 2,3 at T0 and 0,5 at T1 ($P < 0,05$);



scar thickness was 3,5 at T0 and 1,6 at T1 ($P<0,05$). Pain assessment by VAS was 4,3 before treatment and 2,1 after ($P<0,05$). In group B: the mean scar vascularity before treatment (T0) was 2,2 and after (T1) 0,5 ($P<0,05$); scar pigmentation was 2,4 at T0 and 0,3 at T1 ($P<0,05$); scar height was 2,4 at T0 and 1,3 at T1 ($P<0,05$); scar thickness was 3,1 at T0 and 1,2 at T1 ($P<0,05$) h. Pain assessment by VAS was 5,2 before treatment and 2 after ($P<0,05$). In group C: the mean scar vascularity before treatment (T0) was 2,4 and after (T1) 1,9; scar pigmentation was 1,4 at T0 and 0,9 at T1; scar height was 2,5 at T0 and 2,2 at T1; scar thickness was 3,4 at T0 and 2,7 at T1. Pain assessment by VAS was 5,3 before treatment and 4,3 after. In summary we found a significant improvement of vascularity, color, height, thickness, pigmentation, a significant reduction of hyper sensibility and a remission of pain in groups A and B which received ESWT. The reduction of hand disability and the return to daily activity was very significant for groups A and B. The control group, C group, didn't have any significative benefit at the second evaluation.

Discussion: Multiple sources of dermal damage may induce deposition of new collagen through activation of dermal fibroblasts. Fibroblasts are mesenchymal cells playing a critical role in wound healing. Fibroblasts are capable of secreting the precursors of Extracellular Matrix (ECM) components, including basal substance, collagens, glycosaminoglycans, reticular and elastic fibers, glycoproteins. Shock-wave treatment has been shown to induce an increase in the number of activated fibroblasts, CD34+ fibrocytes, and fXIII+ dendritic cells; this process leads to the deposition of new collagen, characterized by thinner collagen fascicles and parallel orientation to the dermo epidermal junction. Indeed, a strong correlation may be observed between such histologic features and scar macroscopic appearance in treated patients. Additionally, shock-wave therapy may be regarded as playing a significant role in the increase in CD31+ vessel density in the dermis of treated patients, allowing an improved tissue metabolism.

Conclusion: In this way and considering the significative clinical results we can confirm that ESWT can be an elective treatment in skin healing disorders, even without other contribution like Manual Myofascial Therapy.

17th ISMST Congress in Milano, Italy. Abstract No. 63.

Study Performance: **dermagold100**

2.3.4. The Effectiveness of Extracorporeal Shockwave Therapy in the Treatment of Surgical Hand Scars (Saggini et al., 2013)

Dept. Neuroscience and Imaging, "G. D'Annunzio" University, Chieti, Italy.

Introduction:

Cutaneous scarring can cause patients symptoms ranging from psychological to physical pain. Although the process of normal scarring is well described the ultimate cause of pathological scarring remains unknown. The retracting scars on the hands may cause significant functional deficits. For this reason, clinical studies for preventative or curative scarring treatments are crucial.

Previous studies showed that shockwaves are effective in stimulating several endogenous growth factors such as EGF, IGF1, VEGF and nitric oxide production inducing angiogenesis and promoting the healing of fractures, ulcers and complex lesions. In 2009 Kuo et al. also showed that ESWT is able to: 1) reduce the inflammatory response with subsequent reduction in the number of circulating leukocytes and of oxygen free radicals; 2) promote the production of fibroblasts and the vascularization of the compromised skin, thus reducing the number of apoptotic cells. The aim of our study was to evaluate the efficacy of the treatment of hand scars with unfocused shockwaves and to judge the improvement of the function of the hand.

Methods:

We studied a group of 60 patients, aged between 20 and 65 years, with painful scars over one month after surgery. The patients were randomly divided in 5 groups: group A with surgical scars did not receive treatment with ESWT (control group), group B with surgical scars received treatment only with unfocused ESWT, group C with surgical scars with regional pain complex syndrome received treatment only with unfocused ESWT, group D with surgical scars received treatment with unfocused ESWT associated with manual rehabilitation, group E with surgical scars received treatment with unfocused ESWT associated with manual rehabilitation and local treatment with I-COONE system.

The patients were treated with a frequency of 2 sessions every 7 days for 5 weeks with Dermagold system using 500 impulses at 0,11 mJ/mm². Their evolution was monitored by histological and clinical examination, scar scales and photography.

For histological examination, biopsy specimens were performed on patient's scars before and 5 weeks after shockwave therapy and subsequently stained with hematoxylin-eosin, picrosirius red and immunohistochemical stains for FXIII, CD34 to evaluate collagen and stain for CD34 to assess vascular response to therapy. Biopsies were also taken from patients who did not undergo shockwave therapy. Scar scales have been devised to quantify scar appearance in response to treatment. We used 3 scar scales for the evaluation that were originally designed to assess subjective parameters in an objective way. The Vancouver Scar Scale (VSS), Patient and Observer Scar Assessment Scale (POSAS), Visual Analogic Scale (VAS). These observer-dependent scales consider factors such as scar height or thickness, surface area, texture, pigmentation and vascularity.

Results:

In the groups B, C, D, E a significant improvement of vascularity, color, height, thickness, pigmentation, and a significant reduction of scars hypersensitivity and a remission of pain has been observed evaluated with Visual Analogic Scale. Reduction of hand disability and return to the daily activity was very important for shock wave treated patients. Conversely the control group not receiving shockwave therapy did benefit on the reduction of hand disability and pain and did not show a significant improvement of vascularity, color, height, thickness, and pigmentation.

We observed in all patients of B, C, D and E group a more ordered disposition of collagen bundles, increased amount of fibroblasts and vascular proliferation in histological examination compared to the control group A.

Conclusion:

Unfocused shockwave therapy seems to have a positive influence on scar formation on scars of the hand after surgery.

16th International Congress of the ISMST 2013 in Salzburg, Austria, Abstract No. P51.

Study Performance: **dermagold100**

2.4. Lymphoedema

2.4.1. Low-Energy Extracorporeal Shockwave Therapy as a Therapeutic Option for Patients with a Secondary Late-Stage Fibro-Lymphedema After Breast Cancer Therapy: A Pilot Study (Joos et al., 2020)

Department of Physical Medicine and Rehabilitation and UZ Brussels, Brussels, Belgium.

Background: Secondary lymphedema (LE) can occur after breast cancer (BC) therapy with axillary lymph node surgery and/or radiotherapy. Reported incidence varies around 20%. The aim of this study



was to see whether low-energy extracorporeal shockwave therapy (ESWT) is a therapeutic option in end-stage secondary upper limb fibro-LE.

Methods and Results: A pilot study was performed on 10 adult patients who presented with an end-stage LE after BC treatment. They were all treated with usual physical therapy and all had lymphatic surgery before. Eight sessions of ESWT were applied, 2600 shocks at 0.1 mJ/mm^2 , 2/week during 4 weeks. Upper limb volume decreased nonsignificantly, from 3086.4 ± 539.47 to 2909.1 ± 471.60 mL. Mean circumference of the upper limb was significantly decreased from 32.3 ± 3.01 to 31.4 ± 2.71 cm at the height of the upper arm, from 29.1 ± 2.89 to 28.1 ± 2.71 cm at the height of the elbow, and from 27.5 ± 4.08 to 26.8 ± 3.75 cm at the height of the forearm. Subjective measurements by visual analog scale showed significant decrease in both hardness from 57.3 ± 15.84 to 24.4 ± 21.89 mm and subjective feeling of edema from 44.2 ± 16.90 to 23.2 ± 21.16 mm. No adverse features were reported.

Conclusion: We added some evidence that low-energy ESWT is well supported and has additional benefits also in longstanding fibro-lipo-LE on swelling of the arm leading to more subjective comfort for the patients.

Study Performance: **dermagold100** with applicator OP155

Also presented at the 23rd World Congress of the ISMST 2017 in Vienna, Austria, 7. ESWT in Wound Healing Disorders.

3. Urology

3.1. Peyronie's Disease

3.1.1. Low-Intensity Extracorporeal Shockwave Therapy (LI-ESWT) for Peyronie's Disease: a 4 Year Single Center Experience (Chiarelli et al., 2022)

Istituto Clinico Città Studi (Milano), Italy.

Objective

The aim of this study is to evaluate the low-intensity extracorporeal shock wave therapy (li-ESWT) efficacy using the HMT Orthogold 100 lithotripter in treating Peyronie's disease based on parameters such as penile curvature, erectile function and penile pain during erection.

Materials and Methods

120 patients from our clinical institute were selected from January 2018 to December 2021. The mean disease duration was 21 months (6 – 60 months). All patients were no-responders to medical oral therapy. Before and after treatment, the angle was calculated through self-photography after an erection induced by a vacuum device and we were able to evaluate the pain intensity during the erection using the Wong – Baker visual pain analog scale or the Facies Pain Scale (0 – 10). The International Index of Erectile Function (IIEF-V) was used for erectile dysfunction (ED). All patients had at least one symptom, i.e. 78 patients experienced pain during erection (with a pain average on the visual scale from 6 to 8); 113 patients had a mean angulation of 42 degrees (with a range between 15 degrees and 55 degrees); while 56 patients presented a mild to moderate erectile dysfunction (IIEF-V between 10 and 18). The HMT Orthogold 100 lithotripter was adopted for the treatment. The plaque was localized through clinical palpation and a fast ultrasound scan. The mean follow-up was 9 months (range 6 – 12 months). Each patient received at least one li-ESWT session (3000 shock waves, 7 kJ) applied to a flaccid penis, i.e. one treatment per week for 6 weeks. Each treatment lasted about 10 minutes.

Results

All patients completed the protocol. Tolerance and safety proved to be excellent, in line with International statistics. Of the 78 patients who experienced pain during erection, 69 (89%) reported immediate relief after li-ESWT (with a mean pain reduction of 2.9 on the visual pain scale, equal to a $p < 0.00001$). For 42 patients (37%) an improvement in angulation was observed (greater than 5 degrees), with a mean reduction of 20 degrees ($P < 0.001$). For patients affected by erectile dysfunction, 43 (77%) had a higher Questionnaire score (greater than 4 points). Finally, 35 patients (31%) reported the plaque was subjectively smoother compared to that at the beginning of treatment.

Discussions

In our experience, low-intensity extracorporeal shockwave therapy performed with a HMT Orthogold 100 lithotripter for the treatment of Peyronie's disease has proven to be a feasible, reproducible, painless, safe and an effective treatment for reducing pain during erection. This technique demonstrated an improvement in the penile curvature and also confirmed that low intensity shock waves are an effective support when treating mild to moderate erectile deficit.

Conclusion

Extracorporeal shock wave therapy may be helpful in Peyronie's disease management for refractory penile pain and reduction in plaque size. However, penile pain typically resolves spontaneously over time, and shock wave therapy can be a significant financial burden for patients. A multi-institutional randomized controlled trial with standardized methods and strict inclusion criteria regarding disease duration would be useful to determine the true efficacy of shock waves therapy in Peyronie's disease.

XXIX Congresso Nazionale Associazione Urologi Italiani (AURO.it), Napoli, 19-22 maggio 2022. Abstract No. #132

Study Performance: **OW100**

3.1.2. Extracorporeal Shockwave Therapy in the Treatment of Peyronie's Disease: Our Initial Experience (Inneo et al., 2021)

UO Urologia, ICCS Milano, Milano, ITA

Objective

To evaluate whether extracorporeal shockwave therapy (ESWT) using our Orthogold 100 HMT lithotripter with OE50 head is effective in the treatment of Peyronie's disease on parameters such as penile curvature, erectile function and penile pain during erection.

Materials

We selected 86 patients with Peyronie's disease between January 2018 and December 2019, (after failure of oral medical therapy). Angulation was calculated by self-photography after Vacuum-induced erection, allowing us to assess the intensity of pain during erection, the severity of which was measured using the Wong - Baker visual pain scale. For erectile deficit, the IIEF-V self-assessment questionnaire was used. All patients had at least one symptom, 56 patients had pain during erection (average between 6 and 8); 81 patients had an average angle of 40 degrees; finally 40 patients also had mild to moderate maintenance erectile dysfunction (IIEF-V score between 10 and 18). Lithotripsy was performed with an HMT Orthogold 100 lithotripter. The plaque was localised by clinical palpation and penile ultrasound. The mean duration of disease was 19 months (4 - 60) and the mean follow-up was 9 months (6 - 12).

Methods



Each patient received an extracorporeal shock wave session (3000 shocks per treatment at an intensity of 0.15mJ/mm²) applied to a flaccid penis, one treatment per week for 6 weeks. Each one lasted approximately 10 minutes.

Results

All patients completed the protocol. The procedure was tolerated and safe. Of the 56 patients who presented with pain during erection, 51 (91%) reported relief immediately after treatment with ESWT (with a mean reduction of 2.9 on the visual analogue pain scale). An improvement in angulation (greater than 5 degrees) was observed for 30 patients (37%), with an average reduction of 15 degrees. For patients with erectile dysfunction, 31 (78%) had an increased questionnaire score (greater than 4). Finally, 25 patients (31%) expressed satisfaction by reporting that the plaque on self-examination was smoother.

Conclusion

Extracorporeal shock wave therapy may be useful in the management of Peyronie's disease for refractory penile pain and improvement of erectile deficit. A multicentre randomised controlled trial with standardisation of methods and strict inclusion criteria regarding disease duration would prove useful in determining the true efficacy of shock wave therapy in Peyronie's disease.

44th National Congress of the Italian Association for the Study of Pain September 23, 2021 - September 25, 2021. Cureus Journal of Medical Science 13, no. 9 (2021).

Study Performance: **OW100**

3.2. Erectile Dysfunction

3.2.1. Low Intensity Shockwave Treatment of the Erect Penis: Assessment by Pre-and Post-Grayscale (Goldstein et al., 2024)

San Diego Sexual Medicine, San Diego, California, United States of America.

Objectives

We assessed changes in penile Grayscale/color Doppler ultrasound (G/DUS) parameters in men with ED after LiSWT treatments.

Methods

A retrospective chart review of penile G/DUS pre and post LiSWT (Urogold 100 MTS) was performed. B-mode ultrasounds performed at specific settings include 12 axial images at the proximal, midshaft and distal dorsal penis at a fixed dynamic range of 70 dB with B-mode gain values of increased brightness (45%, 55%, 65%). The fourth image at each location was taken at a dynamic range of 49 dB and B-mode gain value identified as providing best discrimination between Grayscale black/white. In the erect shaft right/left sagittal planes, cavernosal artery peak systolic velocity (PSV) and end diastolic velocity (EDV) values were obtained. ED patients then underwent 6 erect penile LiSWT treatments over varying intervals. After pharmacologic erection, 600 shocks (energy flux density 0.13mJ/mm², 3 Hz, membrane pressure 3), were applied each to dorsal, ventral, right/left lateral penile shaft, and right/left crura. PGI-I was scored at each repeat visit. Approximately 2 months after the last treatment, penile G/DUS was repeated. Baseline and post-treatment G/DUS were de-identified and read by two experts for erectile tissue inhomogeneity on Grayscale with 0/3 no inhomogeneity, 1/3 mild inhomogeneity (<25% of cross-sectional area revealing hypo- or hyper-echoic regions), 2/3 moderate inhomogeneity (25% - 50%), and 3/3 severe inhomogeneity (>50%), respectively. PGI-I scores were compared to ultrasound findings.

Results

79 patients (mean age 44 +/- 21) met inclusion criteria. 53/79 (67%) had improved erectile tissue homogeneity post-LiSWT, 10/79 (13%) were unchanged, 15/79 (19%) worsened. Of patients with improved G/DUS findings, 40/53 (75%) rated PGI-I as improved. 37/53 (70%) had PSV increase and 18/53 (34%) had EDV decrease.

Conclusions

The mechanisms by which erect penile LiSWT improves erectile function, in part, involve enhanced erectile tissue homogeneity, increased PSV and decreased EDV.

Conflicts of Interest

No conflicts of interest.

ESSM congress 2024, Bari, Italy. Poster presentation, P-01-07 #177.

Study Performance: **OW100 urogold100**

3.2.2. Low Intensity Shockwave Therapy for Erectile Dysfunction: A Sham-Controlled Randomized Trial (Goldstein et al., 2024)

San Diego Sexual Medicine, San Diego, California, United States of America.

Objectives

A sham-controlled, randomized prospective trial in men with ED was performed using an electrohydraulic shockwave device (Softwave/Urogold, TRT).

Methods

In this single-blind study performed in men with ED, participants were randomized 2:1 to active low intensity shockwave therapy (LiSWT) (4 Hz, 0.12 mJ/mm²) or sham. Arm 1 consisted of 3 treatments of 5000 shocks every 3 weeks. Arm 2 consisted of 5000, 3000, 3000 shocks during weeks 1, 2, 3, respectively, followed by an identical cycle of treatment 3 weeks later. Doppler ultrasound/grayscale was performed at weeks 20 and 32. Participants completing sham treatment crossed over to LiSWT. Post-treatment end diastolic velocity (EDV) and peak systolic velocity (PSV) were measured, and visual grading scores used to assess hypoechoic regions in the corpora cavernosa. Data were analyzed by 2-way repeated measures ANOVA with Geisser-Greenhouse correction. Pairwise comparisons were performed to baseline using Dunnett's multiple comparison test. Missing data were imputed by "last observation carried forward".

Results

36 participants (22 active, 14 sham) were randomized. Sham treatments showed no significant changes. Visual grading scores in the proximal region were consistently higher with active LiSWT vs sham (Arm 1 = 88.9% vs. 11.1%; Arm 2 = 40.0% vs. 20.0%, respectively), statistically significant in Arm 1 at weeks 20 (p=0.005) and 32 (p=0.001). Sham participants also had improved grayscale ratings after LiSWT (Arm 1 = 33.3% vs. 11.1%; Arm 2 = 40.0% vs. 20.0%). After LiSWT, greater numbers of patients had higher PSV, lower EDV, or no worsening relative to baseline. Decrease in EDV was statistically significant in active treatment Arm 2 at Week 32 (p=0.003). Adverse events were transient.

Conclusions

Statistically significant changes from baseline between sham and active treatments in primary outcome measures with no adverse events support safety and efficacy of LiSWT for treating ED.

Conflicts of Interest

No conflicts of interest.

ESSM congress 2024, Bari, Italy. Poster presentation, P-01-07 #181.

Study Performance: **OW100 urogold100**

3.2.3. Simulation of Erectile Tissue Shockwave Energy Absorption During Low LiSWT for Erectile Dysfunction (Goldstein et al., 2024)



San Diego Sexual Medicine, San Diego, California, United States of America.

Objectives

Low intensity shockwave therapy (LiSWT) treats ED by inducing mechanotransduction regenerative mechanisms; the greater the shockwave energy absorbed in cavernosal erectile tissue, the greater the opportunity for mechanotransduction. Energy absorption may be improved by erect vs flaccid penile treatment. Compared to flaccid, erect intracavernosal penile pressure is 16-fold higher and erect blood volume >2 times greater, both properties determinants of tissue energy wave velocity. Additionally, energy absorption may be improved using a symmetry-matched secondary reflector. This may reflect shockwave energy back to the erectile tissue that had previously passed through the penis. We performed a simulation of energy absorption during LiSWT in flaccid/erect penis with/without a reflector.

Methods

This energy model used the UroGold100 MTS/Softwave TRT electrohydraulic shockwave device. Sound propagation in tissue can be illustrated via computer simulation by mathematically calculating damping and deflection of the sound wave by different tissue structures. Finite Element Method (FEM) simulation models are suitable for the mathematical description of complex processes of shockwave propagation. Based on results, a "prediction" of propagation of LiSWT in tissue is possible. This patient-specific procedure is based on consideration of individual anatomical structures: corporal lacunar spaces and physical-acoustic laws. For FEM modeling of LiSWT propagation, program systems ANSYS, MATLAB and PZFLEX/ONSCALE were used.

Results

Using the FEM calculation model of the simulation analyses, the shockwave pulse was applied at the bottom edge of the model. This pulse propagated through the erect/flaccid states; there was most energy absorption in the erect state with a reflector. In addition, the simulation model showed that increasing penile pressure during erection with a constant volume increased energy absorption.

Conclusions

More energy is absorbed in cavernosal erectile tissue to achieve mechanotransduction during erection than flaccidity, and with a symmetric reflector. Such strategies should be considered when performing shockwave therapy for ED.

Conflicts of Interest

Erich Theuer is a consultant to MTS.

Nikolaus Hopfenzitz is an employee of MTS.

John Warlick is owner of Softwave/TRT.

ESSM congress 2024, Bari, Italy. Poster presentation, P-01-07 #179.

Study Performance: **OW100 urogold100**

3.2.4. Variations in Low Intensity Shockwave Treatment Protocols for Erectile Dysfunction: A Review of the Literature and Guide to Offering Treatment (Hayon et al., 2023)

Department of Urology, Northwestern University Feinberg School of Medicine, Chicago, IL, USA.

Low-intensity shockwave therapy (LiSWT) for erectile dysfunction (ED) continues to gain popularity in both clinical practice and the academic literature. The majority of trials and meta-analysis studies have shown LiSWT to be low risk with a trend toward positive improvements in International Index of Erectile Function (IIEF) scores. However, there is still debate over the clinical utility of LiSWT and there is no agreed upon optimal treatment protocol. In this review article we summarize published meta-

analysis studies of LiSWT for ED, and review the treatment protocols from randomized sham-control trials published in the last 10 years. We found the most common device settings were an energy of 0.09 mJ/mm² and a frequency of 5 Hz. Shock number and location varied, but the most common protocol was 1,500 shocks per session, with 900 shocks to the penis (shaft, base, or hilum) and 600 shocks to the proximal corpora/crura. Protocols ranged from 4 to 12 treatment sessions. We also describe our institutional experience with LiSWT, including patient counseling and treatment protocol.

Study Performance: **OW100 urogold100**

3.2.5. Three-dimensional shockwave modeling of the efficacy of secondary reflectors in low intensity shockwave therapy to the penis (Janout et al., 2023)

Ludwig Boltzmann Institute for Traumatology, Vienna, Austria.

Introduction

Potential tissue damage has long been linked to induced pulmonary capillary bleeding brought on by increased tensile wave amplitudes in the vicinity of significant impedance mismatches, such as tissue interfaces. The evaluation of potential tissue damage is given by tissue-safety parameters. These parameters are provided by ultrasound based mechanical index (MI) thresholds, which have to be assessed based on the utilized shockwave applicator. Furthermore, electrohydraulic generators have long been associated with large volumetric treatment zones and weak tensile wave strengths. This study aims to show that using a symmetry-matched secondary reflector in the therapeutic treatment of the penis in men with erectile dysfunction can: i) not only reduce the appearance of further induced tensile stress forces but ii) also increase the treatment volume of each applied shockwave.

Material & Method

One of the key aspects in choosing a shockwave applicator is the treatment volume per shot. We evaluate the in-situ pressure field distributions using 3-dimensional numerical non-linear shockwave modelling. Additional water bath reference and phantom-based in-situ hydrophone sound pressure measurements enable a therapeutic application's systematic evaluation. Following these measurements, detailed knowledge of soundwave propagation allows for evolutionary strategy-based optimization of ideal reflector geometries, further increasing the efficacy of low-intensity shockwave therapy to the penis. The resulting reflector designs are 3-dimensional printed and once again evaluated in the water bath and simulated clinical phantom application.

Results

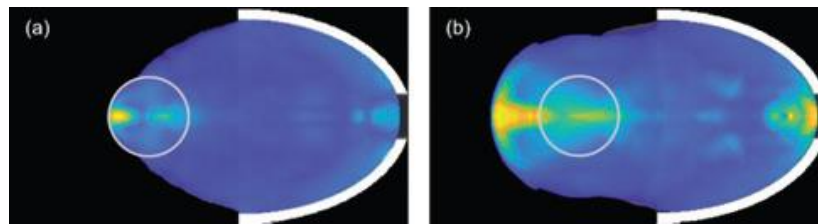
Introducing an applicator-tailored reflector increases therapeutic volume and reduction of tensile wave content in the clinical application. Therapeutic longitudinal shockwaves during treatment at the lateral end of the application undergo phase-inversion at the air interface, and an enhanced tensile wave is created at the boundary. In addition, the geometry of the genitalia creates a collecting reflection. Still, due to the symmetry and phase mismatch, no significant refocusing occurs at this secondary reflector. Adding an applicator-matched reflector eliminates the enhanced tensile wave within the treatment zone. Furthermore, it provides a subsequent tertiary pulse of intensity after the insignificant primary and strongest secondary wave pulses.

Discussion

The applicator's focal zone may be extended by refocusing the pressure waves past the tissue of interest during shockwave therapy treatment of the penis. Selectively using a reflector may improve clinical outcomes by reducing tissue stress caused by tensile forces and potentially harmful cavitation effects. Simultaneously, a weakly refocusing tertiary wave in rapid succession of the main treatment pulse increases the size of the treatment volume of a single pulse, potentially increasing therapeutic efficacy.



Figure 1



Tensile pressure distribution of a shockwave pulse without a reflector (a) and with a reflector (b). Surrounding air is visualized in black, and a gray circle indicates the penile cross-section.

Technology: Focused Shockwave, k-wave Toolkit

Device and Manufacturer: Orthogold100 by MTS Medical UG, Konstanz, Germany; Müller-Platte Needle Probe by Müller Instruments, Oberursel, Germany

COI: No conflict of interest

25th ISMST Congress Daegu, Korea, 2023.

Study Performance: **OW100**

3.2.6. Low Intensity Shockwave Therapy (LiSWT) for Improvement of Erectile Function: Prospective Study and Engineering Studies (Goldstein et al., 2023)

San Diego Sexual Medicine, Sexual Medicine, San Diego, USA.

Introduction: The Softwave electrohydraulic shockwave device is FDA cleared for improved blood flow and connective tissue activation; retrospective studies in ED patients have shown positive outcome. There are limited engineering studies of energy absorption during shockwave treatment for ED.

Objective: To perform an analysis of sham/active treatment changes in primary outcome measures of grayscale ultrasound and DUS. To perform shockwave modeling to better assess energy absorption during shockwave treatment for ED.

Methods: A: A single-blind, sham-controlled, randomized, prospective study in men with ED naïve to acoustic wave therapy was performed. Those meeting inclusion/exclusion were randomized to one of two treatment arms and assigned to active or sham, 2:1 within each arm. Arm 1 consisted of three treatments of 5000 shocks every three weeks, 4 Hz, 0.12 mJ/mm²; arm 2 consisted of 5000, 3000 and 3000 shocks, 4 Hz, 0.12 mJ/mm²; weeks one, two and three respectively, three weeks without treatment, then repeat treatments every three weeks. First follow-up was 20 weeks after initial treatment; DUS and grayscale imaging using a 15.4 MHz probe were repeated under pharmacologic erection 3-4/4 hardness. Post-treatment grayscale percent hypoechoic regions within the corpora cavernosa were assessed: none (0), mild (1), moderate (2) and severe (3) and compared to baseline. Post-treatment EDV and PSV were compared to baseline. Upon completion subjects were unblinded. Subjects assigned to sham were crossed over to the opposite arm for active treatment. Subjects initially in active treatment underwent a second follow-up 32 weeks after initial treatment. Data from each treatment arm were analyzed by two-way repeated measures ANOVA with Geisser-Greenhouse correction. Follow-up pairwise comparisons to baseline were performed using Dunnett's multiple comparison test. In subjects with one on-treatment assessment, missing data due to early discontinuation from the study were imputed by the "last observation carried forward" method.

Methods B: This research used the Softwave TRT (MTS UroGold) electrohydraulic shockwave device. When sound waves pass through an interface between 2 media with different impedances, sound propagation can be significantly altered. If impedances of the media are different, part of the sound energy is reflected into the incident medium; the rest of the sound energy is transferred to the second medium. Sound propagation in tissue can be illustrated via computer simulation by mathematically calculating the damping and deflection of the sound wave by different tissue structures. Finite Element Method (FEM) simulation models are particularly suitable for the mathematical description of complex processes of shockwave propagation, such as in the flaccid and erect penis. Based on results, a "prediction" of propagation of LiSWT in tissue is possible. This patient-specific procedure is based on consideration of individual anatomical structures: corporal lacunar spaces and physical-acoustic laws. For FEM modelling of LiSWT propagation, program systems ANSYS, MATLAB and PZFLEX/ONSCALE were used.

Methods: C) 3-dimensional numerical non-linear shockwave modeling is used to evaluate the pressure field distributions during the application of low intensity shockwaves therapy to the penis for erectile dysfunction (Figure 1). Using water bath reference and phantom-based in-situ hydrophone sound pressure measurements, a systematic evaluation of a therapeutic application may be performed. A detailed knowledge of the soundwave propagation allows for evolutionary strategy-based optimization of ideal reflector geometries.

Results A: Powered for 60 subjects, recruitment was stopped (COVID) after randomizing 36 subjects (22 active, 14 sham). The proximal penis exhibited greatest improvement (decreased heterogeneity score) on grayscale. The number of subjects with improved erectile tissue grayscale ratings in the proximal region was consistently higher in active treatment versus sham groups (Arm 1 = 88.9% vs. 11.1%; Arm 2 = 40.0% vs. 20.0%, respectively). Sham subjects rolled over to active LiSWT also had improved grayscale ratings (Arm 1 = 33.3% vs. 11.1%; Arm 2 = 40.0% vs. 20.0%). Change in heterogeneity was statistically significant for the proximal region in active treatment Arm 1 at both Week 20 ($p=0.005$) and Week 32 ($p=0.001$). Mean IIEF-EF scores were nominally higher in subjects in active treatment with improved grayscale ratings versus those with no improvement on grayscale. Concerning penile blood flow, improvement after LiSWT greater numbers of patients had higher PSV or lower EDV relative to baseline; greater numbers of patients had no worsening in blood flow parameters. Decrease in EDV reached statistical significance in active treatment Arm 2 at Week 32 ($p=0.003$). Adverse events were transient.

Results B: Using the FEM calculation model of the simulation analyses, the shockwave pulse is applied at the bottom edge of the model (Fig 2-1) and propagates through the erect (Fig2- 2a) and flaccid (Fig 2-2b) states, with the most energy absorption in the erect penis, shown in red. Fig 2-3 shows the effect of increased penile pressure on energy absorption when the volume is constant.

Results C: Therapeutic longitudinal shockwaves reflected at the lateral end of application undergo phase-inversion at the air interface resulting in the local creation of an enhanced tensile wave about the boundary. The geometry of the genitalia creates a collecting reflection but due to the symmetry and phase mismatches no significant refocusing occurs at this secondary reflector. The addition of an applicator-matched reflector removes the enhanced tensile wave inside the treatment zone and provides a successive tertiary pulse of intensity between that of the insignificant primary and strongest secondary wave pulse. Figures A and B show tensile pressures of 3-dimensional numerical non-linear shockwaves. Fig A shows the traditional treatment method, while Fig B displays a reflector placed behind the penis with a layer of water acting as a buffer zone for potentially damaging tensile waves. The tensile pressure content inside the penis is significantly lower in B than A.



Conclusion A: Flaccid penile LiSWT appears to be safe and efficacious for treating ED based on statistically significant changes between sham and active treatments in primary outcome measures grayscale ultrasound and DUS.

Conclusion B: More energy is absorbed in cavernosal tissue during erection than in the flaccid state, with greater opportunity for beneficial mechanotransduction regenerative mechanisms. This is due, in part, to increased intracavernosal pressure and tissue volume with larger blood-filled lacunar spaces during erection. LiSWT to treat erectile dysfunction should be more effective when performed in the erect state.

Conclusion: In low-intensity shockwave therapy treatment of the penis much of the applicator's focal zone may extend past the body. The targeted use of a reflector may potentially improve clinical outcomes by i) reducing tissue stress due to tensile forces and potential damaging cavitation effects, and ii) enhancing the size of the treatment volume of a single pulse by refocusing the tertiary wave in rapid succession of the main treatment pulse, resulting in a potentially enhanced therapeutic efficacy.

Figure 1

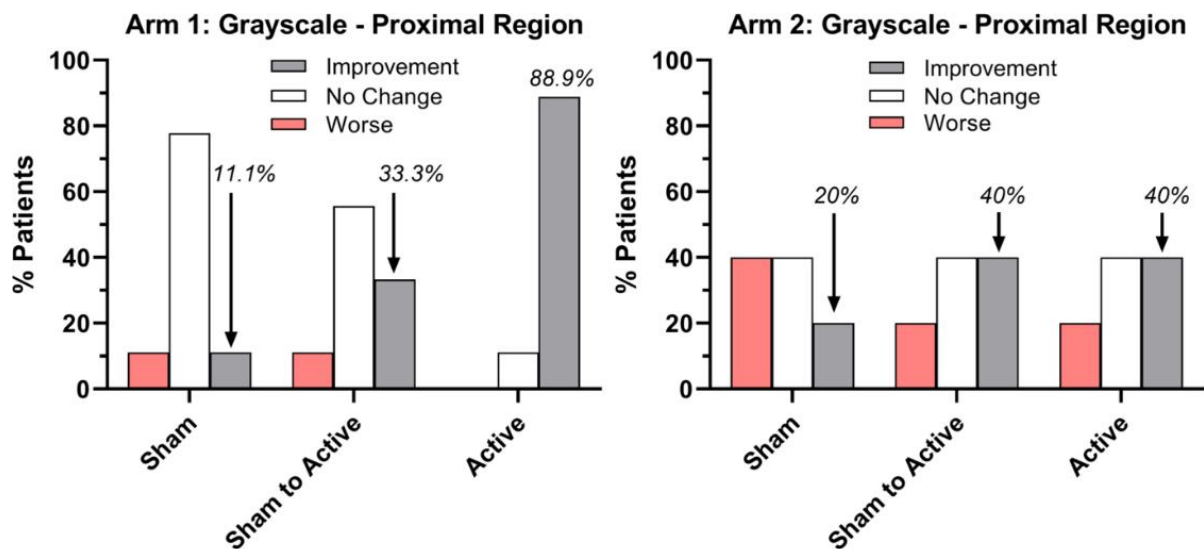


Figure 2

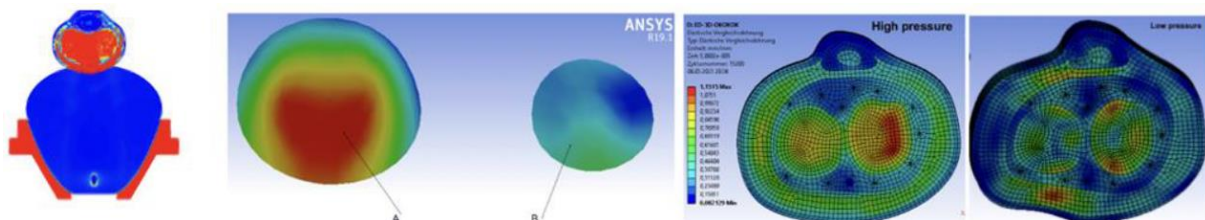
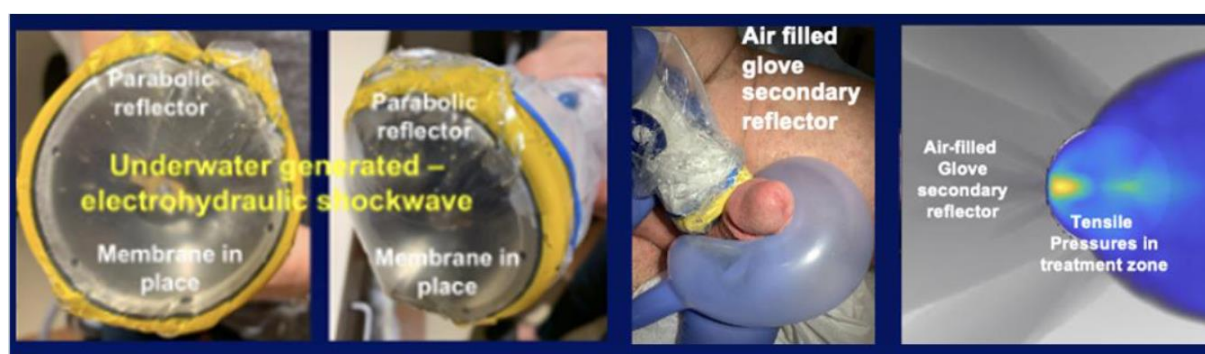

Figure 1. FEM calculation model. Figure 2. Energy absorbed in (a) erect and (b) flaccid penis. Figure 3. Effect of pressure.

Figure 3



25th ISMST Congress Daegu, Korea, 2023. Keynote Day 1.

Study Performance: **uroGold100** applicator OP155

3.2.7. A Sham-Controlled Randomized Trial of Low Intensity Shockwave Therapy for Erectile Dysfunction (Goldstein et al., 2023)

San Diego Sexual Medicine, Sexual Medicine, San Diego, USA.

INTRODUCTION AND OBJECTIVE:

We performed a sham-controlled, randomized prospective trial in men with ED using an electrohydraulic shockwave device FDA cleared for connective tissue activation and improved blood flow.

METHODS:

This single-blind study was performed in men with ED naïve to acoustic wave and shockwave therapy. Patients were randomized to treatment and assigned to active low intensity shockwave therapy (LiSWT) (4 Hz, 0.12 mJ/mm²) or sham treatment, 2:1. Arm 1 consisted of 3 treatments of 5000 shocks every 3 weeks. Arm 2 consisted of 5000, 3000, and 3000 shocks during weeks 1, 2, and 3, respectively, followed by an identical cycle of treatment 3 weeks later. Doppler ultrasound and grayscale imaging with a 15.4 MHz probe were performed under pharmacologic erection at weeks 20 and 32. Subjects completing sham treatment were unblinded and crossed over to the opposite arm for active treatment. Post-treatment end diastolic velocity (EDV) and peak systolic velocity (PSV) were measured, and visual grading scores were used to assess extent of hypoechoic regions in the corpora cavernosa. Data were analyzed by 2-way repeated measures ANOVA with Geisser-Greenhouse correction. Pairwise comparisons were performed to baseline used Dunnett's multiple comparison test. Missing data were imputed by "last observation carried forward".

RESULTS:

Although powered for 60, recruitment was limited due to COVID and 36 subjects (22 active, 14 sham) were randomized. Sham treatments showed no significant changes in outcome measures. The number of subjects with improved visual grading scores in the proximal region was consistently higher in active LiSWT vs sham (Arm 1=88.9% vs. 11.1%; Arm 2=40.0% vs. 20.0%, respectively) with statistical significance in Arm 1 at weeks 20 (p=0.005) and 32 (p=0.001). Sham subjects rolled over to active LiSWT also had improved grayscale ratings (Arm 1=33.3% vs. 11.1%; Arm 2=40.0% vs. 20.0%). After LiSWT, greater numbers of patients had higher PSV, lower EDV, or no worsening of blood flow parameters relative to baseline. Decrease in EDV was statistically significant in active treatment Arm 2 at Week 32 (p=0.003). Mean IIEF-EF scores were nominally higher in subjects in active treatment who had improved visual grading scores vs those with no improvement. Adverse events were transient.

CONCLUSIONS:



Flaccid penile LiSWT appears to be safe and efficacious for treating ED based on statistically significant changes from baseline between sham and active treatments in primary outcome measures.

AUA Congress Chicago, USA, 2023. Abstract No. MP79-11.

Study Performance: **urogold100** applicator OP155

3.2.8. Interim Analysis of a Sham-Controlled Randomized, Prospective Study Using Low Intensity Shockwave Therapy (LiSWT) for Improvement of Erectile Dysfunction (Goldstein et al., 2022)

San Diego Sexual Medicine, Sexual Medicine, San Diego, USA.

keywords: low intensity shockwave therapy, erectile dysfunction, grayscale, hypoechoic regions, corpora cavernosa.

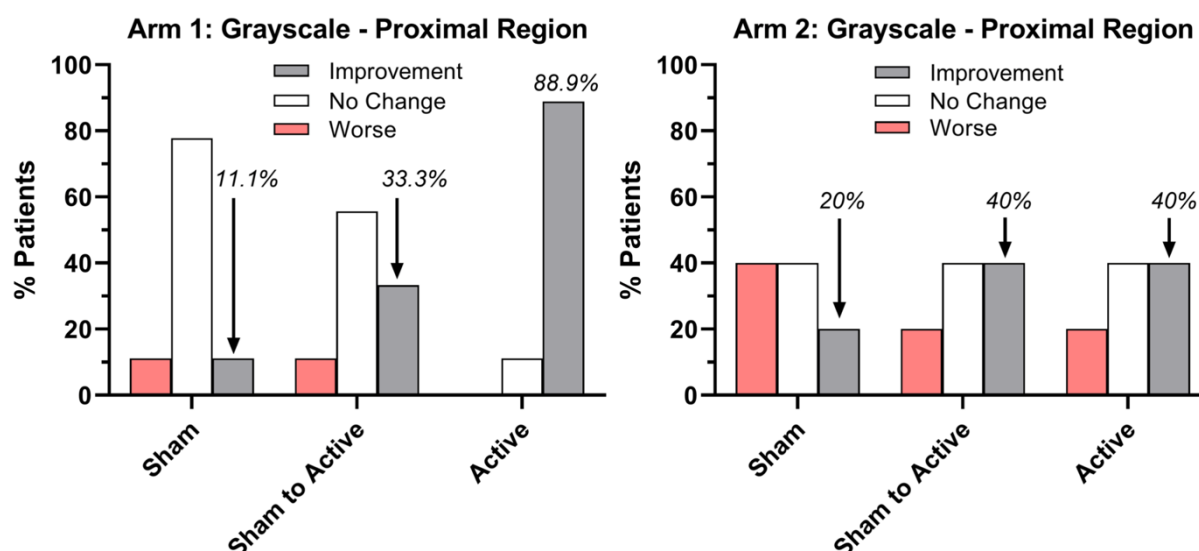
Introduction: The Urogold 100 MTS™ electrohydraulic shockwave device is FDA cleared for improved blood flow and connective tissue activation; retrospective studies in ED patients have shown positive outcome.

Objective: To perform an interim analysis of sham/active treatment changes in primary outcome measures of grayscale ultrasound and DUS.

Methods: A single-blind, sham-controlled, randomized, prospective study in men with ED naïve to acoustic wave therapy was performed. Those meeting inclusion/exclusion were randomized to one of two treatment arms and assigned to active or sham, 2:1 within each arm. Arm 1 consisted of three treatments of 5000 shocks every three weeks, 4 Hz, 0.12 mJ/mm²; arm 2 consisted of 5000, 3000 and 3000 shocks, 4 Hz, 0.12 mJ/mm²; weeks one, two and three respectively, three weeks without treatment, then repeat treatments every three weeks. First follow-up was 20 weeks after initial treatment; DUS and grayscale imaging using a 15.4 MHz probe were repeated under pharmacologic erection 3-4/4 hardness. Post-treatment grayscale percent hypoechoic regions within the corpora cavernosa were assessed: none (0), mild (1), moderate (2) and severe (3) and compared to baseline. Post-treatment EDV and PSV were compared to baseline. Upon completion subjects were unblinded. Subjects assigned to sham were crossed over to the opposite arm for active treatment. Subjects initially in active treatment underwent a second follow-up 32 weeks after initial treatment. Data from each treatment arm were analyzed by two-way repeated measures ANOVA with Geisser-Greenhouse correction. Follow-up pairwise comparisons to baseline were performed using Dunnett's multiple comparison test. In subjects with one on-treatment assessment, missing data due to early discontinuation from the study were imputed by the "last observation carried forward" method.

Results: Powered for 60 subjects, recruitment was stopped (COVID) after randomizing 36 subjects (22 active, 14 sham). The proximal penis exhibited greatest improvement (decreased heterogeneity score) on grayscale. The number of subjects with improved erectile tissue grayscale ratings in the proximal region was consistently higher in active treatment versus sham groups (Arm 1 = 88.9% vs. 11.1%; Arm 2 = 40.0% vs. 20.0%, respectively). Sham subjects rolled over to active LiSWT also had improved grayscale ratings (Arm 1 = 33.3% vs. 11.1%; Arm 2 = 40.0% vs. 20.0%). Change in heterogeneity was statistically significant for the proximal region in active treatment Arm 1 at both Week 20 (p=0.005) and Week 32 (p=0.001). Mean IIEF-EF scores were nominally higher in subjects in active treatment with improved grayscale ratings versus those with no improvement on grayscale. Concerning penile blood flow, improvement after LiSWT greater numbers of patients had higher PSV or lower EDV relative to baseline; greater numbers of patients had no worsening in blood flow parameters. Decrease in EDV reached statistical significance in active treatment Arm 2 at Week 32 (p=0.003). Adverse events were transient.

Conclusion: Flaccid penile LiSWT appears to be safe and efficacious for treating ED based on statistically significant changes between sham and active treatments in primary outcome measures grayscale ultrasound and DUS.



Keypoints:

This single-blind, sham-controlled, randomized study in men with ED naïve to acoustic wave therapy stopped early due to COVID. Thirty-six subjects were randomized to one of two treatment arms, assigned 2:1 to active or sham. This interim analysis examined changes from baseline in the primary outcome measures of grayscale ultrasound and DUS in both sham and active treatment arms. In general, the proximal penis exhibited greatest improvement (decreased heterogeneity score) on grayscale. The number of subjects with improved erectile tissue grayscale ratings in the proximal region was consistently higher in active treatment versus sham. Decrease in EDV reached statistical significance in active treatment Arm 2 at Week 32 ($p=0.003$). All adverse events were transient. Flaccid penile LiSWT appears to be safe and efficacious for treating ED based on statistically significant changes between sham and active treatments in the primary outcome.

23rd Annual Fall Scientific Meeting of SMSNA and 23rd ISSM Scientific Meeting, Miami, FL, USA. Abstract No. 129.

Study Performance: **urogold100** applicator OP155

3.2.9. Novel Low Intensity Shockwave Therapy Sham Delivery Method (Zero Energy) Assessed Objectively by Grayscale and Doppler Ultrasound Results (Goldstein et al., 2022)

San Diego Sexual Medicine, Sexual Medicine, San Diego, USA.

keywords: low intensity shockwave therapy, sham control, grayscale, erectile tissue heterogeneity, histometry.

Introduction: Most ED LiSWT studies use the IIEF as a primary outcome. While clinically relevant, the IIEF does not directly assess erectile tissue structure. To establish a more objective parameter, we investigated the estimation of hypoechoic area in grayscale ultrasound images of erectile tissue as an objective primary outcome for clinical trials assessing the efficacy of LiSWT. During erection, grayscale imaging of the penis demonstrates corpora cavernosa (CC) that is homogenous in healthy men and heterogeneous to varying degrees in men with ED. A critical aspect of using grayscale ultrasound is to



determine that sham treatment reliably results in no significant improvement in erectile tissue structure. Other studies have used sham probes with cotton wadding or non-penetrable gel pads to dampen delivery of shockwave energy flux density, however a small amount of energy may still be delivered. We report a novel sham-controlled methodology in LiSWT RCT for ED.

Objective: To evaluate erectile tissue heterogeneity as an endpoint in LiSWT sham-controlled trials using grayscale analysis of percent hypoechoic regions in CC after sham delivery of zero energy flux density.

Methods: A single-blind, sham-controlled, randomized prospective study was performed in men with ED naïve to any kind of acoustic wave therapy. Those meeting inclusion/exclusion completed baseline assessments and were randomized to active or sham within each treatment arm. This interim sub-analysis only examined the sham group ($n = 7$). For each treatment, the shockwave device was already on in the exam room. When the subject was ready a curtain was suspended above his mid-section blocking the device, and noise cancelling headphones provided. When the probe was placed on the penis, a high-quality recording of shockwave sounds was activated for sham treatment. Twenty weeks after zero energy sham treatment, grayscale and DUS imaging using a 15.4 MHz probe under pharmacologic erection 3-4/4 hardness was performed before unblinding. Grayscale percent hypoechoic regions within the CC were assessed by computer-assisted histometry using Image J. (Fig 1) The IIEF was also administered to all patients at baseline and week 20. Grayscale data were analyzed by two-way repeated measures ANOVA. IIEF-EF scores and blood flow values (PSV and EDV) were compared using the Wilcoxon matched-pairs signed rank test.

Results: Compared to baseline, there were no significant changes ($p > 0.7$; see figure) at week 20 in hypoechoic area in the proximal, middle, and distal erect penile shaft. (Fig 2) Furthermore, there were no significant changes in PSV ($p > 0.15$), EDV ($p > 0.2$), or IIEF-EF ($p > 0.6$) from baseline to week 20.

Conclusion: Using computer-assisted histometry to determine hypoechoic area in grayscale ultrasound images to assess penile erectile tissue heterogeneity, we demonstrated that a novel sham treatment protocol that ensures zero energy delivery does not change erectile tissue integrity. The lack of improvement in PSV, EDV, and IIEF-EF further support our findings with grayscale ultrasound. Future studies will assess the appropriateness of grayscale ultrasound image analysis as a primary endpoint in LiSWT clinical trials.

Keypoints:

We evaluated sham delivery (zero energy flux density) on erectile tissue heterogeneity as an endpoint in low intensity shockwave therapy (LiSWT) trials using grayscale analysis of percent hypoechoic regions in corpora cavernosa (CC). Most ED LiSWT studies use IIEF as primary outcome, not directly assessing erectile tissue structure. Grayscale imaging of the penis during erection demonstrates CC homogeneity in healthy men and heterogeneity to varying degrees in men with ED. This single-blind, sham-controlled, randomized prospective studied men with ED naïve to acoustic wave therapy. Using computer-assisted histometry Image J, we calculated percent hypoechoic regions in CC at baseline and week 20 in the sham group ($n = 7$). Compared to baseline, there were no significant changes at week 20 in hypoechoic area in the proximal, middle, and distal erect penile shaft, or PSV, EDV, or IIEF-EF with zero energy delivery.

23rd Annual Fall Scientific Meeting of SMSNA and 23rd ISSM Scientific Meeting, Miami, FL, USA. Abstract No. 123.

Study Performance: **urogold100** applicator OP155

3.2.10. Post-Finasteride Induced Erectile Dysfunction: Diagnosis by Grayscale / Doppler Ultrasound and Disease Modification Treatment with Erect Penile Extracorporeal Shockwave Therapy (Goldstein et al., 2022)

San Diego Sexual Medicine, Sexual Medicine, San Diego, USA.

Introduction

Finasteride (1 mg), a 5-alpha reductase inhibitor that lowers dihydrotestosterone, is approved for treatment of male pattern hair loss, androgenic alopecia. Persistent sexual side effects have been reported following discontinuation of finasteride, including erectile dysfunction (ED). It has been postulated that post-finasteride induced ED is, in part, due to cavernosal smooth muscle cell apoptosis as a sequela of low serum dihydrotestosterone. Khera et al (2020) reported persistent penile vascular changes in 25 men after discontinuation of finasteride. The purpose of this study was to replicate Khera's findings in a larger population and examine treatment of those patients with post-finasteride induced ED using ESWT.

Material & Method

A chart review (2015-2020) was performed. Our patient population had normal sexual function prior to finasteride use and experienced changes within 6 months of discontinuation of finasteride which persisted > 6 months. Information collected included sexual function history, current symptoms, validated instruments, hormone blood test values, data from grayscale/Doppler ultrasound during pharmacological erection (15.4 MHz probe; Aixplorer® Ultrasound) and data from erect penile ESWT treatment with UroGold 100 MTS.

Results

91 patients (median age 39) met inclusion criteria, 9.6 % of men evaluated during this period. The most common symptom was ED in 95 % (87/91). Mean IIEF-EF score was 14 ± 8.63 ($n = 81$), consistent with severe (43 %), mild-moderate (23 %), moderate (12 %), and mild (10 %) ED. Of the 57 who underwent grayscale/Doppler ultrasound, 77 % exhibited abnormal erectile tissue inhomogeneity. Mean cavernosal artery PSV/EDV values ($n = 61$) were left $30.4 \pm 18.02/0.76 \pm 2.86$ cm/sec and right $29.63 \pm 14.97/0.60 \pm 1.89$ cm/sec, respectively. These data support that erectile tissue damage occurs in the corpora cavernosa after discontinuation of finasteride. A total of 6 LiSWT were performed on the erect penis (erection hardness 3–4/4) in 18 (32 %) of these men as a disease modification management option for their post-finasteride induced ED. A total of 3600 shocks per treatment, energy flux density 0.13 mJ/mm², 3 Hz, membrane pressure 1 using UroGold 100 MTS. After completion of the 6th treatment cycle of ESWT, grayscale/Doppler ultrasound was repeated. 58 % exhibited improved erectile tissue homogeneity, (61 %) patients had PSV increase, (32 %) had EDV decrease and 65 % reported improvement in Patient Global Impression of Improvement.

Discussion

In a large series of men with persistent ED after discontinuation of finasteride, ESWT has been shown to provide improvement in erectile tissue homogeneity, PSV and EDV, therefore improving the quality of erection in this otherwise difficult to treat population men.

24rd World Congress of the ISMST 2022 in Prague, Czech Republic, oral presentation ISMST22-0073.

Study Performance: **urogold100** applicator OP155.

3.2.11. Interim Analysis of a Sham-Controlled Randomized, Prospective Study Using Low Intensity Shockwave Therapy (LiESWT) for Improvement of Erectile Function (Goldstein et al., 2022)

Alvarado Hospital, United States of America.



Introduction: The Urogold 100 MTS™ electrohydraulic shockwave device is FDA cleared for improved blood flow and connective tissue activation; retrospective studies in ED patients have shown positive outcome data.

Objective: To perform an interim analysis of sham and active treatment changes in primary outcome measures of grayscale ultrasound and DUS.

Methods: A single-blind, sham-controlled, randomized, prospective study in men with ED naïve to LiSWT was performed. Those who met inclusion/exclusion were randomized to one of two treatment arms and assigned to active or sham, 2:1 within each arm. Arm 1 consisted of three treatments of 5000 shocks every three weeks, 4 Hz; arm 2 consisted of 5000, 3000 and 3000 shocks, 4 Hz, weeks one, two and three respectively, three weeks without treatment, then repeat treatments every three weeks. First follow-up was 20 weeks after initial treatment; DUS and grayscale imaging using a 15.4 MHz probe were repeated under pharmacologic erection 3-4/4 hardness. Post-treatment grayscale percent hypoechoic regions within the corpora cavernosa were assessed: none (0), mild (1), moderate (2) and severe (3) and compared to baseline. Post-treatment EDV and PSV were compared to baseline. Upon completion the subject was unblinded. Subjects assigned to sham were crossed over to the opposite arm for active treatment. Subjects initially in active treatment underwent a second follow-up 32 weeks after initial treatment. Data from each treatment arm were analyzed by two-way repeated measures ANOVA with Geisser-Greenhouse correction. Follow-up pairwise comparisons to baseline were performed using Dunnett's multiple comparison test. In subjects with one on-treatment assessment, missing data due to early discontinuation from the study were imputed by the "last observation carried forward" method.

Results: Originally powered for 60 subjects, recruitment was stopped due to COVID after 36 subjects were randomized (22 active, 14 sham). In general, the proximal penis exhibited greatest improvement (decreased heterogeneity score) on grayscale. The number of subjects with improved erectile tissue grayscale ratings in the proximal region was consistently higher in active treatment versus sham groups (Arm 1 = 88.9% vs. 11.1%; Arm 2 = 40.0% vs. 20.0%, respectively). Sham subjects rolled over to active LiSWT also had improved grayscale ratings (Arm 1 = 33.3% vs. 11.1%; Arm 2 = 40.0% vs. 20.0%). Change in heterogeneity was statistically significant for the proximal region in active treatment Arm 1 at both Week 20 ($p=0.005$) and Week 32 ($p=0.001$). Mean IIEF-EF scores were nominally higher in subjects in active treatment with improved grayscale ratings versus those with no improvement on grayscale. While the data were more variable for penile blood flow, improvement after LiSWT was characterized by either greater numbers of patients having higher PSV or lower EDV relative to baseline; or greater numbers of patients having no further worsening in blood flow parameters. Decrease in EDV reached statistical significance in active treatment Arm 2 at Week 32 ($p=0.003$). All adverse events were transient.

Conclusion: Flaccid penile LiSWT appears to be safe and efficacious for treating ED based on statistically significant changes between sham and active treatments in primary outcome measures grayscale ultrasound and DUS.

23rd Annual Fall Scientific Meeting of SMSNA / 23rd ISSM Scientific Meeting in Miami, FL, USA. Abstract No.

Study Performance: **urogold100** applicator OP155

3.2.12. Retrospective Comparison of Focused Shockwave Therapy and Radial Wave Therapy for Men with Erectile Dysfunction (S. S. Wu et al., 2020)

Department of Urology, Cleveland Clinic Foundation, Glickman Urological and Kidney Institute, Cleveland, OH, USA.

Background: Low-intensity shockwave therapy (SWT) is an emerging treatment for erectile dysfunction (ED). Devices used for SWT include focused shockwave therapy (fSWT) or radial wave therapy (rWT), which differ in how the waves are generated, their tissue penetration, and the shape of their pressure waves. Most studies of SWT for ED to date have utilized fSWT. Although widely used, the efficacy of rWT for ED is unknown. Our objective is to compare the efficacy of rWT and fSWT for ED at our institution.

Methods: A retrospective chart review was performed to identify all men with ED treated by fSWT or rWT. Men with history suggesting non-vasculogenic ED were excluded. All men received 6 consecutive weekly treatments. The fSWT group received 3,000 shocks per treatment at 0.09 mJ/mm². The rWT group received 10,000 shocks per treatment at 90 mJ and 15 Hz. Pre-treatment and 6-week post-treatment Sexual Health Inventory in Men (SHIM) scores were measured. Treatment response was categorized on a scale of 1–3 (1 if no improvement, 2 if erections sufficient for intercourse with phosphodiesterase 5 inhibitors (PDE5i), or 3 if sufficient erections without PDE5i). Primary endpoint was self-reported improvement score of 2 or greater.

Results: A total of 48 men were included: 24 treated by fSWT and 24 by rWT. There were no significant differences in age, duration of ED, pre-treatment PDE5i use, or pre-treatment SHIM scores between the groups. Following treatment with rWT, the mean SHIM score improved from 9.3 to 16.1 (P<0.001). The mean SHIM following fSWT improved from 9.3 to 15.5 (P<0.001). The mean improvement in SHIM score did not differ between rWT (6.8) and fSWT (6.2) (P=0.42). 54% of men treated by fSWT experienced a significant clinical improvement (≥ grade 2 response) compared to 75% in the rWT group (P=0.42). There were no reported side effects with either device.

Conclusions: In our patient population, both fSWT and rWT were moderately effective treatments for arteriogenic ED with no observable difference in efficacy between the two modalities.

Study Performance: **urogold100**

3.2.13. Proposed Mechanisms of Erectile Function Improvement with Low Intensity Shock Wave Therapy: Vascular and Erectile Tissue Health Changes Pre- and Post-Treatment (Yih et al., 2020)

San Diego Sexual Medicine, San Diego, CA.

Introduction: Although Low Intensity Shockwave Therapy (LiSWT) for erectile dysfunction (ED) has been widely used as a non-invasive disease modification strategy, the mechanisms for erectile function (EF) improvement need further elucidation.

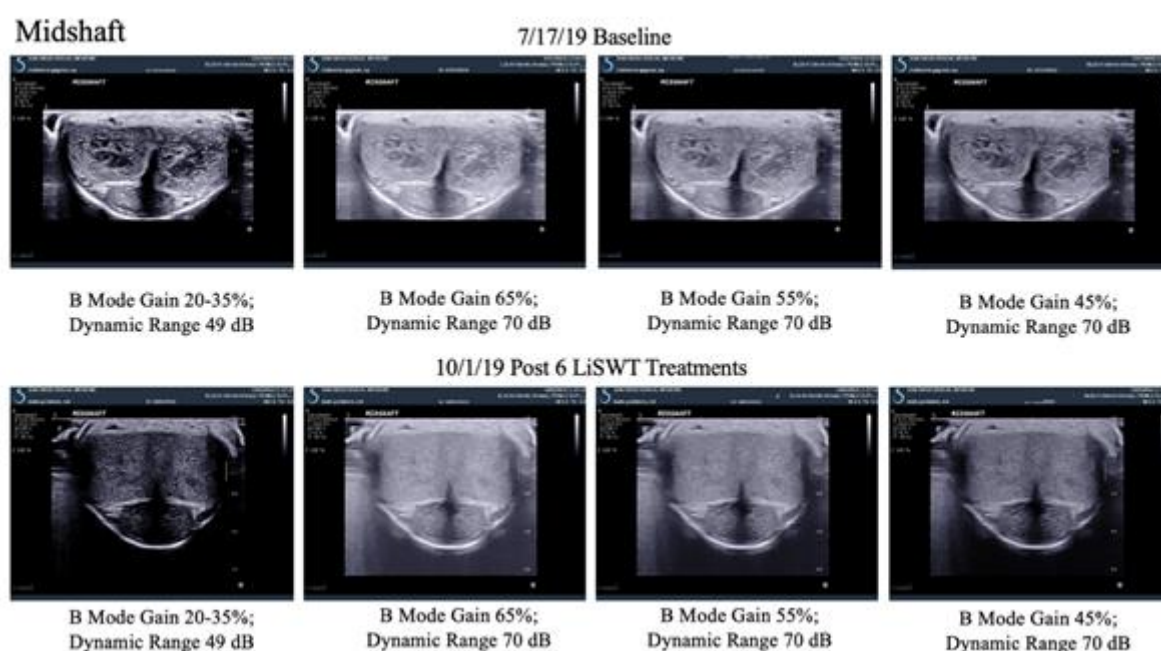Objective: The goal was to enhance understanding of proposed vascular mechanisms of EF improvement by objectively examining blood flow and erectile tissue health parameters in ED patients prior to and following LiSWT.

Methods: This was a retrospective chart review of men with ED who underwent ≥ 6 LiSWT treatments (Urogold 100 MTS) over a 12-month period, underwent baseline and post-treatment grayscale and Doppler ultrasound (GDUS), and completed a patient global impression of improvement (PGI-I) after treatment. Typical LiSWT treatment parameters involved 600 shocks each to dorsal, ventral, right/left lateral penile shaft, right/left crura during erection using the parabolic reflector probe (OP-155), energy flux density 0.13mJ/mm², 3 Hz, membrane pressure 3. A pharmacologic erection with erection hardness score sustained at 3-4 /4 was achieved for the GDUS. B-mode ultrasound (Aixplorer 15.4 MHz transducer) was performed with predetermined settings to avoid reader bias. Four images were captured in the axial plane from the dorsal penile surface at the proximal penile shaft at a fixed dynamic range of 70 dB with three B-mode gain values of increased brightness: 45%, 55% and 65%. Then the dynamic range was lowered to 49 dB and B-mode gain identified (25% - 35%) that provided



the best black/white grayscale discrimination. This was repeated at the midshaft and distal penile shaft, yielding 12 cross sectional images/patient. Erectile tissue homogeneity/inhomogeneity of proximal, midshaft and distal cross-sectional areas were determined as follows: normal grayscale had no inhomogeneity (hypo- or hyper-echoic regions); mild inhomogeneity <25%, moderate inhomogeneity 25% - 50%, and severe inhomogeneity >50% hypo- or hyper-echoic regions respectively. De-identified images were read by two experienced readers reaching consensus regarding degree of absent or present hypo- or hyper-echoic regions. Measurements of right/left cavernosal artery peak systolic velocity (PSV) and cavernosal artery right/left end-diastolic velocity (EDV) values were recorded.

Results: 31 patients met inclusion criteria. 18/31 (58%) patients had improved erectile tissue homogeneity post-LiSWT from baseline, 4/31 (13%) remained the same and 9/31 (29%) worsened. 12/31 had improved erectile tissue homogeneity in the proximal section, 12/31 in the distal section although not the same 12, and 14/31 in the midshaft. 22/31 patients (71%) rated PGI-I as improved and 11/18 (61%) of patients who expressed improvement on PGI-I had GDUS evidence of erectile tissue improvement. Of those with baseline pre- and post- PSV and EDV measurements, 19/27 (70%) patients had an increase in PSV measurement and 8/27 (30%) had a decrease in EDV measurement. Mean PSV increase was 13.06 cm/s and mean EDV decrease was 2.48 cm/s. 9 patients with EDV of 0 cm/s pretreatment remained unchanged. The figure below shows improved erectile tissue homogeneity in the midshaft comparing baseline severe inhomogeneity to post-treatment mild inhomogeneity.



Conclusion: This study shows that the mechanisms by which LiSWT for ED improves, in part, erectile function involve enhanced erectile tissue health, increased cavernosal arterial peak systolic velocity and decreased end-diastolic velocity.

21st Annual Fall Scientific Meeting of Sexual Medicine Society of North America (SMSNA), Abstract No.092.

Study Performance: **urogold100**

3.2.14. Review of the Current Status of Low Intensity Extracorporeal Shockwave Therapy (Li-ESWT) in Erectile Dysfunction (ED), Peyronie's Disease (PD), and Sexual Rehabilitation

After Radical Prostatectomy with Special Focus on Technical Aspects of the Different Marketed ESWT Devices Including Personal Experiences in 350 Patients (Porst, 2020)

European Institute for Sexual Health (EISH), Hamburg, Germany.

Introduction: Although the literature of the positive effects of penile low intensity extracorporeal shockwave therapy is meanwhile substantial, there are substantial differences regarding both the sources of energies and extracorporeal shockwave therapy (ESWT) devices.

Objectives: To provide an overview on the energy range and energy differences of the 6 currently marketed ESWT devices along with personal ESWT experiences in 350 patients.

Methods: This review includes all published preclinical and clinical penile ESWT studies with evaluation of the technical differences of the 6 ESWT devices and the personal experiences with these 6 devices in ED and PD. The main outcomes measures were success rates in ED (International Index of Erectile Function-erectile function change, conversion of phosphodiesterase type 5 inhibitors non-responders) and PD (change in deviation and plaque size), differences of used sources of energy, and energy flux densities (EFDs).

Results: 3 different sources of energies are used, that is electromagnetic, electrohydraulic, and piezoelectric. The devices markedly distinguish in the available spectrum of the EFD ranging between 0.09 and 0.55 mJ/mm². In terms of the biological effects, the relevant energy parameters are -6 dB and the 5 MPa focus, which differ substantially between the ESWT devices. In addition, a great variability in the treatment protocols and applied energy is obvious. The preliminary own experiences with low intensity extracorporeal shockwave therapy in 160 ED non-responders and 190 patients with PD with success rates of 45% and 47%, respectively, are reported.

Conclusion: Positive results were published with all 6 ESWT devices in question in patients with organic ED but with huge differences regarding the EFD and the total energies applied. There is growing evidence that concentrated treatment protocols and increasing energies may yield better results. In this context, it may be argued that at least some of the published studies were markedly underpowered. Owing to the paucity of published studies, the literature of the effects of ESWT in PD and for penile rehabilitation after pelvic surgery is currently not conclusive.

Study Performance: **urogold100**

3.2.15. Retrospective Review of Improvement of Erectile Dysfunction after Low-Intensity Shockwave Treatment with Urogold100 (Yih et al., 2020)

San Diego Sexual Medicine, San Diego, CA.

Introduction: Erectile dysfunction (ED) can result from insufficient arterial blood inflow and/or from veno-occlusive dysfunction from reduced erectile tissue expandability secondary to erectile tissue fibrosis. Non-surgical strategies to manage ED in the United States (US) are primarily symptomatic based, such as PDE5 inhibitors and/or intracavernosal injections. In Europe, disease modification strategies such as Low Intensity Shockwave Treatment (LiSWT) using energy levels 0.09 – 0.12 mJ/mm² have shown, in multiple sham-controlled prospective studies, significant improvement in both ED outcome measures and blood inflow. The European Urological Association lists Li-SWT as a recognized ED treatment. The Urogold 100™ is an electrohydraulic shockwave device that generates energy levels such as 0.09 – 0.12 mJ/mm² with a unique parabolic reflector. It is FDA-cleared for improved blood flow and connective tissue activation as non-significant risk in humans.

Objectives: The objective was to perform a single site retrospective chart review of the outcome of ED treatment with the Urogold 100™ shockwave device.



Methods: Patients presenting with ED were offered the opportunity to receive shock wave therapy as a potential treatment for their ED as part of patient care or in a clinical trial. As standard of care, patients at baseline completed the International Index of Erectile Function (IIEF), the sexual distress scale (SDS), and Grayscale and Doppler ultrasound. LiSWT treatment protocol involved 6 treatment sessions of 5000 total shocks each (500 right/left hilum, 1000 right/left penile shaft, and 1000 right/left crus), frequency 4/sec, membrane level 1. The energy varied from 0.10 – 0.12 mJ/mm², based on patient toleration. Patients were asked in follow-up about their response, recorded as Patient Global Impression of Improvement (PGI-I), on a scale of 1 – 7 with clinically relevant improvement expressed by scores of 1 – 3.

Results: To date, data have been collected on 40 ED patients, mean age 45 years (range 25 – 72). Baseline IIEF domain scores for Erectile Function, Orgasm, Desire, Intercourse Satisfaction and Sexual Satisfaction were 14.5, 6.2, 6.6, 7.1, and 4.2 respectively. Baseline mean sexual distress scale score was 30.7/52. Baseline Grayscale ultrasound, used to assess erectile tissue homogeneity in the proximal, mid-shaft and distal aspects of the penile shaft, revealed minimal (25%-50%) and severe (>50%) erectile tissue inhomogeneity in 22/40 (55%), 13/40 (33%) and 5/40 (12%), respectively. Post-treatment, 25/40 (63%) of patients reported a PGI-I of 1 – 3. These patients had baseline erectile tissue homogeneity of 18/25 (72%), 6/25 (24%) and 1/25 (4%), respectively. No treatment related side effects were noted.

Conclusions: In this US-based LiSWT retrospective study, the Urogold 100™ shockwave device has shown clinically relevant improvement in 63% of men with ED, based on self-report. Preliminary studies show that minimal erectile tissue homogeneity has a higher likelihood of positive treatment outcome with shockwave therapy. Only 1 patient with severe inhomogeneity showed improvement. An IRB approved sham-controlled prospective 2 arm 40-week clinical trial using Urogold 100™ shockwave device with all subjects undergoing baseline and post-treatment Grayscale and Doppler ultrasound to assess objective erectile function changes is currently underway.

Study Performance: **urogold100**

3.2.16. First Report for Unfocused Li-eswt for Nocturia and Erectile Dysfunction (Sharpe et al., 2019)

Georgia Urology, Atlanta, USA.

Introduction and Objective: Nearly 350 Shockwave Therapy (SWT) devices have been sold in the USA for Erectile Dysfunction (ED) since 2007 - with at least 250,000 patients treated. The vast majority of treatments have been performed with inexpensive radial/ballistic SWT devices by non-urologists (primarily by chiropractors). Annually, many millions of dollars have been spent on advertising (primarily AM radio) to recruit ED patients to these clinics. The fee for a series of 6 – 10 treatments by non-urologists averages \$4000. During last year's ISSM Congress in Lisbon, invited speakers from the Mayo Clinic estimated the overall "success" rate for these ED clinics at "about 50%". Monthly, our network of urology offices receives hundreds of inquiries from our patients regarding this technology (most inquiries driven by the frequent radio advertisements, at least 8 each hour on Atlanta's largest AM station). To respond to our patient's inquiries, and to answer our own questions, we initiated an IRB study to evaluate this technology. This is the first report for unfocused, electrohydraulic SWT (or any form of shockwaves) for Nocturia and for ED. Multiple publications confirm that a primary mechanism of action of SWT for urologic and sexual health indications is a shockwave's unique ability to recruit a patient's own stem cells to the targeted/treated area (not yet proven for radial/ballistic acoustic pulse therapy). The objective of this study was to evaluate the effectiveness and safety of unfocused, electro-hydraulic SWT "SoftWaves" for ED. The results of this study, and a review of the

literature, will determine whether we offer this technology to our patients through our network of 40 urologists and 30 offices.

Methods: All patients (15) were consented per the IRB and evaluated to confirm the ED diagnosis and screened for prostate cancer (PSA or digital or ultrasound screening). Patient's ages ranged from 54 to 80 (64 average). Each patient was treated once a week. Utilizing the UroGold SWT device (Distributed by TRT, Woodstock, GA., www.trtllc.com; and manufactured by MTS Germany) - 6 treatments per patient were applied over an average of 8 weeks. The average treatment required 2000 pulses. SWT was evenly divided between 3 treatment sites on the patient's shaft, crura, and perineum. Treatment times averaged less than 15 minutes. After an average of 12 weeks from the first treatment, patients were asked to complete the post treatment questionnaire which asked the patient to report their % improvement on a scale of 0 to 100%, with 100% representing a return to normal erectile function. Patients paid \$1500 each to participate in the study.

Results: Average improvement for the ED group was 47% (range of 0 – 100%); 12/14 showed at least 40% improvement (86%); 14/15 showed some improvement. All patients reported that they wanted to continue the protocol and would pay for more treatments. No pain was reported. No numbing cream was utilized. During the weekly evaluations of the ED patients, very interesting observations were made by multiple patients. As early as week 2, several patients reported that they urinated less frequently at night and attributed this improvement to the SWT. Post study, we collected data from all of the patients that complained of Nocturia who were enrolled in the study (11). We can report the first ever results for SWT and Nocturia. 8/11 (73%) patients reported the reduction in the number of night time urinations of at least 50%. Three (3) patients decreased bathroom visits from 6 to 1 times per night. The average decrease in bathroom visits was 64%. Most interesting, patients reported these improvements in the early weeks, whereas ED symptoms improved much later (average 3 vs. 10 weeks).

Conclusions: All results are statistically significant and no adverse events reported. Based on these results, an exhaustive review of the literature, and the recent FDA Clearance of the device; our practice has determined that we will offer this technology to our patients.

22th ISMST Congress in Beijing, China.

Study Performance: **urogold100**

3.2.17. Case Series of Weekly Low Intensity Shockwave Therapy for Erectile Dysfunction (Shoskes et al., 2017)

Cleveland Clinic, United States.

Background & Aim: Low Intensity Shock Wave (LiSW) has emerged as a therapy for vasculogenic erectile dysfunction (ED). Mechanism may be related to angiogenesis, release of growth factors and/or recruitment of stem cells. Several sham controlled studies have shown improvement in peak arterial velocity and efficacy in the 60-65% range depending on the definition. The initial protocol of twice weekly treatments for 3 weeks with a rest period and repeat has remained the standard, although this can be very inconvenient for patients. We wished to study the efficacy and safety of LiSW using a modified protocol of 4 weekly treatments.

Methods: Men were enrolled in this IRB approved study provided they had a diagnosis of ED for at least 6 months and were able to return for weekly treatments. Low Intensity Shockwave was delivered with the Urogold 100 machine (Tissue Regeneration Technologies, Woodstock, GA) using the soft wide focused applicator probe (figure 1). There were 6 treatment sites: one at each crus of the penis and 2 on the shaft bilaterally with about 500 shocks each for a total of 3000 shocks. Energy flux was 0.13



mJ/mm² and frequency was 4 Hz. ED severity was measured with the Sexual Health Inventory for Men (SHIM) score at baseline and 1 month following the 4 weekly treatments. Pre and post SHIM values were compared with the paired t test with significance set at $p < 0.05$.

Results: Eight men enrolled with a mean age of 56.8 years (range 26-70) and median duration of 36 months (range 12-120). Five had previously tried PDE5 inhibitor (PDE5i) oral medications without adequate success. One patient stopped after 3 treatments but was included for an intent to treat analysis. The treatments were painless and there were no side effects. Overall, SHIM score improved from 11.0 ± 3.6 to 17.2 ± 5.2 ($p = 0.01$). SHIM was unchanged in 2 patients (25%), mildly improved in 1 patient but not sufficiently for intercourse and significantly improved with erection sufficient for intercourse in 5 patients (62.5%) (figure 2). Two of these 5 men required a PDE5i for optimal erections however both had failed PDE5i in the past.

Discussion: Low Intensity Shockwave Lithotripsy with the Urogold 100 using a once a week protocol produced a similar success rate to previously published twice weekly protocols. One of the treatment failures had psychogenic ED suggesting that inclusion criteria should focus on men with an arteriogenic etiology. Whether this once weekly therapy remains durable will await longer term follow up. Since in the United States this device is not approved by the FDA and patients will need to pay cash for therapy, a protocol that minimizes time away from work and out of pocket expense is highly desirable.

Conclusion: Once weekly low intensity shock wave lithotripsy improved erections sufficient for intercourse in 62.5% of our patients without side effects.

20th ISMST Congress in San Sebastian, Spain.

Study Performance: **urogold100**

3.2.18. Effectiveness of Shock Wave Therapy: Implementation of a Soft Wide Focus Applicator in Patients with Erectile Dysfunction (Saffon et al., 2017)

Boston Medical Group, Bogota, Columbia.

INTRODUCTION: Low-intensity extracorporeal shock wave therapy (LI-ESWT) is of great clinical interest for the treatment of erectile dysfunction (ED), chronic pelvic pain (CPP) and Peyronie's disease. Extensive research in animal and human studies showed that the beneficial effect of LI-ESWT is due to its angiogenic properties. It is thought to stimulate neovascularization by inducing the expression of regeneration- and growth-related factors, like for example eNOS, VEGF and PCNA although the precise underlying mechanisms are not entirely clear yet. Thereby LI-ESWT can increase penile blood flow and endothelial function and represents a new, sustainable therapeutic strategy to restore erectile function, independent of, or supporting the conventional palliative medication. [1][2][3] **OBJECTIVE** Progress report on LI-ESWT in the treatment of vascular ED using a SWFA (soft wide focused applicator) handpiece for a cohort of 20 patients in a clinical center in Bogota, Columbia.

METHODS: Clinical records of patients treated at the medical center were reviewed during the first half of 2016, with diagnosis of vascular ED and underwent a protocol of LI-ESWT once a week for 5 weeks, energy flux density 0.15mJ and 3000 pulses per session, with the MTS urogold100® and applicator OP155. Outcome measurements: Erection Hardness Score (EHS), International Index of Erectile Function, 5-item version (IIEF-5).

RESULTS: 20 patients with a mean age of 53.1 ± 12.1 years were included. At admission, 70% of patients had mild / moderate ($n = 14$), 20% ($n = 4$) moderate and 10% ($n = 2$) severe ED according to the IIEF-5 scale. After five sessions 25% ($n = 5$), and after one-month follow-up even 45% ($n = 9$) of patients showed a clinical important difference (defined as an increase of ≥ 4 points) in the IIEF score with an average increase of 5 points (18 ± 4.4 , $p = 0.001$). Assessing the EHS, 55.5% of patients at baseline (mean

EHS: 3 ± 0.6) had an erection insufficient to penetrate, this proportion decreased significantly to 28% after therapy (mean EHS: 4 ± 0.7 , $p = 0.05$), a beneficial effect that was still persisting after one month follow-up (mean EHS: 4 ± 0.7 , $p = 0.04$).

CONCLUSIONS: The preliminary results of LI-ESWT in the treatment of ED with the MTS urogold100® and applicator OP155 are promising and indicate a clinically significant improvement in both, the IIEF and EHS by this technology. Studies with a larger group of patients, a longer follow-up and a comparative shock wave protocol setup are necessary to further assess the statistical, clinical significance and efficacy of this improvement in erectile function upon LI-ESWT.

Study Performance: **urogold100**

3.2.19. Penile Low Intensity Shock Wave Therapy for PDE5i Non-Responders Suffering from Vasculogenic Erectile Dysfunction since 2 to 10 Years: A Prospective, Randomized, Placebo-Controlled Study (Vinay et al., 2017)

Andrology Department, Fundació Puigvert / Universidad Autònoma de Barcelona, Barcelona, Spain.

Background: Several animal and human studies have evaluated the role of low-intensity extracorporeal shockwave therapy (LIST) in the management of multiple disorders such as chronic wounds, peripheral neuropathy and cardiac ischemic disease. LIST was reported to trigger a chain of events that releases angiogenic factors, recruits endothelial progenitor cells, induces neovascularization and enhances blood flow in treated areas. Recently, some studies with contradictory results have assessed the efficacy and safety of this therapy on patients suffering erectile dysfunction.

Aim: Investigate the effects of penile LIST on erectile function in long-term patients suffering from erectile dysfunction since 2-10 years and are refractory to phosphodiesterase type 5 inhibitors (PDE5i).

Methods: Prospective, randomized, simple-blind, sham-controlled study. In total 58 patients with vasculogenic erectile dysfunction refractory to PDE5i were randomized into two groups. 30 were treated with electrohydraulic low intensity shock waves (1 session/week for 6 weeks; 1,500 pulses of 0.10 mJ/mm^2 at 5 Hz, urogold100® MTS) and 28 were treated with a sham probe. Eleven patients withdrew from the study and were lost to follow-up. All patients were evaluated at baseline and 1 month after the end of treatment using validated erectile dysfunction questionnaires like the International Index of Erectile Function (IIEF-5) and the Sexual Encounter Profile (SEP). Demographic and clinical characteristics were recorded. Data analysis investigated specifically the long-term patients suffering from ED since 2-10 years, which were in total forty-one patients; 22 in the verum group, 19 in the sham group.

Results: 22 active-treated patients and 19 sham-treated patients, suffering from ED since 2-10 years were analyzed. There was no significant difference between the two groups in baseline characteristics. Baseline five-item version of the IIEF-5 mean scores, in the active and sham groups, were 10.0 ± 4 and 9.9 ± 4.6 , respectively ($p = 0.94$). At baseline, 14% of patients in the active group (3 of 22) and 10.5% of patients in the placebo group (2 of 19) had a positive answer to the SEP 3 question ($p = 0.8$). One month after treatment IIEF-5 scores mean changes from baseline, in the active and placebo group, were 2.2 ± 4.9 and 0.25 ± 4.4 , respectively ($p = 0.2$). SEP 3 positive responders increased by 33% in the active group (7 of 22) and even decreased in the placebo group to 5% (1 of 19) ($p = 0.03$) after LIST.

Conclusion: In this prospective study, 1 month of moderate LIST treatment led to partial recovery of erectile function at one-month follow up, as the amount of positive SEP3 responders significantly Page 2 of 4 increased 4 times and the average IIEF-5 score improved 8 times in the active group compared to the sham control group which, showed no placebo-effect. More studies with larger sample size and



longer follow-up, comparing different lithotripters and shock wave protocols, are imperative to define alternative protocols and the role of LIST in erectile dysfunction for long term ED patients.

Study Performance: **urogold100**

3.3. Chronic Pelvic Pain / Chronic Prostatitis

3.3.1. Case Series of Low Intensity Shock Wave Therapy for Men with Chronic Prostatitis / Chronic Pelvic Pain Syndrome (Shoskes & Mooney, 2018)

Department of Urology, Glickman Urologic and Kidney Institute, Cleveland Clinic Foundation, Cleveland, OH, USA.

Introduction: Chronic Prostatitis/Chronic Pelvic Pain Syndrome (CP/CPPS) is a heterogeneous syndrome that is often challenging to treat. Low Intensity Shock Wave (LiSW) has emerged as a potential therapy and several sham controlled studies have shown efficacy. We wished to study the efficacy and safety of LiSW in CP/CPPS patients with clinical phenotyping to better understand who may best respond.

Methods: Men were enrolled in this IRB approved study provided they had a diagnosis of CP/CPPS for at least 6 months and were able to return for weekly treatments. Those on multi-modal therapy continued other therapies as long as the dose was stable. LiSW was delivered with the Urogold 100 machine (Tissue Regeneration Technologies, Woodstock, GA) using the standard probe. There were 4 treatment sites, 2 on each side of the perineum at 500 shocks each for a total of 2000 shocks. Symptom severity was measured with the National Institute of Health Chronic Prostatitis Symptom Index (CPSI) at baseline and 1 month following the last treatment. Patients also self-reported a General Response Assessment (GRA) ranging from 1 (significantly improved) to 5 (significantly worse). Patients were clinically phenotyped by the UPOINT system. Pre and post values were compared with the paired t test with significance set at $p < 0.05$.

Results: 14 men enrolled with a mean age of 45.1 years (range 22-67) and median duration of 36 months (range 9-240). Men had a mean of 2.6 positive UPOINT domains (range 1-5) and all but 2 had pelvic floor tenderness (domain &[Prime]T&[Prime]). Total CPSI improved from 27.7 +/- 5.4 to 19.4 +/- 7.5 ($p = 0.003$). While the pain and quality of life scores improved significantly, there was no change in the urinary subscore. 9 patients (64.3%) had a >6-point drop in CPSI. By GRA, 7 patients said they were significantly improved, 2 was somewhat improved and 5 were unchanged. There were no significant differences in responders to non-responders for phenotype or symptom duration although responders had a higher starting pain score (14.0 vs 9.4, $p = 0.005$) and both patients without pelvic floor spasm failed to improve.

Conclusions: LiSW with the Urogold 100 improved symptoms of CP/CPPS in the majority of patients. All responders had pelvic floor spasm, and shock wave therapy is well established in the treatment of pain from trigger points. While small numbers preclude meaningful subgroup analysis, there was no impact on urinary symptoms. In conclusion, once weekly low intensity shock wave lithotripsy improved the symptoms of CP/CPPS in the majority of patients without side effects.

Study Performance: **urogold100**

3.3.2. Efficacy of Extracorporeal Shockwave Therapy (ESWT) for Male Chronic Pelvic Pain Syndrome: a Phase III, Randomized, Double Blind Controlled with Placebo Study (Ramon et al., 2017)

Hospital Quiron Barcelona, Spain.

Introduction: Chronic Prostatitis/ Chronic Pelvic Pain Syndrome (CP/CPPS) according to NIH is genitourinary pain or discomfort lasting 3 or more months with undetectable uropathogenic bacteria.

Material & Methods: Randomized, double blind, placebo-controlled study has been conducted in 40 male patients who have had CPPS. Patients were randomly assigned to receive extracorporeal shock wave therapy (ESWT) or placebo. The study was conducted together by both Urology and Rehabilitation services. The primary outcome was to assess the efficacy of extracorporeal shock wave therapy for treatment of males CPPS.

Results: 38 patients were evaluated. ESWT group improved their pain relief statistically significantly compared to placebo group (11 +/- 3.15 vs 6.31 +/- 2.55, $p < 0.05$). Also improved voiding quality as measured by IPSS score (11 +/- 2 vs 7.21 +/- 1.5, $p < 0.05$). These results were maintained until 12 weeks. No AEs.

Discussion: At 4 and 12 weeks, patients who received ESWT experienced improvement in pain relief, quality of life, and voiding symptoms. In the literature the patients experienced the maximum relief of their symptomatology after 4 weeks of treatment, according to our results patients have achieved an improvement even better at 12 weeks. The results obtained are similar to those reported in the bibliography. Several studies in orthopedics, urology and cardiology have shown very low rate of AEs derived from ESWT.

Conclusion: It has been demonstrated ESWT is an effective and safe treatment for CPPS. Due to high prevalence of CPPS and none specific treatment, ESWT should be considered an effective and safe treatment alternative.

20th ISMST Congress in San Sebastian, Spain.

Study Performance: **urogold100**

3.4. Premature Ejaculation

3.4.1. Novel Use of a Shock Wave Device for Energy Flux Density Threshold Testing of the Distal Ventral Erect Penile Shaft as a Marker of Penile Dysesthesia/Hypersensitivity Associated with Premature Ejaculation (Uloko et al., 2020)

San Diego Sexual Medicine, San Diego, CA.

Introduction: Premature ejaculation (PE) is the most common sexual dysfunction in men. Traditional PE management is based on pharmacologic strategies to increase/decrease central inhibition/excitation, respectively. A subset of PE patients was identified with extreme penile hypersensitivity; simply touching the frenular region during sexual activity resulted inevitably in premature ejaculation. The clinical dilemma is that there are no objective and clinically relevant clinical tests of penile dysesthesia/hypersensitivity to successfully identify this subset of PE patients

Objectives: We herein describe, in a subset of men with PE, a novel biologic marker for penile dysesthesia/hypersensitivity.

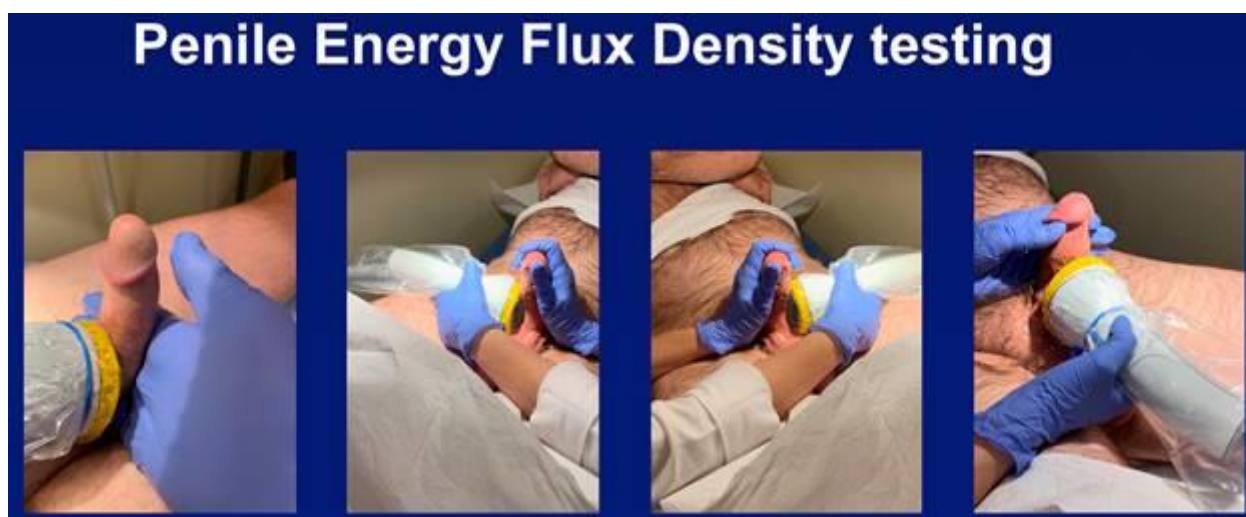Methods: Energy flux density is a measure of the energy per square area (mJ/mm²) released by a shockwave pulse at a specific location. The threshold of energy flux density tolerable to the patient was determined during pharmacologic penile erection. The UroGold 100 MTS OP155 parabolic probe, Hz 3 was applied to the right and left lateral mid-shaft, the dorsal mid-shaft, the proximal ventral shaft and the distal ventral shaft overlying the frenulum. At each location, the patient was asked if there was pain on a 4-point scale (0 none, 1 mild, 2 moderate, 3 severe). We started with energy flux density



values of 0.05 mJ/mm² and increased to a maximum of 0.14 mJ/mm², if tolerable. Energy flux density threshold was defined as the energy flux density when the patient experienced a 2-3 pain level. In those who demonstrated peri-frenular penile dysesthesia/hypersensitivity, the extent of the dysesthesia was mapped, the region was numbed (penile anesthesia test) and the patient was asked to masturbate in a private setting, usually in the office, to determine ejaculation latency.

Results: 51 men without PE (mean age 48 +/- 15, IELT > 5 min) and 14 men with PE (IELT < 1 min) (mean age 25 +/- 7) were studied during pharmacologic penile erection. In men without PE, the energy flux density threshold in all erect penile locations was 0.12 - 0.14 mJ/mm². In the 14 men with PE, the energy flux density threshold in the distal erect ventral shaft region was significantly lower at 0.05 - 0.07 mJ/mm², while all other erect penile locations yielded threshold values similar to men without PE (0.12 - 0.14 mJ/mm²). 9 patients underwent penile anesthesia testing and IELT values during masturbation increased to over 10 minutes. Figure 1 depicts the novel use of erect penile shockwave energy flux density testing as a diagnostic marker in this subset of men with PE.

Conclusion: Energy flux density threshold may be the first objective, sensitive, clinically relevant biologic marker to identify men whose PE is a result of a localized penile dysesthesia/hypersensitivity in the peri-frenular region. Identification of this subset of PE patients could lead to alternative strategies to cure their PE.



21st Annual Fall Scientific Meeting of Sexual Medicine Society of North America (SMSNA), Abstract No.041

Study Performance: **urogold100**

3.5. Penile Augmentation

3.5.1. *The Concept of Spark Wave Therapy (Sw) Assisted Penile Augmentation* (Mirza, 2017)

Kharkiv National Medical University (KNMU), Kharkiv, Ukraine.

Introduction and rationale: Spark Wave Therapy (SWT) works on the basis of Angiogenesis and tissue regeneration. The therapeutic approach involves usage of penile traction devices, hydropump in combination with SWT to induce penile tissue hyperplasia in a controlled manner which can be considered as an alternative to Augmentation Phalloplasty (Penis enlargement) surgery.

Action: Usage of penile traction device and penile hydropump causes the penile tissue to be stretched and expanded. As a result, microtears appear in the penile tissue. Due to the body's own repair

mechanism, these microtears heal by the mean of cell proliferation which results in penile tissue hyperplasia. The acceleration and completion of the repair process depends on several factors. Two of the most important factors are angiogenesis which ensures the proper environment for cell proliferation by means of improving hemodynamics and migration, proliferation and differentiation of stem cells. These biological processes could be assisted by SWT which will speed up and complete the recovery process successfully.

Outcome: As a result of the combination of Angiogenesis (inducing vascularization and improving hemodynamics) and cell proliferation (pre-existing cells and stem cells), penile tissue hyperplasia occurs which results in increased penile length and girth (circumference) permanently without any damage to erectile function.

Discussion and recommendations: Augmentation Phalloplasty carries such risks as post-operative penile shortening, penile deformation, asymmetric penile dimensions etc. On the other hand, SWT assisted penile augmentation does not carry any of those risks.

3.6. Testicular Function

3.6.1. Pilot Trial, First Report Worldwide for Unfocused SoftWave Therapy (uESWT) for the Treatment of Testicles to Improve Testicular Size and Function (Sharpe et al., 2019)

Georgia Urology, Atlanta, USA.

Introduction: Testosterone in males is produced in the testicles. With aging testosterone levels are reduced, and this is associated with the loss of libido and erectile dysfunction (ED). In the U.S. ED is common affecting at least 12 million men¹. Usual practice to treat ED in the U.S., involve Shock Wave Therapy (SWT) using radial and ballistic devices. However, the Mayo clinic (Rochester, MN) during the 2018 ISSM Congress in Lisbon, reported only an average success rate of about 50 %. In order to improve ED problems of aging men, we used a novel approach of ESWT which uses unfocused SoftWaves. Based on previous studies we predict these uESWT could improve testicular health and function.

Results: Post treatment average testosterone levels improved 45 %. No patients reported pain during or after treatment. No analgesic was required during therapy. All of the patients continue to use the therapy and report continued satisfaction and improved libido.

Discussion: The testicles appear to be producing natural testosterone and returning to near normal size, improving functionality. However, additional studies are needed.

Conclusion: Based on the results of this pilot trial, TRT is sponsoring an IRB study to expand the number of patients and the scope of the study. IRB partners are being recruited at this time. It seems as if the added treatment of the testicles during ED therapy may support improved outcomes and patient satisfaction.

22th ISMST Congress in Beijing, China.

Study Performance: **urogold100**

3.7. Vestibulodynia

3.7.1. Chart Review of Low-Intensity Shockwave Therapy with Urogold100™ MTS for Hormonally-Mediated Vestibulodynia (Goldstein et al., 2024)

San Diego Sexual Medicine, San Diego, California, United States of America.



Objectives

Low intensity shockwave therapy (LiSWT) is a non-pharmacologic, non-surgical treatment strategy FDA-cleared for pain amelioration. This chart review examines treatment outcome with the Urogold 100™MTS for hormonally-mediated vestibulodynia (HMV).

Methods

Patients diagnosed with HMV were offered LiSWT. Standard in our practice, patients completed Female Sexual Function Index (FSFI), Sexual Distress Scale (SDS), vulvoscopy with photography, and cotton-tipped swab testing at baseline. Pre-treatment hormonal blood tests included total testosterone and sex hormone binding globulin. Vulvoscopic vulvar/vestibular photographs were scored for Vulvar/Vestibular Tissue Appearance (Vul/VestTA) (0 = normal, 1 = minimal, 2 = moderate, 3 = severe) for the vulva, vestibule and urethral meatus. Cotton-tipped swab testing rated pain at the 1:00, 3:00, 5:00, 6:00, 7:00, 9:00 and 11:00 positions (0 = no pain, 1 = minimal, 2 = moderate, 3 = severe). The LiSWT protocol involved 6 treatment sessions, 2100 shocks each (700 right/left lateral vestibule, 700 posterior vestibule), frequency 3/sec, membrane level 1, with energy varied from 0.07 – 0.13 mJ/mm², based on patient tolerance. Patients underwent vulvar-vestibular photography and cotton-tipped swab testing prior to each set of LiSWT. Before the second and subsequent treatments, patients completed the Patient Global Impression of Improvement (PGI-I).

Results

19 patients with HMV, mean age 35 years, had low calculated free testosterone and elevated sex hormone binding globulin. Mean baseline scores were: FSFI 15.2/36; Sexual Distress Scale 31/52; cotton-tipped swab testing 2.4; and Vul/VestTA 2.6. Post-treatment, 11/19 (58%) of patients reported a PGI-I of 1-3, indicative of clinically relevant improvement. Post-treatment cotton-tipped swab testing score was diminished to 1.9 (consistent with mild pain), Vul/VestTA was 1.7 and vulvar/vestibular photographs revealed reduced vestibular pallor and erythema. One patient experienced transient worsening of symptoms.

Conclusions

This chart review supports the need for prospective, sham-controlled clinical trials of LiSWT with Urogold 100™MTS for HMV.

Conflicts of Interest

No conflicts of interest.

ESSM congress 2024, Bari, Italy. Poster presentation, P-01-07 #182.

Study Performance: **OW100 urogold100**

3.7.2. A Pilot Study of Post-Vestibulectomy Opioid Use following Pre-Operative Vestibular Low Intensity Shockwave Therapy (Goldstein et al., 2024)

San Diego Sexual Medicine, San Diego, California, United States of America.

Objectives

Low intensity shockwave therapy (LiWST) is FDA-cleared for pain amelioration. We serendipitously observed that one patient trying to avoid vestibulectomy surgery for neuroproliferative vestibulodynia (NPV) by undergoing multiple vestibular LiWST treatments used very few narcotics post-vestibulectomy. As a result, we studied whether using pre-operative LiSWT would decrease post-operative opioid use in patients undergoing complete vestibulectomy for NPV.

Methods

Post-op opioid use among women who underwent complete vestibulectomy at our facility January 1, 2019 to June 30, 2021 was assessed based on patient's recall of total oxycodone/acetaminophen tablets required within 30 days post-vestibulectomy. When possible, patients confirmed use by counting tablets remaining in the pill container. Women scheduled for vestibulectomy were included in the LiSWT study group if they agreed to undergo 3 vestibular LiSWT treatments immediately pre-

operatively. Using the Urogold 100™MTS, LiSWT involved delivery of 1800 shocks to the vestibule per session, energy flux density 0.05-0.1 mJ/mm², 3 Hz, membrane pressure 3. We compared post-op opioid use by women who did and did not undergo pre-operative LiSWT.

Results

Forty-five women (mean age 28 years) underwent complete vestibulectomy during the 30-month period. Twenty women (mean age 27 years) underwent pre-op LiSWT and 25 (mean age 29 years) did not. Post-op opioid use was obtained from all but 6 in the non-LiSWT group. Mean post-op opioid use was 22 +/- 10 (range 1 - 26) tablets in patients who underwent vestibular LiSWT treatments; opioid side effects were restricted to constipation, sleepiness, and nausea. Mean post-operative opioid use was 47 +/- 13 (range 25 - 90) tablets in those without vestibular LiSWT; opioid side effects included constipation, nausea, fainting, drowsiness, fatigue, and blurred vision.

Conclusions

In this pilot study, pre-operative low intensity shockwave therapy decreased post-operative opioid use after complete vestibulectomy with vaginal advancement flap. While encouraging, more research is needed.

Conflicts of Interest

No conflicts of interest.

ESSM congress 2024, Bari, Italy. Poster presentation, P-01-07 #183.

Study Performance: **OW100 urogold100**

3.7.3. Decrease in Opioid Use Post-Vestibulectomy Based on Pre-Operative Low Intensity Vestibular Shockwave Therapy (LiSWT) (Goldstein et al., 2021)

Alvarado Hospital, United States of America.

Introduction

Surgeons performing complete vestibulectomy for neuro-proliferative vestibulodynia (NPV) need to consider acute pain relief in the early postoperative period and risks for persistent opioid use. One patient who failed multiple vestibular LiSWT sessions to manage her pain eventually underwent vestibulectomy. We observed that post-operatively there was minimum hydrocodone use. Since a study showed that pre-operative LiSWT improved wound healing and surgical outcome, it was hypothesized that LiSWT promoted enhanced blood supply and angiogenesis through expression of vascular endothelial growth factor and nitric oxide synthesis, and via anti-inflammatory action downregulating necrosis factor B activation thereby lowering inflammatory cytokines. In women undergoing vestibulectomy for NPV, we wished to see if pre-operative LiSWT would reduce post-operative opioid use. We compared opioid use post-op vestibulectomy in patients who had and had not undergone LiSWT just prior to surgery.

Material & Method

This is a pilot study of patients' post-operative vestibulectomy experiences with opioid use for post-operative pain management. Patients scheduled for surgery were required to present to the hospital 4 days before surgery for a COVID-19 test. They underwent vestibular LiSWT at our clinic on that day and each subsequent day until surgery; 2400 shocks, energy flux density 0.09-0.11 mJ/mm², 3 Hz, membrane pressure 3 using the Urogold 100™MTS, FDA-cleared for pain amelioration, providing unfocused electrohydraulic shockwaves with a unique parabolic reflector (OP-155).

Results

Patients are routinely prescribed # 60 oxycodone 5 mg/acetaminophen 325 mg tablets to be taken every 4 hours as needed. Mean post-op opioid use was 38 +/- 15 tablets in 10 vestibulectomy patients (mean age 29 +/- 10 years) who did not undergo pre-op vestibular LiSWT; opioid side effects included



constipation, nausea, fainting, blurred vision. Mean post-op opioid use was 14 +/- 6 tablets in 9 vestibulectomy patients (mean age 27 +/- 9 years) who did undergo pre-op vestibular LISWT sessions x 3; opioid side effects were restricted to constipation and nausea.

Discussion

In this pilot study, pre-op LiSWT using Urogold 100™ MTS decreased post-op opioid use after complete vestibulectomy with vaginal advancement flap. While encouraging, more research is needed.

23rd World Congress of the ISMST 2021 in Vienna, Austria, 6. ESWT in Urology and Sexual Medicine.

Study Performance: **urogold100** applicator OP155

3.7.4. Retrospective Chart Review of Treatment Outcome Following Low-Intensity Shockwave Therapy for the Treatment of Vestibulodynia with Urogold100 (Yih, 2020)

San Diego Sexual Medicine, San Diego, CA.

Introduction: Genital pain disorders have devastating effects on a woman's quality of life, including social isolation. These disorders occur with high prevalence; more than 1/3 of women report pain during sexual activity, placing a significant financial burden on women and the healthcare system. Multiple medical treatments for dyspareunia are available to improve quality of life and decrease pain, however many are invasive, involving pharmacotherapy/hormone therapy/needle insertion/surgery, and are associated with significant morbidity. Low intensity shockwave therapy (LiSWT) is a non-invasive, non-pharmacologic, non-hormonal, non-surgical, low morbidity treatment strategy. FDA-cleared for pain amelioration in the US as non-significant risk in humans, Urogold 100™ is an electrohydraulic shockwave device that generates energy levels such as 0.10-0.12 mJ/mm² with a unique parabolic reflector.

Objective: This chart review represents the first US-based treatment outcome study in women with vestibulodynia using Urogold 100™.

Methods: Patients presenting with vestibulodynia were offered the opportunity to receive LiSWT as a potential treatment for their genital pain disorder. As standard of care in our practice, patients completed the Female Sexual Function Index (FSFI), Sexual Distress Scale (SDS), vulvoscopy with photography, and cotton-tipped swab (Q-tip®) test at baseline. Vulvoscopic vulvar/vestibular photographs were scored for Vulvar/Vestibular Tissue Appearance (Vul/VestTA) (0 = normal appearance, 1 = minimal, 2 = moderate, 3 = severe concerns) for the vulva, vestibule and urethral meatus, with low scores associated with healthier tissue appearance. Cotton-tipped swab testing rated pain at the 1:00, 3:00, 5:00, 6:00, 7:00, 9:00 and 11:00 positions (0 = no pain, 1 = minimal, 2 = moderate, 3 = severe). The LiSWT protocol involved 6 treatment sessions, 3000 shocks each (1000 right/left lateral vestibule, and 1000 posterior vestibule), frequency 4/sec, membrane level 1. The energy varied from 0.10 – 0.12 mJ/mm², based on patient toleration. Patients underwent vulvoscopy with photography and cotton-tipped swab testing prior to each LiSWT, as is routine in our practice. At the end of treatment, patients recorded their treatment response by Patient Global Impression of Improvement (PGI-I), a scale of 1 – 7 with clinically relevant improvement expressed by scores of 1 – 3.

Results: To date data have been collected on 14 vestibulodynia patients, mean age 37 years (range 21 – 74). Mean baseline FSFI domain scores for desire, arousal, lubrication, orgasm, satisfaction and pain were: 2.6/6, 3.1/6, 3.4/6, 2.2/6, 2.6/6, and 1.6/6, respectively. Mean baseline Sexual Distress Scale score was 35.7/52, cotton-tipped swab test score was 2.6, and Vul/VestTA score was 2.5. Posttreatment, 9/14 (64%) of patients reported a PGI-I of 1 - 3. Post-treatment cotton-tipped swab testing score was diminished to 1.4 (consistent with mild pain). Post-treatment Vul/VestTA was 1.3

and vulvar/vestibular photographs revealed reduced vestibular pallor and erythema. No treatment-related side effects were reported. No patient experienced worsening of symptoms.

Conclusions: Vestibulodynia is a significant sexual health concern in women. Efforts to improve noninvasive, non-pharmacologic, non-hormonal, non-surgical, low morbidity treatment strategies should be encouraged. This chart review of LiSWT using UroGold 100™ is supporting the development of a prospective, sham-controlled clinical trial of LiSWT in women with vestibulodynia.

Study Performance: **uroGold100**

3.8. Persistent Genital Arousal Disorder / Genito-Pelvic Dysesthesia

3.8.1. *Extracorporeal Shockwave Therapy for the Management of Persistent Genital Arousal Disorder/Genito-Pelvic Dysesthesia from Lumbosacral Spine Pathology-Induced Sacral Radiculopathy (Goldstein et al., 2022)*

San Diego Sexual Medicine, Sexual Medicine, San Diego, USA.

Introduction

Persistent genital arousal disorder (PGAD), a form of genito-pelvic dysesthesia (GPD), is a sexual medicine condition highly associated with despair, emotional lability, catastrophization and suicidality. PGAD/GPD may be triggered by an inflammatory radiculopathy of sacral spinal nerve roots in the cauda equina from lumbar annular tear(s) or sacral Tarlov cyst(s). Approximately 1 % of the population have PGAD/GPD. These patients may suffer from unwanted, unrelenting, unprovoked, arousal and/or dysesthesia symptoms with limited treatment options.

Material & Method (please include the kind of device you are using)

This is a retrospective chart review of patients who underwent lumbo-sacral extracorporeal shockwave therapy (ESWT) who had: 1) distressing PGAD/GPD symptoms; 2) abnormal neurogenital testing; 3) abnormal lumbo-sacral MRI's exhibiting sacral Tarlov cyst or lumbar annular tear; and 4) a consultation with a minimally invasive spine surgeon. ESWT was applied to the right and left lateral sacral (Tarlov cyst) and/or lumbar area (annular tear) identifying regions of moderate-severe discomfort using the UroGold 100 MTS OP155 unfocused parabolic probe, Hz 3, membrane level 1. The probe was maintained over that region until discomfort diminished to zero. Initial energy flux density was 0.06 mJ/mm², increasing energy by 0.01 mJ/mm² until a new region of moderate-severe discomfort was identified and discomfort returned to zero, with a maximum energy flux density of 0.11 mJ/mm². From 2 to 6 treatment sessions were performed with 2800–4900 shocks each session, based on individual tolerance. Patients self-rated their PGAD/GPD intensity prior to treatment and multiple times during treatment. Beginning with the second treatment, patients completed the Patient Global Impression of Improvement (PGI-I) after signing consent. Clinically relevant improvement was expressed by scores of 1–3 on the scale of 1–7.

Results

21 people (mean age 39 ± 13 years) were identified: 10 had undergone lumbar and/or sacral spine surgery with only partial resolution of symptoms; 8 were not considered candidates for spine surgery; 3 chose not to undergo spine surgery. All exhibited various bothersome symptoms of PGAD/GPD during lumbo-sacral ESWT with marked reduction in symptoms during the actual shockwave treatment in 13/21 (62 %). These patients also exhibited longer-term marked reduction in symptoms with reports of 1–3 on the PGI-I with follow-up of 2–4 months. Adverse events were limited to short-term back pain that fully resolved by 1 week.



Discussion

Initial results are promising for this non-invasive, non-hormonal, non-pharmacologic shockwave energy-based strategy for a highly selected population of patients with distressing PGAD/GPD secondary to Tarlov cyst and/ or lumbar annular tear induced sacral radiculopathy.

24th World Congress of the ISMST 2022 in Prague, Czech Republic, oral presentation ISMST22-0076.

Study Performance: **urogold100** applicator OP155.

3.8.2.Lumbo-Sacral Low Intensity Shock Wave Therapy for Persistent Genital Arousal Disorder/Genito-Pelvic Dysesthesia Using the UroGold 100 MTS (Yih et al., 2020)

San Diego Sexual Medicine, San Diego, CA.

Introduction: Low intensity shockwave therapy (LiSWT) was introduced to sexual medicine in 2010 as penile shockwave therapy for the non-invasive, non-hormonal, non-pharmacologic treatment of erectile dysfunction. Ever since, sexual medicine clinicians have been broadening LiSWT utilization for bothersome sexual health concerns. LiSWT has been shown to be anti-inflammatory to such processes as radiculitis and researching Pubmed for LiWST treatments of various pain conditions yields over 600 citations. Persistent genital arousal disorder (PGAD) a form of genito-pelvic dysesthesia (GPD), is a sexual medicine condition highly associated with despair, emotional lability, catastrophization and suicidality.

Objective: The objective of this chart review was to examine outcomes of a specific population of women with distressing PGAD/GPD suspected to be from radiculopathy of the sacral spinal nerve roots who underwent lumbo-sacral LiSWT.

Methods: Patients with PGAD/GPD suspected to be from radiculopathy of the sacral spinal nerve roots have the following: i) abnormal neuro-genital testing, ii) abnormal lumbo-sacral MRI with degenerative disc disease, herniated nucleus pulposus, annular tear, facet cyst, and/or Tarlov cyst; and iv) consultation with a spine surgeon. Patients were selected for lumbo-sacral LiSWT who had distressing symptoms of PGAD/GPD with unrelenting, unprovoked feelings of arousal, pain or other dysesthesia > 3 mo, who had either had minimally invasive spine surgery (MISS) without full resolution of symptoms; had not been considered a candidate for MISS, or had chosen not to have lumbosacral surgery. Treatment involved using the UroGold 100 MTS, OP155 parabolic probe, Hz 3, energy density 0.06 - 0.10 mJ/mm² for 2-4 treatments, with 2100 - 4200 shocks to the left and right sacral and/or lumbar regions depending on the suspected site of pathology based on the MRI. The Patient Global Impression of Improvement (PGI-I) was administered at the second treatment visit and thereafter.

Results: Thirteen women (mean age 38 +/- 11 years) with various symptoms of PGAD/GPD were identified. 7 had MISS with improvement but not full resolution of their distressing symptoms and 6 did not have spine surgery. After treatments, 8/13 (62%) realized improvement of distressing symptoms selecting very much better, much better or somewhat better on the PGI-I. Four of the patients-maintained improvement, reporting minimum PGAD/GPD distressing symptoms at 4-6 months following the last LiSWT. The adverse event of temporary worsening of back pain was observed in 5 patients, noted for 1- 14 days post-treatment, that fully resolved in all patients.

Conclusion: While more research is needed, initial results are promising for this non-invasive, non-hormonal, non-pharmacologic shockwave energy-based strategy for a highly selected population of women with distressing PGAD/GPD secondary to suspected radiculopathy of sacral spinal nerve roots.

21st Annual Fall Scientific Meeting of Sexual Medicine Society of North America (SMSNA), Abstract No.134.



Study Performance: **urogold100**

3.9. Lithotripsy - Kidney and Ureter Stone Disease

3.9.1. Lithotripter Outcomes in a Community Practice Setting: Comparison of an Electromagnetic and an Electrohydraulic Lithotripter (Bhojani et al., 2015)

Indiana University School of Medicine, Indianapolis, Indiana.

Purpose: We assessed patient outcomes using 2 widely different contemporary lithotripters.

Materials and methods: We performed a consecutive case series study of 355 patients in a large private practice group using a Modulith® SLX electromagnetic lithotripter in 200 patients and a LithoGold LG-380 electrohydraulic lithotripter (TRT, Woodstock, Georgia) in 155. Patients were followed at approximately 2 weeks. All preoperative and postoperative films were reviewed blindly by a dedicated genitourinary radiologist. The stone-free rate was defined as no residual fragments remaining after a single session of shock wave lithotripsy without an ancillary procedure.

Results: Patients with multiple stones were excluded from analysis, leaving 76 and 142 treated with electrohydraulic and electromagnetic lithotripsy, respectively. The stone-free rate was similar for the electrohydraulic and electromagnetic lithotripters (29 of 76 patients or 38.2% and 69 of 142 or 48.6%, $p = 0.15$) with no difference in the stone-free outcome for renal stones (20 of 45 or 44.4% and 33 of 66 or 50%, $p = 0.70$) or ureteral stones (9 of 31 or 29% and 36 of 76 or 47.4%, respectively, $p = 0.08$). The percent of stones that did not break was similar for the electrohydraulic and electromagnetic devices (10 of 76 patients or 13.2% and 23 of 142 or 16.2%) and ureteroscopy was the most common ancillary procedure (18 of 22 or 81.8% and 30 of 40 or 75%, respectively). The overall mean number of procedures performed in patients in the 2 groups was similar (1.7 and 1.5, respectively).

Conclusions: We present lithotripsy outcomes in the setting of a suburban urology practice. Stone-free rates were modest using shock wave lithotripsy alone but access to ureteroscopy provided satisfactory outcomes overall. Although the acoustic characteristics of the electrohydraulic and electromagnetic lithotripters differ substantially, outcomes with these 2 machines were similar.

Study Performance: **lithogold380**

4. Neurology

4.1. Spinal Cord Injury

4.1.1. Shock Wave Treatment Reduces Neuronal Degeneration Upon Spinal Cord Ischemia and Improves Symptoms in a First-in-Man Trial (Holfeld J., ... Tepeköylü C. et al., 2017)

Department of Cardiac Surgery, Medical university of Innsbruck, Austria.

Introduction: In pre-clinical and clinical studies SWT had a favorable effect on ischemic myocardium. We therefore hypothesized that SWT may have a beneficial effect on spinal cord ischemia.

Material and Method: Mice underwent aortic cross clamp surgery and received 500 shock waves at 0.1 mJ/mm^2 (5Hz). Functional performance of animals was evaluated. Neuronal degeneration, angiogenesis and inflammatory response was analyzed. Three patients with spinal cord ischemia were treated with SWT. Motor function was assessed using the standardized ASIA scale, spinal cord independence measure, MRI and sensory evoked potentials.



Results: SWT resulted in decreased neuronal degeneration, improved motor function and enhanced survival. SWT induced angiogenesis and modulation of inflammatory in treated spinal cords. Effects were missing in TLR3-/- animals. The beneficial effect could be confirmed in human spinal slice cultures. Treated patients showed no side effects and exhibited significant improvement of motor function and sensory function after SWT.

Discussion: Shock wave treatment induces angiogenesis and modulates inflammation in spinal cord ischemia via the activation of TLR3 resulting in decreased neuronal degeneration. SWT is safe for patients with SCI and improves symptoms.

Conclusion: We present for the first time a feasible treatment option for paraplegia upon ischemic spinal cord injury.

20th International Congress of the ISMST 2017 in San Sebastian, Spain, Abstract P30.

Study Performance: **orthogold180C** with applicator CP050

4.1.2. Unfocused SoftWave Therapy for the Treatment of Spine Injury Patients to Evaluate the Technology's Influence on Patient Strength, mobility, Sensitivity, Perspiration, Lung Function, Spasticity, Wound Healing and the Appearance of Scars (Weaver et al., 2015)

Georgia Spectrum Neurological, Roswell; Lavin Consulting, LLC, Framingham; TRT, Woodstock; USA; University of Innsbruck Hospital; Austria.

Introduction:

Published research has identified the influence of shockwaves on stem cell attractants, stem cell differentiation, nitric oxide, growth factors, nerve regeneration, apoptosis and the Toll Like Receptors 3 which can impact the immune and inflammatory systems.

Methods:

Ten patients with spinal cord injuries (6 complete injury, 4 incomplete) representing multiple injury types and lesions, with 14-112 months range of time since injury. All patients were attending Project Walk Atlanta rehabilitation center and actively engaged in physical therapy. These ten patients were selected to undergo multiple SoftWave treatments. Each patient was evaluated prior to enrollment with the proprietary Project Walk Developmental Activity Score (DAS, 1 --- 40) by the patient's long time Physical Therapist. A control group of 5 patients not undergoing SoftWave therapy was also selected and evaluated. All patients continued to receive the standard of care, primarily physical rehabilitation at Project Walk Atlanta. The patients were treated an average of 11 times over an average of 14 weeks with SoftWave. Each also received an average of 26 hours of physical therapy during this same time frame. After The final treatment, another DAS Evaluation was performed by the physical therapist, with the patient and physical therapist filling out an extensive post treatment self-assessment questionnaire.

Results:

All patients experienced clinically significant improvements in at least one measure. Patients showed improvement with both a self-assessment questionnaire and an independent, proprietary DAS evaluation. Statistical significance was achieved for both measures. Two patients with diminished lung capacity had substantial improvement, one returning to Normal 7 Years post injury. All patients who could not perspire below the injury showed improvement. In four Patients with long term chronic wounds, all wounds totally recovered. One horribly spastic patient had his baclofen pump removed after the study. There was also a positive correlation between outcome and the number of weeks enrolled, number of shock waves, and the number of treatments. Most importantly, on the self-assessment questionnaire, patients were asked on a scale of 1 to 10, 1 being your level of ability the

day before the first SoftWave treatment, and 10 representing a return to normal, the average response was a 43% improvement. Patients believed that they were 40% down the road to total recovery. The Independent Project Walk DAS assessment showed an average improvement of 65% relative to baseline. No adverse events were noted other than one minor bruise on the foot.

Discussion:

Despite the limited number of patients, and the varied treatment protocols (location/durations), we are impressed by multi-dimensional benefits in a controlled setting. The Degree of improvement was far beyond chance. The effects on the autonomic nervous system seemed to be the most emergent (perspiration/respiration). The chronic wound healing was probably the most appreciated and obvious. The appearance of scars was diminished in all patients. Most of the patients are still participating and receiving treatment although less frequently. We continue longer term follow up.

Conclusion:

Further study is warranted with an emphasis on treating patients as soon as possible after an injury.

18th ISMST Congress in Mendoza, Argentina. Abstract No. 8.

Study Performance: **DermaGold100**

4.2. Limb Loss / Phantom Pain / Sensory Reinnervation

4.2.1. Targeted Sensory Reinnervation (TSR) and Our Experience with Shock Wave Therapy for the Treatment of Microsurgical Nerve Sutures (Gardetto et al., 2022)

Brixiana Private Clinic, Department for Plastic- Aesthetic and Reconstructive Surgery with Hand Surgery, Bressanone, Italy.

AUVA-Rehabilitation Center Tobelbad, Department for Exoprostheses, Tobelbad, Austria.

Ludwig-Boltzmann-Institute for Traumatology, The Research Center in Cooperation with AUVA, Vienna, Austria.

Introduction

The loss of the hand leads the patient to a significant reduction in personal and working quality of life and often inevitably to psychological consequences. Currently with myoelectric prostheses many of the normal activities of the hand can be recovered, with the exception of tactile sensitivity. Based on our successful experience with TSR (Targeted Sensory Reinnervation) operations performed at lower limb level, we decided to develop the same technique also at upper limb level.

Material & Method

The indications for this intervention are the treatment or prevention of neuropathic and phantom limb pain resistant to conservative therapies. Between October 2020 and February 2021, we performed the TSR technic on 3 patients.

Two patients underwent elective hand amputation and TSR surgery at the same time. In one patient, TSR was performed secondarily after a frustrated replantation attempt. The technique involves neurorrhaphy of the median and ulnar nerves with the lateral and medial antebrachial cutaneous nerve respectively in order to reinnervate the skin of the amputation stump. In one patient, immediately after surgery, the coaptation sites were treated with ESWT to proof if the reinnervation time could be shortened. Postoperatively, EEG and nerve conduction tests were performed. All patients underwent a strict rehabilitation program.

Results

The pre-operative pain (especially neuropathic pain) improved significantly to completely postoperatively or did not occur at all. No phantom limb pain occurred in the electively amputated patients and in the patients, who underwent secondary surgery, the pain has clearly subsided. A skin



sensory map of the five fingers at the level of the amputation stump and the distinction between hot and cold were detected in all three. The reinnervation data were also tested with an EEG study.

Discussion

By redirecting the median and ulnar nerves to the medial and lateral cutaneous antebrachial nerves, the originally hand is reactivated as the transmitter of the pressure sensation from the prosthetic glove. As a result, the patients equipped with a special feed stream system, feel the hand authentically and the phantom limb pain is clearly to completely interrupted or, in the case of elective amputations, not caused at all. With intraoperative shock wave therapy, the sprouting of the nerve fibers could be accelerated significantly. However, we were also able to observe an increased formation of neuroma, which don't occur in the other patients without shock wave therapy. This fact opens up a wide field of discussion for us.

24th World Congress of the ISMST 2022 in Prague, Czech Republic, oral presentation ISMST22-0079.

Study Performance: **orthogold100**

4.3. Fibromyalgia

4.3.1. Radial Extracorporeal Shockwave Treatment: A New Paradigm on Fibromyalgia (Ramon et al., 2015)

Hospital Quiron, Barcelona; Spain. Garcia Cugat Foundation, CEU – UCH Chair of Medicine.

Introduction: The purpose of this study is to evaluate the chronic effects of radial extracorporeal shockwave treatment (rESWT) in fibromyalgia (FM).

Methods: 24 women suffering from FM were included in a randomized study and asked to select the 3 most painful myofascial and asymmetrical points in the body. All patients were female, mean age 52.13 years, and received rESWT (Physiogold50, MTS): 5 weekly sessions, using 2000 shocks of rESWT at each of the 3 points: group 1 (treatment) N 0 13 treated with 500 shocks, 1,5 bar, 5 Hz; then 1000 shocks, 2 bar, 8 Hz; and 500 shocks, 1,5 bar, 15 Hz; group 2 (placebo) N = 11 (using a soft rubber cap leaving air between transmitter and the cap) received 500 shocks, 15 Hz; then 1000 shocks, 8 Hz; and 500 shocks, 15 Hz, with the pressure constant 1,5 bar.

Outcome variables were: 1) Pain: VAS, algometer (Wagner instruments) at 3 points and contralateral; McGill Questionnaire; 2) Emotional situation (BDI; Hamilton test) and 3) QOL measures: Fibromyalgia-Impact-Questionnaire (FIQ); Fibromyalgia-R808-NP2; SF-36. Both groups received a home FM exercise program, according to Fibromyalgia Information Foundation. All patients were assessed for pain before each rESWT and at 6 weeks, 3, 6 and 12 months after treatment.

Results: rESWT showed significant improvement in subjective measures such as local pain (VAS), and objective measures (algometer, Roles & Maudsley, FIQ, pain dimension in SF-36) in treatment group at 6 weeks, 3, 6 and 12 months follow-up compared to placebo, and stabilize at 6 months.

Discussion: Patients maintained long-term benefit 6 months after treatment. At that point, reapplying ESWT could be considered.

Conclusion: rESWT appears to be safe and effective as an early adjunctive therapy in fibromyalgia lasting at least 6 months after treatment.

Therefore, Fibromyalgia is no more an exclusion criterion from ESWT.

18th International Congress of the ISMST 2015, Mendoza, Argentina. Abstract No. 30.

Study Performance: **physiogold50**

4.3.2.Radial Extracorporeal Shockwave Therapy in Fibromyalgia (Ramon et al., 2014)

Dept. of Rehabilitation, Dept. of Rheumatology, Dept. of Orthopedic Surgery, Hospital Quiron, Barcelona, Spain.

Introduction: The purpose of this study is to evaluate the evidence of rESWT in fibromyalgia (FM).

Methods: We performed a randomized, prospective study with 24 FM patients. All patients were female, mean age 52, 13 years (45-67). Patients were divided into two groups and asked to select the 3 most painful myofascial and asymmetrical regions. Both groups received 5 weekly sessions of radial ESWT (rESWT), using 2000 shocks of rESWT at each of the 3 points. Group 1 (treatment) N= 13 treated with 500 shocks, 1,5 bar, 5 Hz; then 1000 shocks, 2 bar, 8 Hz; and 500 shocks, 1,5 bar, 15 Hz; Group 2 (placebo) N= 11 (using a soft rubber cap leaving air between transmitter and the cap) received 500 shocks, 15 Hz; then 1000 shocks, 8 Hz; and 500 shocks, 15 Hz, with the pressure constant 1,5 bar. Outcome variables were: 1) Pain: VAS, algometer (Wagner instruments®) at 3 points and contralateral; McGill Questionnaire; 2) Emotional status (BDI; Hamilton test) and 3) QOL measures: Fibromyalgia-Impact-Questionnaire; Fibromyalgia-R808-NP2; SF-36. Both groups received a home FM exercise program, according to Fibromyalgia Information Foundation. All patients were assessed for pain before each rESWT and at 6 weeks post treatment.

Results: We found clinical improvement on pain at 6 weeks after treatment and excellent-good results according to Roles and Maudsley in FM patients treated compared to placebo, without side effects.

Discussion: Patient follow-up 6 to 12 months post-treatment will determine shockwave efficacy over time.

Conclusion: In a multi-disciplinary approach, rESWT appears to be safe and effective as an early adjunctive therapy in fibromyalgia.

17th International Congress of the ISMST 2014, Milano, Italy.

Study Performance: **physiogold50**



PRECLINICAL STUDIES / BASIC RESEARCH

5. Orthopedics

5.1. Tendinopathies / Soft Tissue Disorders

5.1.1. Shock Waves as Treatment of Mouse Myofascial Trigger Points (Monclús et al., 2023)

Unit of Histology and Neurobiology, Department of Basic Medical Sciences, Faculty of Medicine and Health Sciences, Rovira i Virgili University, Reus, Spain.

Introduction: An abnormal increase in spontaneous neurotransmission can induce subsynaptic knots in the myocyte called myofascial trigger points. The treatment of choice is to destroy these trigger points by inserting needles. However, 10% of the population has a phobia of needles, blood, or injuries. Therefore, the objective of this study is to verify the usefulness of shock waves in the treatment of myofascial trigger points.

Methods: Two groups of mice have been developed for this: healthy muscles treated with shock waves; trigger points affected muscles artificially generated with neostigmine and subsequently treated with shock waves. Muscles were stained with methylene blue, PAS-Alcian Blue, and labeling the axons with fluorescein and the acetylcholine receptors with rhodamine. Using intracellular recording the frequency of miniature endplate potentials (mEPPs) was recorded and endplate noise was recorded with electromyography.

Results: No healthy muscles treated with shock waves showed injury. Twitch knots in mice previously treated with neostigmine disappeared after shock wave treatment. Several motor axonal branches were retracted. On the other hand, shock wave treatment reduces the frequency of mEPPs and the number of areas with endplate noise.

Discussion: Shock waves seem to be a suitable treatment for myofascial trigger points. In the present study, with a single session of shock waves, very relevant results have been obtained, both functional (normalization of spontaneous neurotransmission) and morphological (disappearance of myofascial trigger points). Patients with a phobia of needles, blood, or injuries who cannot benefit from dry needling may turn to noninvasive radial shock wave treatment.

Study Performance: **physiogold50**

5.1.2. Improved Biomechanics in Experimental Chronic Rotator Cuff Repair after Shockwaves is not Reflected by Bone Microarchitecture (Feichtinger et al., 2022)

Ludwig Boltzmann Institute for Experimental and Clinical Traumatology, Vienna, Austria.

AUVA Trauma Center Vienna-Meidling, Vienna, Austria.

Department of Orthopaedic Surgery II, Herz-Jesu Krankenhaus, Vienna, Austria.

Austrian Cluster for Tissue Regeneration, Vienna, Austria.

Purpose: The aim of this study was to investigate the effect of extracorporeal shockwave therapy (ESWT) on bone microstructure as well as the bone-tendon-interface and the musculo-tendinous transition zone to explain the previously shown improved biomechanics in a degenerative rotator cuff tear animal model. This study hypothesized that biomechanical improvements related to ESWT are a result of improved bone microstructure and muscle tendon properties.

Methods: In this controlled laboratory study unilateral supraspinatus (SSP) tendon detachment was performed in 48 male Sprague-Dawley rats. After a degeneration period of three weeks, SSP tendon was reconstructed transosseously. Rats were randomly assigned into three groups (n = 16 per group): control (noSW); intraoperative shockwave treatment (IntraSW); intra- and postoperative shockwave treatment (IntraPostSW). Eight weeks after SSP repair, all rats were sacrificed and underwent bone microstructure analysis as well as histological and immunohistochemical analyses.

Results: With exception of cortical porosity at the tendon area, bone microstructure analyses revealed no significant differences between the three study groups regarding cortical and trabecular bone parameters. Cortical Porosity at the Tendon Area was lowest in the IntraPostSW ($p \leq 0.05$) group. Histological analyses showed well-regenerated muscle and tendon structures in all groups. Immunohistochemistry detected augmented angiogenesis at the musculo-tendinous transition zone in both shockwave groups indicated by CD31 positive stained blood vessels.

Conclusion: In conclusion, bone microarchitecture changes are not responsible for previously described improved biomechanical results after shockwave treatment in rotator cuff repair in rodents. Immunohistochemical analysis showed neovascularization at the musculo-tendinous transition zone within ESWT-treated animals. Further studies focusing on neovascularization at the musculo-tendinous transition zone are necessary to explain the enhanced biomechanical and functional properties observed previously.

Clinical relevance: In patients treated with a double-row SSP tendon repair, an improvement in healing through ESWT, especially in this area, could prevent a failure of the medial row, which is considered a constantly observed tear pattern.

Study Performance: **dermagold100**

5.1.3. Substantial Biomechanical Improvement by Extracorporeal Shockwave Therapy After Surgical Repair of Rodent Chronic Rotator Cuff Tears (Feichtinger et al., 2019)

Ludwig Boltzmann Institute for Experimental and Clinical Traumatology, Vienna, Austria.

Background: Characteristics of chronic rotator cuff tears include continuous loss of tendon structure as well as tendon elasticity, followed by a high failure rate after surgical reconstruction. Several studies have already shown the beneficial effect of extracorporeal shockwave therapy (ESWT) on tissue regeneration in tendon pathologies.

Hypothesis: ESWT improves biomechanical tendon properties as well as functional shoulder outcomes in chronic rotator cuff reconstruction in rodents.

Study design: Controlled laboratory study.

Methods: After tendon detachment and 3 weeks of degeneration, a subsequent transosseous reattachment of the supraspinatus tendon was performed in 48 adult male Sprague-Dawley rats (n = 16 per group). Rodents were randomly assigned to 3 study groups: no ESWT/control group, intraoperative ESWT (IntraESWT), and intra- and postoperative ESWT (IntraPostESWT). Shoulder joint function, as determined by gait analysis, was assessed repeatedly during the observation period. Eight weeks after tendon reconstruction, the rats were euthanized, and biomechanical and gene expression analyses were performed.

Results: Macroscopically, all repairs were intact at the time of euthanasia, with no ruptures detectable. Biomechanical analyses showed significantly improved load-to-failure testing results in both ESWT groups in comparison with the control group (control, 0.629; IntraESWT, 1.102; IntraPostESWT, 0.924; IntraESWT vs control, $P \leq .001$; IntraPostESWT vs control, $P \leq .05$). Furthermore, functional gait analyses showed a significant enhancement in intensity measurements for the IntraPostESWT group in



comparison with the control group ($P \leq .05$). Gene expression analysis revealed no significant differences among the 3 groups.

Conclusion: Clearly improved biomechanical results were shown in the single-application and repetitive ESWT groups. Furthermore, functional evaluation showed significantly improved intensity measurements for the repetitive ESWT group.

Clinical relevance: This study underpins a new additional treatment possibility to prevent healing failure. Improved biomechanical stability and functionality may enable faster remobilization as well as an accelerated return to work and sports activities. Furthermore, as shockwave therapy is a noninvasive, easy-to-perform, cost-effective treatment tool with no undesired side effects, this study is of high clinical relevance in orthopaedic surgery. Based on these study results, a clinical study has already been initiated to clinically confirm the improved functionality by ESWT.

Study Performance: **dermagold100**

5.1.4. Shock Wave Treatment of Muscle Stem Cells – a New Implementation for Regeneration (Fuchs C., Weihs A., et al., 2017)

Austrian Cluster for Tissue Regeneration, Vienna, Austria; University of Applied Sciences Technikum Wien, Department of Biochemical Engineering, Vienna, Austria.

Introduction: Shock waves have recently been exploited for treatment of skeletal muscle especially in the elderly as they can suffer from muscle waste resulting in a high socioeconomic burden.

Material and Method: Murine C2C12 & human C25 myoblasts and primary murine muscle stem have been subjected to shockwave treatment (SWT). Cells were treated in vitro using the dermagold100 device (MTS). Cells were subjected to different energy flux densities, ranging from 0.04 to 0.19 mJ/mm², at a constant number of 100 pulses. The immediate and short term effect of SWT on various signaling pathways and proliferation was investigated.

Results: SWT of myoblasts and muscle stem cells resulted in a higher proliferative capacity compared to their controls in an energy dependent manner. Additionally, signaling pathways known to be essential in regulating proliferation and differentiation were investigated. Our obtained data showed that the AKT mTOR axis seems to play a more pronounced role in muscle (stem) cells rather than MAPK signaling pathways.

Discussion: SWT on muscle cells has a beneficial effect on proliferation and distinct signaling pathways involved in biological processes. Whether various pathways in different species play diverse roles or whether two or more signaling pathways act in concert with each other needs to be further elucidated. A closer look into the activation machinery would give further insight into the effects of SWT on muscle. Finally, investigation of those treated cells in terms of their differentiation potential and regenerative capacity is needed to show the versatility of SWT for regenerative medicine approaches.

Conclusion: The beneficial effect of SWT could induce a new therapeutic application of shock waves for treating patients suffering from muscle waste, which are caused by the lack of functional muscle stem cells due to ageing.

20th ISMST Congress in San Sebastian, Spain. Abstract P29.

Study Performance: **dermagold100**

5.1.5. *The Effect of Shock Waves on In Vitro Cartilage Development in Silk Scaffolds* (Szwarc D., Fuchs C. et al., 2016)

Austrian Cluster for Tissue Regeneration, Vienna, Austria; University of Applied Sciences Technikum Wien, Department of Biochemical Engineering, Vienna, Austria.

Introduction: Osteoarthritis (OA) is a degenerative condition causing joint pain and stiffness and, thereby, severely impairs everyday life of patients. It is predicted that by the year 2030, a quarter of the US population alone will be diagnosed with OA. Silk is a biocompatible and biodegradable biomaterial, which has been implicated in a wide range of applications in biomedical engineering. Silk can be processed into very different forms, from hydrogels to solid bulk material, making it one of the most versatile biomaterials available. Furthermore, its outstanding mechanical properties permit the creation of constructs capable of withstanding physiological loads.

It has been shown that low-energy shock wave treatment (SWT), applied in combination with microfractures, resulted in increased production of cartilage-like tissue, affecting both chondrocytes and the surrounding blood vessels. Moreover, in another study, SWT was proven to slightly improve the differentiation potential of equine adipose tissue-derived mesenchymal stem cells *in vitro*.

Methods: We therefore studied the effect of SWT on articular chondrocytes *in vitro*. This included their expansion *in vitro*, resulting in their dedifferentiation, and finally their redifferentiation into functional cartilage in a silk scaffold upon SWT. We analyzed the distribution of cells within the scaffold, gene expression of cartilage-specific markers, as well as the activation of intracellular signaling pathways *in vitro*.

Results: Silk-based hydrogels and sponges were shown to be suitable scaffolds for cartilage engineering, providing the cells with a robust environment that preserves its architecture during long culture periods. The scaffold alone was shown to promote chondrogenic marker expression in cultured cells. This effect was further increased when SWT was applied.

Discussion: The use of shock wave treatment on chondrocyte-loaded silk scaffolds would provide a novel tool for tissue engineering in cartilage regeneration.

4th ISMST Basic Research Meeting in Vienna, Austria.

Study Performance: **dermagold100** with OP155 applicator

5.1.6. *Soft-focused extracorporeal shock waves increase the expression of tendon-specific markers and the release of anti-inflammatory cytokines in an adherent culture model of primary human tendon cells* (de Girolamo et al., 2014)

Orthopaedic Biotechnology Laboratory, IRCCS Istituto Ortopedico Galeazzi, Milan, Italy.

Focused extracorporeal shock waves have been found to upregulate the expression of collagen and to initiate cell proliferation in healthy tenocytes and to positively affect the metabolism of tendons, promoting the healing process. Recently, soft-focused extracorporeal shock waves have also been found to have a significant effect on tissue regeneration. However, very few *in vitro* reports have dealt with the application of this type of shock wave to cells, and in particular, no previous studies have investigated the response of tendon cells to this impulse. We devised an original model to investigate the *in vitro* effects of soft-focused shock waves on a heterogeneous population of human resident tendon cells in adherent monolayer culture. Our results indicate that soft-focused extracorporeal shock wave treatment (0.17 mJ/mm²) is able to induce positive modulation of cell viability, proliferation and tendon-specific marker expression, as well as release of anti-inflammatory cytokines.



This could prefigure a new rationale for routine employment of soft-focused shock waves to treat the failed healing status that distinguishes tendinopathies.

Study Performance: **orthogold100**, OP155.

5.1.7. Soft Focused Extracorporeal Shockwaves Increase the Expression of Tendon-Specific Markers and the Release of Anti-Inflammatory Cytokines in an Adherent Culture Model of Primary Human Tendon Cells (Vigano et al., 2014)

IRCCS Istituto Ortopedico Galeazzi, Dipartimento di Scienze Biomediche, Chirurgiche ed Odontoiatriche, Università degli Studi di Milano, Milan, Italy.

Introduction: Few in vitro reports investigate the response of tendon cells (TCs) to shockwaves. In particular no one study has already reported data about TCs treated while adhering on culture plate rather than in suspension as usually applied. In this study we first investigated the effect of soft-focused shockwaves on adherent TCs culture, which represents a more physiological-like condition, where cell-to-cell contact could influence the cell response.

Methods: TCs, deriving from 7 healthy donors, were treated while adherent on culture plate, with 1000 shots of soft-focused extracorporeal shockwaves (SF-ESW) at energy of 0.17 mJ/mm². Cells were plated accordingly to the size of the SF-ESW SW focus, in order to treat the whole cell culture. The culture flask was treated after the immersion in a devoted water bath. Viability, proliferation, gene expression of specific markers and release of cytokines and growth factors were assessed.

Results: Shockwaves were able to induce positive modulation of cell viability, proliferation and tendon-specific marker expression, as well as release of anti-inflammatory cytokines and growth factors.

Discussion: We devised an original model to investigate the in vitro effects of soft focused shock waves on TCs in adherent culture, and demonstrate that this kind of treatment could enhance TCs activation, in terms of tissue regeneration, thanks to its anti-inflammatory, proliferative, pro-tenogenic and pro-angiogenic effect.

Conclusion: Our findings could prefigure a new modality of in vitro cell treatment with SF-ESW, where a more physiological-like condition is preserved, allowing more reliable results.

17th ISMST Congress in Milano, Italy. Abstract No. 12.

Study Performance: **orthogold100**, OP155.

5.2. Bone Healing Disorders

5.2.1. Optimization of Screw Fixation in Rat Bone with Extracorporeal Shock Waves (Koolen et al., 2017)

Department of Orthopaedics, University Medical Center Utrecht, UMC Utrecht, G.05.228, P.O. Box 85500, Utrecht 3508 GA, The Netherlands.

Screw fixation in osteoporotic patients is becoming an increasing problem in orthopedic surgery as deterioration of cortical and cancellous bone hamper biomechanical stability and screw fixation. This might result in delayed weight-bearing or failure of instrumentation. We hypothesized that local peri-operative shock wave treatment can optimize osseointegration and subsequent screw fixation. In eight female Wistar rats, two cancellous and two cortical bone screws were implanted in both femora and tibiae. Immediately after implantation, 3.000 unfocused extracorporeal shock waves (energy flux density 0.3 mJ/mm²) were applied to one side. The other side served as non-treated internal control.

Evaluation of osseointegration was performed after 4 weeks with the use of microCT scanning, histology with fluorochrome labeling, and pull-out tests of the screws. Four weeks after extracorporeal shock wave treatment, treated legs exhibited increased bone formation and screw fixation around cortical screws as compared to the control legs. This was corroborated by an increased pull-out of the shock wave treated cortical screws. The cancellous bone screws appeared not to be sensitive for shock wave treatment. Formation of neocortices after shock wave therapy was observed in three of eight animals. Furthermore, de novo bone formation in the bone marrow was observed in some animals. The current study showed bone formation and improved screw fixation as a result of shock wave therapy. New bone was also formed at locations remote from the screws, hence, not contributing to screw fixation. Further, research is warranted to make shock wave therapy tailor-made for fracture fixation.

Study Performance: **orthogold180c**

5.2.2. Shock Wave Therapy for Osteoinduction (Koolen M., ...van der Jagt O. et al., 2017)

Department of Orthopaedics, University Medical Centre Utrecht, Utrecht, The Netherlands.

Introduction: Bone substitutes can be used if human's capacity for bone regeneration is lacking. We think that shock waves (UESW) can improve bone ingrowth and angiogenesis.

Material and Methods: Three different bone substitutes were implanted in a 6 mm femoral defect in rats: porous tricalcium phosphate (TCP), porous hydroxyapatite (HA) and porous titanium. Femurs were treated twice with 1500 UESW 2 & 4 weeks after implantation and compared with non-treated controls (n=B per group). Net bone volume changes were analysed using microCT-scanning. With histology angiogenesis and bone ingrowth was examined.

Results: UESW treated femurs with HA and titanium did have more bone formation during follow-up from 4 to 11 weeks after implantation. The TCP bone substitutes slowly diminished their net volume of calcified matrix during the follow-up period and TCP was insensitive to UESW treatment. Histology confirmed this.

Discussion: In this study we showed that HA and titanium bone substitutes favour from an extracorporeal shock wave treatment, whereas TCP does not. We speculate that this is related to the mechanical characteristics of the bone substitute as well as the bone resorption induction of the TCP.

Conclusion: Shock wave therapy might become a useful tool to enhance bone formation in bone substitutes, but further studies are required to unravel the mechanism behind its osteoinductive effects.

20th ISMST Congress in San Sebastian, Spain. Abstract P33.

Study Performance: **dermagold100**

5.2.3. Unfocused Extracorporeal Shock Waves Induce Anabolic Effects in Osteoporotic Rats (Van Der Jagt et al., 2013)

Orthopaedic Research Laboratory, Erasmus MC, University Medical Center, Room EE-1614, Dr. Molewaterplein 50, PO Box 2040, 3000 CA Rotterdam, The Netherlands.

Unfocused extracorporeal shock waves (UESW) have been shown to have an anabolic effect on bone mass. Therefore, we investigated the effects of UESW on bone in osteoporotic rats with and without anti-resorptive treatment. Twenty-week-old rats were ovariectomized (n = 27). One group was treated



with saline and another group with Alendronate (ALN) 2.4 µg/kg, 3×/week. UESW were applied 2 weeks after ovariectomy. Thousand UESW were applied to one hind leg, the contra-lateral hind leg was not treated and served as control. With the use of in vivo micro-CT scanning it was shown that in saline treated rats trabecular bone volume fraction (BV/TV) was higher at 2 weeks follow-up in UESW treated legs compared to control legs. However, at 4 and 10 weeks no difference was found. In ALN treated animals UESW led to a pronounced anabolic response resulting in an increase in BV/TV at all time-points. Furthermore, UESW resulted in increased cortical volume (CtV), higher trabecular connectivity and, more plate-like and thicker trabeculae. Biomechanical testing showed that UESW lead to a higher maximum force before failure and higher stiffness in all treatment groups. With histology abundant areas of intramembranous bone formation along the periosteal cortex and within the bone marrow were observed. In conclusion this study shows promising results for the use of UESW in the treatment of osteoporosis, especially when this treatment is combined with an anti-resorptive treatment.

Study Performance: **dermagold100**

5.2.4. Unfocused Extracorporeal Shock Waves Induce Anabolic Effects in Rat Bone (Van Der Jagt et al., 2011)

Department of Orthopaedics, Erasmus MC, University Medical Center Rotterdam, The Netherlands.

Background: Extracorporeal shock waves are known to stimulate the differentiation of mesenchymal stem cells toward osteoprogenitors and induce the expression of osteogenic-related growth hormones. The aim of this study was to investigate if and how extracorporeal shock waves affected new bone formation, bone microarchitecture, and the mechanical properties of bone in a healthy rat model, in order to evaluate whether extracorporeal shock wave therapy might be a potential treatment for osteoporosis.

Methods: Thirteen rats received 1000 electrohydraulically generated unfocused extracorporeal shock waves to the right tibia. The contralateral, left tibia was not treated and served as a control. At two, seven, twenty-one, and forty-nine days after administration of the shock waves, in vivo single-photon-emission computed tomography (SPECT) scanning was performed to measure new bone formation on the basis of uptake of technetium-labeled methylene diphosphonate ((99m)Tc-MDP) (n = 6). Prior to and forty-nine days after the extracorporeal shock wave therapy, micro-computed tomography (micro-CT) scans were made to examine the architectural bone changes. In addition, mechanical testing, microcrack, and histological analyses were performed.

Results: Extracorporeal shock waves induced a strong increase in (99m)Tc-MDP uptake in the treated tibia compared with the uptake in the untreated, control tibia. Micro-CT analysis showed that extracorporeal shock waves stimulated increases in both trabecular and cortical volume, which resulted in higher bone stiffness compared with that of the control tibiae. Histological analysis showed intramedullary soft-tissue damage and de novo bone with active osteoblasts and osteoid in the bone marrow of the legs treated with extracorporeal shock waves. Microcrack analysis showed no differences between the treated and control legs.

Conclusions: This study shows that a single treatment with extracorporeal shock waves induces anabolic effects in both cancellous and cortical bone, leading to improved biomechanical properties. Furthermore, treatment with extracorporeal shock waves results in transient damage to the bone marrow, which might be related to the anabolic effects. After further examination and optimization, unfocused extracorporeal shock waves might enable local treatment of skeletal sites susceptible to fracture.

Study Performance: **dermagold100**

5.2.5. *Unfocused Extracorporeal Shock Wave Therapy as Potential Treatment for Osteoporosis* (van der Jagt et al., 2009)

Department of Orthopaedics, Erasmus Medical Center, Rotterdam, the Netherlands.

Extracorporeal shock wave therapy (ESWT) influences the differentiation of bone marrow stroma cells towards osteoprogenitors and increases the expression of several growth factors. To assess whether unfocused ESWT might serve as a treatment for osteoporosis, we examined the bone architecture dynamics of ESWT-treated and untreated rat tibiae using in vivo micro-computed tomography (CT) scanning. In addition, the effects of ESWT on fracture healing, using a bilateral fibula osteotomy, were examined. Unilateral unfocused ESWT with 2,000 pulses and an energy flux density of 0.16 mJ/mm² was applied to the hind leg of ovariectomized and sham-ovariectomized rats. A single treatment with unfocused ESWT resulted in a higher trabecular bone volume fraction (BV/TV) in the proximal tibia of the sham-ovariectomized animals. Three weeks after ESWT, BV/TV was 110% of baseline BV/TV in treated legs versus 101% in untreated contralateral control legs ($p = 0.001$) and 105% of baseline BV/TV versus 95% at 7 weeks after ESWT ($p = 0.0004$). In ovariectomized rats, shock wave treatment resulted in a diminished bone loss. At 7 weeks, the BV/TV of the treated legs was 50% of baseline BV/TV, whereas in untreated control legs this was 35% ($p = 0.0004$). ESWT did not influence acute fracture healing. This study shows that bone microarchitecture can be affected by unfocused shock waves, and indicates that unfocused ESWT might be useful for the treatment of osteopenia and osteoporosis.

Study Performance: **dermagold100** / **orthowave180**

5.2.6. *Unfocused Extracorporeal Shockwave Therapy Diminishes Bone Loss in Rats* (Olav P van der Jagt et al., 2008)

Department of Orthopaedics, Erasmus Medical Center, Rotterdam, the Netherlands.

Introduction: Extracorporeal Shockwave (ESW) therapy has shown to be effective in the treatment of non-unions and can enhance healing of fresh fractures. Enhanced proliferation and differentiation of osteoprogenitor cells have been shown in rats after a single ESW treatment. These studies used focused shockwaves; nowadays unfocused shockwaves can be generated, enabling treatment of larger areas without the need for anesthesia. Therefore, extracorporeal shockwave therapy might be useful in the treatment of osteoporosis. We evaluated if unfocused electro-hydraulically generated ESW can reduce bone loss and/or enhance fracture healing in ovariectomized and healthy rats.

Materials and Methods: 48 Female Wistar rats, 20 weeks of age were obtained. To induce bone depletion ovariectomy (OVX) was performed. ESW therapy (Dermagold, MTS-Europe GmbH, Konstanz, Germany) was given to the antero-lateral side of the right leg, the untreated left leg served as control. Two treatment regimens were used: a single treatment with 2000 pulses, 0.13 mJ/mm², or two treatments with three weeks in between with 1000 pulses, 0.13 mJ/mm². The legs were treated 3 (and 6) or 10 (and 13) weeks after OVX. Two days before the first ESW treatment a bilateral fibula osteotomy was performed to evaluate effects on fracture healing. A group with sham-OVX and a fibula osteotomy was treated with 2000 pulses, to evaluate effects in healthy bone. Control groups to check for interactions between the osteotomy and ovariectomy were also evaluated. N=6 for all groups. Under gas anesthesia in-vivo microCT scans of the proximal tibia of the treated and untreated legs were made just before ESW treatment and 3, 6 and 10 weeks thereafter. In vivo microCT allows longitudinal follow-up of a single rat making it possible to evaluate dynamic bone changes in a highly detailed manner (voxelsize of 18 microns). Binary datasets of reconstructed images were made using a local threshold



algorithm. A region of interest containing the proximal metaphysis was selected manually (length of 5,4mm), cortical and trabecular bone were automatically separated. Bone morphologic parameters of both were calculated (see Fig. 1). To evaluate the effect of ESW on fracture healing, a cylindrical region of interest 2mm in length was made around the osteotomy. A global threshold was used to determine the amount of mineralized matrix see (Fig. 1). All outcome measures were statistically evaluated using the Wilcoxin signed rank test.

Results: ham-ovariectomized rats showed enhanced trabecular bone formation after shockwave therapy. Treated legs showed an increase of the trabecular volume fraction of 5% 7 weeks after treatment, whereas the non-treated legs showed a 5% decrease over the same period ($p=0.03$) (Fig. 2A). The cortical volume did not change significantly. Other bone morphologic parameters were not different in treated and untreated legs. The treated legs of rats suffering bone loss due to OVX that received shockwave therapy 3 weeks after OVX showed a slightly larger bone volume than the contralateral untreated legs, when they were treated with 2000 pulses (Fig. 2B). Cortical bone volume was not different between treated and untreated legs. No statistically significant effect of treatment was found in rats suffering bone loss due to OVX that received shockwave therapy after 10 weeks. There was no difference in mineralized callus formation in the fibula osteotomy between treated and non-treated legs in all treatment groups.

Discussion: A single treatment of 2000 pulses resulted in enhanced trabecular bone formation in sham-ovariectomized rats. The bone formation was only seen in the cancellous bone, which suggests that shockwave therapy influences bone remodeling and is therefore most effective in regions with a high remodeling rate. Cortical bone remodeling is almost absent in normal rats. The beneficial effect on trabecular volume fraction was also seen in rats that were shockwaved 3 weeks after OVX. However, in rats that were treated 10 weeks after OVX no effect of shockwave was found. This suggests that ESW affects bone remodeling and causes effects in existing bone structures, but cannot induce de novo bone formation. Because bone structures are still seen in the marrow cavity of patients suffering severe osteoporosis, ESW might be able to induce bone formation in these patients. No effect on fracture healing was found. Previous studies that showed enhanced fracture healing used focused shockwaves instead of the unfocused used here; this might explain the difference in outcome. Unfocused shockwaves can be given without anesthesia and to regions large enough to treat those sites specifically prone for fracturing in osteoporosis, e.g. hip, vertebrae and distal radius and might serve as a(n) (additive) treatment in osteoporosis.

54th Annual Meeting of the Orthopaedic Research Society, Poster No. 964.

Study Performance: **dermagold100** / **orthowave180**

5.3. Orthodontics

5.3.1. *The Effect of Shock Waves on Mineralization and Regeneration of Distraction Zone in Osteoporotic Rabbits* (Özkan et al., 2023)

Department of Oral and Maxillofacial Surgery, Faculty of Dentistry, Istanbul Medeniyet University, Istanbul, Turkey.

Objective: Osteoporotic individuals suffer from various complications such as spontaneous bone fractures due to decreased bone strength and failure in bone healing as a result of decreased bone mineral density and deterioration of bone microstructure. In this study, the effects of Extracorporeal Shock Wave Therapy (ESWT) in a distraction osteogenesis model in osteoporotic rabbits were investigated to prevent these failures and improve bone microstructure.

Material and methods: A total of 28 female New Zealand rabbits underwent mandibular distraction osteogenesis and were divided into four groups: non-ovariectomized control (Cont), ovariectomized control (O-Cont), ovariectomized ESWT1 (O-ESWT1) and ovariectomized ESWT2 (O-ESWT2). ESWT was only applied to the ESWT2 group before the osteotomy, and to both the ESWT1 and ESWT2 groups after the osteotomy. Dual-energy x-ray absorptiometry was used to determine bone mineral density on both the 7th and 28th day of the consolidation. Stereological methods were used to identify new bone formation, connective tissue and neoangiogenesis volume.

Results: According to the dual-energy x-ray absorptiometry examination both at the 7th and 28th day of the consolidation, lower bone mineral density was seen in the ESWT groups. However, the stereological examination showed that shock wave therapy significantly increased new bone formation both ESWT1 and ESWT2 compared with O-Cont, significantly increased neoangiogenesis in O-ESWT1 compared with O-Cont.

Conclusions: The application of ESWT in these parameters after osteotomy was beneficial for bone regeneration in mandibular distraction in osteoporotics. However, ESWT has been shown to be ineffective in improving bone mineral density. KEY MESSAGES The osteoporotic model can be successfully established in rabbits and the subjects can tolerate the distraction procedures. Stereology is a useful analysis method that can determine the volume of the new bone formation and neoangiogenesis. Extracorporeal shock wave therapy has biostimulatory effects on bone tissue.

Study Performance: **dermagold100**

5.3.2. Orthodontic Force and Extracorporeal Shock Wave Therapy: Assessment of Orthodontic Tooth Movement and Bone Morphometry in a Rat Model (Hazan-Molina et al., 2022)

Department of Orthodontics and Craniofacial Anomalies, School of Graduate Dentistry, Rambam Health Care Center and Technion Haifa, Israel.

Objective: The objective was to investigate the effect of extracorporeal shock wave therapy (ESWT) on the magnitude of orthodontic tooth movement, in a rat model, based on a previously established treatment protocol.

Design: In conjunction with orthodontic force commencement, rats underwent ESWT. The amount of tooth movement along with different microarchitectural parameters were measured after three weeks by means of microcomputed tomography. In addition, the percentage of cells expressing vascular endothelial growth factor, the number of tartrate-resistant acid phosphatase (TRAP) positive cells/area and blood vessel density were evaluated both for the pressure and tension sides.

Results: The addition of ESWT to the orthodontic force after three weeks more than doubled the average tooth movement. The addition of ESWT on the pressure side induced a significant decrease in volumetric bone mineral density. Blood vessel density and the number of TRAP positive cells were higher after the application of ESWT.

Conclusion: The induction of ESWT during orthodontic tooth movement in a rat model increases the rate of tooth movement by accelerating bone resorption on the pressure side and possibly enhances bone formation on the tension side.

Study Performance: **dermagold100**

5.3.3. Dose-Related Effects of Extracorporeal Shock Waves on Orthodontic Tooth Movement in Rabbits (Demir & Arici, 2021)

Department of Orthodontics, Faculty of Dentistry, Ondokuz Mayıs University, Atakum, Samsun, Turkey.



The purpose of this animal study is to investigate the quantitative effects of extracorporeal shock waves applied at two different impulses and with two different applicators on orthodontic tooth movement. Thirty-five New Zealand rabbits were randomly divided into five groups ($n = 7$): the four experimental extracorporeal shock wave groups-focused/500 impulses, focused/1000 impulses, unfocused/500 impulses, and unfocused/1000 impulses-and the control group. Orthodontic tooth movement was achieved by application of reciprocal force between two maxillary incisors. In the experimental groups, animals received 500 or 1000 impulses of extracorporeal shock waves at 0.19 mJ/mm^2 with focused or unfocused applicators depending on the group to which they belonged. These experiments were conducted on days 0, 7, and 14. Orthodontic tooth movement was measured with 0.01 mm accuracy at one-week intervals. On days 7 and 21, the bone-specific alkaline phosphatase levels were measured from blood samples. After 21 days, the animals were sacrificed and the area between the two maxillary incisors was stereologically examined. Orthodontic tooth movement in the focused/500 impulses and focused/1000 impulses groups was significantly increased compared to the control group. A significant difference in bone-specific alkaline phosphatase levels between the unfocused/500 impulses and control groups was found at 21st day. Stereological analysis showed that there were significant increases of the formation of new bone, connective tissue, and vessels in the experimental groups. The application of extracorporeal shock waves, especially with a focused applicator, could accelerate orthodontic tooth movement.

Study Performance: orthogold100, Applicator OE050 and OP155

5.3.4. Extracorporeal Shock-Wave Therapy or Low-Level Laser Therapy: Which is More Effective in Bone Healing in Bisphosphonate Treatment? (Göl et al., 2020)

Department of Oral and Maxillofacial Surgery, Oral and Dental Health Hospital, Samsun, Turkey.

Objectives: Bisphosphonate-related osteonecrosis of the jaw is potential side effect of long-term bisphosphonate therapy. Different treatment modalities have been used in this and investigate the effects of low-level laser therapy (LLLT) and extracorporeal shockwave therapy (ESWT) on socket healing after tooth extraction in rats given long-term bisphosphonates.

Methods: Forty male Wistar-Albino rats were used in this experimental study. About 0.1 mg/kg zoledronic acid was administered intraperitoneally to all animals 3 times per week for 8 weeks. Four groups were made which were control, LLLT, ESWT, and ESWT+LLLT. Upper right first molar teeth extraction was performed in all groups; no treatment was given to the control group after molar tooth extraction. About 810 nm wavelength GaAlAs laser was used in LLLT group. In ESWT group, 1000 pulses, 0.21 mJ/mm ESWT was applied, and the 2 treatment methods were applied to the last ESWT+LLLT group at the same time. All the 4 groups were divided into 2 subgroups according to sacrifice time 4 and 8 weeks. Serologic, histologic, and immunohistochemical examinations were performed.

Results: The highest new bone volume was observed in the early LLLT+ESWT. New vessel volume and CD31 expression were found to be high in the LLLT group. Matrixmetalloproteinase (MMP)-2 expression was found increased by the application of LLLT and ESWT.

Conclusion: The LLLT and ESWT have similar effect on socket healing in the early period and that co-use is more effective upon healing. The LLLT has been shown to increase CD31 expression and increase vascularization and soft-tissue healing.

Study Performance: orthogold100, Applicator OP155

5.3.5. Effect of Electrohydraulic Extracorporeal Shockwave Therapy on the Repair of Bone Defects Grafted with Particulate Allografts. (Özkan et al., 2019)

Department of Oral and Maxillofacial Surgery, Bafra Oral and Dental Health Hospital, Samsun, Turkey.

This study determined the effect of electrohydraulic extracorporeal shockwave therapy (ESWT) on the healing of mandible defects repaired using particulate allogenic bone grafts. This study included 20 male Wistar rats aged 12 weeks. In all the animals, a critical-sized defect of 4-mm diameter was created in the mandible and the defect area was filled with particulate allograft. Next, the rats were divided into 2 groups, allograft (G) (n = 10) and allograft + ESWT (GE) (n = 10). On days 3, 5, and 7 after the grafting, rats in the GE group received ESWT involving 200 pulses with an energy flux density of 0.19 mJ/mm. Five rats in each group were sacrificed at the end of week 4 and at the end of week 8. Defect areas were examined radiologically by performing high-resolution computed tomography and stereologically by using the Cavalieri method. Obtained data were compared by performing statistical analysis. Radiological evaluation showed that bone density was higher in rats in the G group than in those in the GE group at week 4. In contrast, bone density was higher in rats in the GE group than in those in the G group at week 8. Stereological examination showed that new bone, connective tissue, and capillary volumes were higher in rats in the GE group than in those in the G group at both weeks 4 and 8. The authors' results indicate that repeated doses of ESWT accelerate the healing of bone defects repaired using allogenic bone grafts.

Study Performance: **orthogold100**

5.3.6. The Assessment of New Bone Formation Induced by Unfocused Extracorporeal Shock Wave Therapy Applied on Pre-Surgical Phase of Distraction Osteogenesis. (Senel et al., 2019)

Department of Oral and Maxillofacial Surgery, Faculty of Dentistry, Pamukkale University, Denizli, Turkey.

Purpose: This study aims to evaluate the effects of extracorporeal shock wave therapy applied before and/or immediately after the osteotomy on the maturation during the consolidation phase.

Materials and methods: 21 female New Zealand rabbits were used in the study. Subjects were divided randomly into three groups: Control (Distraction without ESWT), A (Distraction +ESWT After Osteotomy), AB (Distraction+ESWT After and Before Osteotomy). ESWT (500 pulses, 5 Hz, 0.19 mJ/mm² energy flux density) was applied to group A and group AB after 5, 12 and 19 days after osteotomy and group AB only on days 7,14 and 21 before osteotomy. On the 28th day of the consolidation period, all subjects were sacrificed. Dual-energy x-ray absorptiometry (DEXA) was used to determine bone mineral density (BMD) and bone mineral content (BMC), and stereological methods were used to determine the new bone, connective tissue and neovascularization volumes.

Results: As a result of DEXA examinations made on the 1st and 4th week of consolidation, there was no significant difference between groups regarding BMD and BMC values. According to the results of stereological examination, when the connective tissue and new bone tissue were evaluated, higher values were observed in AB when compared to A, and in AB and A compared to the control group, but the differences are not statistically significant. There was no difference between the groups in terms of neovascularization.

Conclusion: ESWT in these parameters was not positively effective in bone maturation during consolidation when applied before osteotomy or both before and after osteotomy.

Study Performance: **orthogold100**

5.3.7. Effects of Timing of Extracorporeal Shock Wave Therapy on Mandibular Distraction Osteogenesis: An Experimental Study in a Rat Model (Ginini et al., 2019)



Faculty of Medicine at the Technion-Israel Institute of Technology, and the Department of Anatomy and Anthropology, Sackler Faculty of Medicine, Tel-Aviv University.

Purpose: Distraction osteogenesis (DO) is an established method for bone lengthening in the craniofacial skeleton. Its major drawback is the long consolidation period with attendant morbidity and possible complications. Several methods have been suggested to shorten the consolidation period. We evaluated the timing and effects of extracorporeal shock wave therapy (ESWT) on bone mineralization and extracellular bone matrix proteins during mandibular DO.

Materials and methods: Twenty-seven rats underwent mandibular DO (latency period, 3 days; distraction period, 10 days; 0.5 mm/day) and were divided into 3 groups according to the timing of ESWT application: group I (control) received no treatment, whereas groups II and III received ESWT (0.18 mJ/mm²) before and after the active distraction period, respectively. The distracted mandibles were harvested after 4 weeks of consolidation and analyzed radiographically, histologically, and immunohistochemically.

Results: Group III showed significantly increased mineral density, enhanced bone formation, a higher collagen orientation index, and greater expression of type I collagen and osteocalcin proteins.

Conclusions: Application of ESWT after active distraction enhances bone maturation and mineralization.

Study Performance: **dermagold100**

5.3.8. The Effect of Unfocused Extracorporeal Shock Wave Therapy on Bone Defect Healing in Diabetics (Özkan et al., 2018)

Bafra Oral and Dental Health Hospital, Samsun, Turkey.

Aim: The purpose of this study was to evaluate the effect of the unfocused extracorporeal shock wave therapy (ESWT) on healing of mandible ramus defects in diabetic rats.

Material and method: Forty male Wistar albino rats were used in the experiment. All animals were randomly divided into 2 main groups, nondiabetic and diabetic. Critical-sized defects were created on ramus in all rats. ESWT was performed to half of rats in each group at 3 sessions after surgery. Animals were euthanized at either fourth or eighth week. Stereological and radiologic examination was performed. Data were statistically analyzed by one-way variance analysis and Tukey post-hoc test.

Results: Hounsfield Unit values were higher in DE group than DE group in both 8-week and 4-week groups ($P > 0.05$). In both 4-week and 8-week diabetic groups, higher value was observed when compared with nondiabetic groups ($P > 0.05$). According to stereological results, in 4-week groups, there was a higher new bone, connective tissue, and neovascularization volume in DE group than DE group and in DE group than DE group. These results are similar for the 8-week groups except NV volume.

Conclusion: It was found that ESWT application has no positive effect on the healing of critical-sized bone defects in nondiabetics whereas promising effects in diabetics were observed.

Study Performance: **orthogold100**

5.3.9. The Effect of Different Doses of Extracorporeal Shock Waves on Experimental Model Mandibular Distraction (Berek et al., 2018)

Department of Oral and Maxillofacial Surgery, Faculty of Dentistry, Ondokuz Mayıs University, Samsun, Turkey.

Objective: Distraction osteogenesis (DO) is widely used treatment for the bone deformities. In addition, extracorporeal shock wave therapy (ESWT) is a new perspective on noninvasive modalities of management of the bone regeneration. We examined the effects of 2 different single doses of ESWT on the consolidation period of DO of the rabbit mandible using stereological, radiological and immunohistochemical methods in the present study.

Methods: DO was performed unilaterally in the mandible of 18 New Zealand rabbits (6 months' old, weighing between 2.5 and 3 kg). The distraction zone of the mandible has received no treatment as controls. Group 2 (ESWT 500) received ESWT (single dose of 500 impulses 0.19 mJ/mm energy flux intensity and 2155 mJ totally) were applied on the first day of the consolidation. Group 3 (ESWT 1000) treated with ESWT (single dose of 1000 impulses 0.19 mJ/mm energy flux intensity and 4310 mJ totally) were applied on the first day of the consolidation period. After the sacrifice, radiologically bone mineral density, new bone formation, new fibrous tissue, and new vessel formation were analyzed using unbiased stereological methods.

Results: It was found a statistically significant difference between the study groups and control group in the bone mineral density measurements and the highest values were in the ESWT1000 group. In terms of stereological analysis, there was a significant difference between the study groups and control group ($P = 0.00$). The new capillary volume was highest in the E1000 group. Additionally, significant differences were found in point of the capillary volumes between the groups control and ESWT500 ($P = 0.001$), control and ESWT1000 ($P = 0.000$), ESWT500 and ESWT1000 ($P = 0.040$), respectively.

Conclusions: A total of 1000 impulses ESWT may induce the growth factors to enhance the newly formed bone regeneration.

Study Performance: **orthogold100**

5.3.10. *Extracorporeal Shockwave Treatment Impedes Tooth Movement in Rats* (Atsawasuwan et al., 2018)

Department of Orthodontics, University of Illinois at Chicago, College of Dentistry, 801 S. Paulina St, Chicago, Illinois 60612 USA.

Background: Accelerated tooth movement has been a topic of interest for orthodontic research recently. Surgically facilitated orthodontic treatment has been shown to be an effective approach to accelerate tooth movement; however, it remains invasive, requires additional surgery, and may increase post-operative complications. In this study, we evaluate the effects of extracorporeal shockwave treatment (ESWT), a non-invasive approach to regenerate alveolar bone, on orthodontic tooth movement in rats.

Materials and methods: Seventy-two male rats, aged 10 weeks old, were subjected to 10-cN closed-coil nickel-titanium springs for unilateral maxillary first molar tooth movement. One group of rats received a single treatment of extracorporeal shockwave treatment at 500 impulses at energy flux density 0.1 mJ/mm^2 , with a pulse rate of 5 pulses per second immediately after spring installation while the non-ESWT-treated group served as a control group. The rats were sacrificed at day 3, 7, 14, 21 and 28 for tooth movement evaluation and sample analyses. Faxitron radiography, histological, double bone labeling and gene expression analyses were performed. Serum biochemistry was evaluated at day 3, 7 and 28 of the study. Kruskal-Wallis analysis of variance was used to determine the mean difference among groups, and multiple comparisons were analyzed by Mann-Whitney-U tests with a significance level = 0.05.

Results: The results demonstrated that tooth movement in the ESWT-treated rats ($0.11 \pm 0.07 \text{ mm}$) was impeded compared to the tooth movement in the non-ESWT-treated rats ($0.44 \pm 0.09 \text{ mm}$). ESWT up-regulated several osteoblastic and osteoclastic gene markers and cytokines; however, the effects



on osteoclasts were only transient. Double-fluorescence bone labeling demonstrated that osteoblastic activity increased after ESWT treatment. There was no difference in systemic RANKL/OPG ratio between groups.

Study Performance: **vetgold100**

5.3.11. Is it Possible to Change the Duration of Consolidation Period in the Distraction Osteogenesis with the Repetition of Extracorporeal Shock Waves? (Onger et al., 2017)

PhD. Asst. prof. Histology and Embryology, School of Medicine, Ondokuz Mayıs University, Samsun, Turkey.

Background: In this study we examined the effects of two different repeated Extracorporeal Shock Waves (ESW) on the consolidation period of the distraction osteogenesis (DO) of the rabbit mandible using stereological, radiological and immunohistochemical methods.

Material and methods: DO was performed unilaterally in the mandible of 18 New Zealand rabbits (six months old, weighing between 2.5-3 kg). In the consolidation period, rabbits were divided into three groups randomly after the distraction period. The distraction zone of the mandible was received no treatment as controls (E0*2). Group 2 (E 500*2) received ESWT (twice 500 impulses at 14 kV and 0.19 mJ/mm² energy) in the first and fourth days of the consolidation. Group 3 (E1000*2) treated with ESWT (twice 1000 impulses at 14 kV and 0.19 mJ/mm² energy) in the first and fourth days of the consolidation period. After the sacrifices, radiologically bone mineral density, new bone formation, new fibrous tissue and new vessel formation were analyzed by stereological.

Results: It was found a statistically significant difference between the study groups and control group in the bone mineral density measurements and the highest value was in the E1000*2 group. In the stereological analysis, new bone formation was highest in the E1000*2 group and there was a significant difference compared to the other groups (E0*2 and E500*2) (p=0.000). The lowest connective tissue volume was found in the E500*2 and there was a significant difference compared to the other groups (E0*2 and E1000*2) (p=0.000). The volume of the new vessel was highest in the E500*2 and lowest in the E0*2 group. It was found statistically significant difference between the values of the study and control groups.

Conclusions: Interestingly, we found that repetition of the 1000 impulses ESWT accelerated the consolidation, 500 impulses ESWT extended consolidation period of the DO.

Study Performance: **orthogold100** device with applicator OE050

5.3.12. Effects of Shock Waves on Expression of IL-6, IL-8, MCP-1, and TNF-α Expression by Human Periodontal Ligament Fibroblasts: An In Vitro Study (Cai et al., 2016)

School and Hospital of Stomatology, Fujian Medical University, Fuzhou, Fujian, P.R. China.

Background: Extracorporeal shock wave therapy (ESWT) can modulate cell behavior through mechanical information transduction. Human periodontal ligament fibroblasts (hPDLF) are sensible to mechanical stimulus and can express pro-inflammatory molecules in response. The aim of this study was to evaluate the impacts of shock waves on interleukin-6 (IL-6), interleukin-8 (IL-8), monocyte chemotactic protein 1 (MCP-1), and tumor necrosis factor-alpha (TNF-α) expression by hPDLF.

Material/methods: After being treated by shock waves with different parameters (100-500 times, 0.05-0.19 mJ/mm²), cell viability was tested using CCK-8. IL-6, IL-8, MCP-1, and TNF-α gene expression was analyzed by quantitative real-time polymerase chain reaction (qRT-PCR) and IL-6 and IL-8 protein was measured by enzyme-linked immunosorbent assay (ELISA) at different time points.

Results: Shock waves with the parameters used in this study had no significant effects on the viability of hPDLF. A statistical inhibition of IL-6, IL-8, MCP-1, and TNF- α expression during the first few hours was observed ($P<0.05$). Expression of IL-8 was significantly elevated in the group receiving the most pulses of shock wave (500 times) after 4 h ($P<0.05$). At 8 h and 24 h, all treated groups demonstrated significantly enhanced IL-6 expression ($P<0.05$). TNF- α expression in the groups receiving more shock pulses (300, 500 times) or the highest energy shock treatment (0.19 mJ/mm^2) was statistically decreased ($P<0.05$) at 24 h.

Conclusions: Under the condition of this study, a shock wave with energy density no higher than 0.19 mJ/mm^2 and pulses no more than 500 times elicited no negative effects on cell viability of hPDLF. After a uniform initial inhibition impact on expression of inflammatory mediators, a shock wave could cause dose-related up-regulation of IL-6 and IL-8 and down-regulation of TNF- α .

Study Performance: **dermagold100** with applicator OP155

5.3.13. *The Influence of Shockwave Therapy on Orthodontic Tooth Movement Induced in the Rat* (Hazan-Molina et al., 2016)

Dept. of Anatomy and Cell Biology, Technion - Israel Institute of Technology, Haifa, Israel.

Shockwave therapy is used in medicine due to its ability to stimulate healing processes. The application of orthodontic force evokes an inflammatory reaction resulting in tooth movement. Shockwave therapy might have an effect on both inflammatory and periodontal ligament cytokine profiles. Our aim was to evaluate the fluctuations of different inflammatory cytokines after orthodontic force induction with and without shockwave therapy. An orthodontic appliance was applied between the rats' molars and incisors. In conjunction with the commencement of orthodontic force, the rats were treated with a single episode of 1000 shock waves and the gingival crevicular fluid was collected for 3 days. The expression and concentration of different cytokines was evaluated by a commercial 4-multiplex fluorescent bead-based immunoassay. The level of all cytokines displayed a similar trend in both shockwave-treated and untreated groups; the concentration peaked on the first day and declined thereafter. In all cases, however, the cytokine levels were smaller in the shockwave-treated than in untreated animals; a significant difference was found for sRANKL and borderline difference for IL-6 on Day 1. We conclude that shockwave therapy during the induction of orthodontic tooth movement influences the expression of inflammatory cytokines.

Study Performance: **dermagold100**

5.3.14. *Periodontal Cytokines Profile under Orthodontic Force and Extracorporeal Shock Wave Stimuli in a Rat Model* (Hazan-Molina et al., 2015)

Orthodontic and Craniofacial Department, Graduate School of Dentistry, Rambam Health Care Campus and the Rappaport Faculty of Medicine, Technion – Israel Institute of Technology, Haifa, Israel.

Background and objective: Extracorporeal shock wave therapy has been used in various clinical conditions as a result of its ability to stimulate healing processes in acute and chronic inflammatory states. Orthodontic force application triggers an inflammatory reaction in the periodontal tissue surrounding the involved teeth, resulting in tooth movement. Preliminary work revealed that extracorporeal shock wave therapy increased the expression of the inflammatory cytokines involved. Our aim was to investigate the expression of inflammatory cytokines in the periodontal tissues following orthodontic force induction, with and without shock wave therapy, in experimental rats.



Material and methods: An orthodontic appliance was fabricated and applied between the molars and the incisors of adult Wistar rats. In conjunction with orthodontic force commencement, the rats were treated with a single episode of 1000 shock waves. Every day, during the 3 d of the study, rats were killed and the immunolocalization of RANKL, interleukin (IL)-1 β , IL-6 and tumor necrosis factor-alpha was evaluated.

Results: The percentage of the area staining positively for all inflammatory cytokines during the first 2 d decreased statistically significantly more in the shock wave-treated group compared with the nontreated control group. On the first day, the percentage of the area staining positively for IL-1 β and RANKL on the compression side peaked in both groups, with a sequential rise in the number of TRAP-positive cells.

Conclusion: The induction of shock wave therapy during orthodontic tooth movement influences the expression of different inflammatory cytokines in the tissue and might alter the expected periodontal remodeling rate.

Study Performance: **dermagold100**

5.3.15. *Assessment of IL-1 β and VEGF Concentration in a Rat Model During Orthodontic Tooth Movement and Extracorporeal Shock Wave Therapy* (Hazan-Molina et al., 2012)

Orthodontic and Craniofacial Department, School of Graduate Dentistry, Rambam Health Care Campus, Bruce Rappaport Faculty of Medicine, Technion – Israel Institute of Technology, Haifa, Israel.

Objective: This study aimed to investigate PDL's cytokine concentration fluctuations after induction of orthodontic force with and without extracorporeal shock wave therapy in a rat model.

Materials and methods: An orthodontic appliance was fabricated and applied between the molars and the incisors of rats. The rats were treated by a single episode of 1000 shock waves and gingival crevicular fluid was collected for 3 days. The expression and concentration of IL-1 β and VEGF were evaluated by ELISA assay. On day 3 all rats were sacrificed and histologic and immunohistochemical assays were applied.

Results: IL-1 β concentration rose in both the treated and non-treated shockwave groups on the first day, however it was statistically significantly higher in the treated group on day 2. No statistically significant difference was detected between the groups on day 3. The number/area of TRAP positive cells was higher in the non-shockwave group than in the treated group. The percentage of cells expressing VEGF displayed the opposite trend. The findings regarding the immunohistochemical assay for IL-1 β corresponded with those of the ELISA assay on day 3.

Conclusion: The application of shockwaves during orthodontic tooth movement influences the expression of IL-1 β and VEGF and may alternate the periodontal remodeling expected rate.

Study Performance: **dermagold100**

5.3.16. *Effects of Low-Energy Shock Waves on Oral Bacteria* (Novak et al., 2008)

Center for Oral Health Research, College of Dentistry, University of Kentucky, 414, Health Sciences Research Building, Lexington, KY 40536-0305, USA.

We have recently demonstrated that extracorporeal shock-wave therapy (ESWT) is effective in promoting the healing of dermal wounds and in regenerating alveolar bone lost through periodontal disease. The objective of the present study was to determine any antibacterial effect of ESWT on oral bacteria. Monoculture suspensions of 6 bacterial species were treated with 100 to 500 pulses of ESWT at energy flux densities (EFD) of 0.12 mJ/mm², 0.22 mJ/mm², and 0.3 mJ/mm². Following treatment,

aliquots were plated for viability determination and compared with untreated controls. ESWT showed a significant microbicidal effect for *Streptococcus mutans* and an unencapsulated strain of *Porphyromonas gingivalis* following as few as 100 pulses at 0.3 mJ/mm² ($p \leq 0.001$). In addition, a significant disruption of bacterial aggregates was observed at lower EFDs. No significant reduction in viability was observed for all other bacteria at EFDs and pulses tested ($p > 0.05$). These findings suggest that low-energy ESWT may be bactericidal for selected oral bacteria.

Study Performance: **dermagold100**

5.3.17. *Extracorporeal Shock Wave Therapy Induces Alveolar Bone Regeneration* (Sathishkumar et al., 2008)

Department of Periodontology, College of Dentistry, D11-24, University of Florida, Gainesville, FL 32610, USA. Trauma Center Meidling, Vienna, Austria.

Periodontal inflammation with alveolar bone resorption is a hallmark of periodontitis. We hypothesized that extracorporeal shock wave therapy (ESWT) could promote the regeneration of alveolar bone following *Porphyromonas gingivalis*-induced periodontitis in rats. Rats were infected with *P. gingivalis* for 10 wks, which caused alveolar bone resorption. The rats were then treated with a single episode of 100, 300, or 1000 impulses of shock wave on both cheeks at energy levels 0.1 mJ/mm². Alveolar bone levels were determined at 0, 3, 6, and 12 wks following ESWT and compared with those in untreated controls. Infected rats treated with 300 and 1000 impulses demonstrated significantly improved alveolar bone levels at 3 wks compared with untreated controls, and the improved levels remained for at least 6 wks in most rats. The results demonstrated effective regeneration of alveolar bone by ESWT and suggested that ESWT should be evaluated as an adjunct in the regeneration of periodontal tissues following periodontal disease.

Study Performance: **dermagold100**

5.3.18. *Effects of Unfocused Extracorporeal Shock Waves on Gram-Positive and Gram-Negative Bacteria* (Novak et al., 2007)

Department of Periodontology, College of Dentistry, D11-24, University of Florida, Gainesville, FL 32610, USA. Trauma Center Meidling, Vienna, Austria.

Introduction: Extracorporeal shock wave therapy (ESWT) has been used for a multitude of applications in modern medicine. Although there is information on the effects of focused ESWT on eukaryotic and prokaryotic systems, there are currently no published studies on the effects of unfocused ESWT on either.

Methods: This study was designed to determine the effect of electro-hydraulic, unfocused ESWT on Gram-positive and Gram-negative, aerobic and anaerobic bacteria *Porphyromonas gingivalis* 381, *Porphyromonas gingivalis* W83, *Fusobacterium nucleatum* ATCC 49256, *Actinomyces naeslundii* ATCC 49340, *Streptococcus mutans* ATCC 25175 and *Staphylococcus aureus* ATCC 12600. Monoculture suspensions were treated with 100 to 500 pulses of ESWT at energy flux densities (EFD) of 0.12 mJ/mm², 0.22 mJ/mm² and 0.3 mJ/mm². Following treatment, aliquots were plated for viability determination and compared with untreated controls.

Results: ESWT showed a significant antibacterial effect for *S. mutans* and an unencapsulated strain of *P. gingivalis* following as little as 100 pulses at 0.3 mJ/mm² ($p < 0.001$). In addition, a significant disruption of bacterial aggregates was observed at lower EFDs. No significant reduction in viability was observed for all other bacteria at EFDs and pulses tested ($p > 0.05$).



Discussion: Unfocused ESWT appears to be able to disrupt bacterial aggregates and kill specific aerobic and anaerobic bacteria. This may be beneficial as adjunctive therapy for the treatment of bacterial biofilms in specific conditions.

Conclusion: ESWT appears to be antibacterial for selected Gram positive and Gram negative aerobic and anaerobic bacteria associated with human disease.

10th International Congress of the ISMST 2007 in Toronto, Canada, Abstract 32.

Study Performance: **dermagold100**

5.3.19. Extracorporeal Shock Wave Therapy Induces Alveolar Bone Regeneration in Experimental Periodontitis (Satishkumar et al., 2007)

Department of Physiology, University of Kentucky, Lexington, KY 40536, USA. Trauma Center Meidling, Vienna, Austria.

Introduction: Periodontal inflammation with alveolar bone resorption is one of the hallmarks of periodontal disease, elicited in response to several periodontal pathogens including *Porphyromonas gingivalis*. We hypothesized that extracorporeal shock wave therapy (ESWT) could promote the regeneration of alveolar bone following *P. gingivalis*-induced gingival inflammatory reactions leading to periodontal disease in a rat model.

Methods: Rats were infected with *P. gingivalis* for 10 weeks, which caused measurable alveolar bone resorption. The infected rats were then treated with a single episode of 100, 300, or 1000 impulses of shock waves generated with a DermaGold® on both cheeks at energy levels 0.1 mJ/mm². Maxillary and mandibular alveolar bone levels were determined at 3, 6, and 12 weeks by radiography following ESWT and compared to untreated controls.

Results: PCR evaluation of the oral microbial samples demonstrated that 85-100% of the rats were infected with *P. gingivalis* during the experimental periodontal disease period. *P. gingivalis* infected rats treated with ESWT at 300 and 1000 impulses demonstrated significantly improved maxillary and mandibular alveolar bone levels at 3 weeks than those demonstrated by untreated controls, which remained for at least 6 weeks in most rats.

Discussion: ESWT has been shown to regulate/activate several genes (TGF- β 1, IGF-1, BMP- 2) linked to bone formation in rats. Thus, both resident cells and infiltrating inflammatory/immune cells in gingival and periodontal tissues might also reflect functional alterations from ESWT.

Conclusion: The results demonstrated effective regeneration of alveolar bone in *P. gingivalis* infected rats by ESWT and suggested that ESWT may be a useful adjunct in the regeneration of periodontal tissues following periodontal disease.

10th International Congress of the ISMST 2007 in Toronto, Canada, Abstract 35.

Study Performance: **dermagold100**

6. Dermatology

6.1. Acute Wounds and Burns

6.1.1. Effects of Extracorporeal Shock Waves on Microcirculation and Angiogenesis in the in vivo Wound Model of the Diver Box (Sorg et al., 2021)

Department of Plastic, Reconstructive and Aesthetic Surgery, Klinikum Westfalen, Dortmund, Germany.

Introduction: Extracorporeal shock waves (ESWs) have been shown to have a positive effect on skin wound healing; however, little is known on the regeneration of the microcirculation and angiogenesis as well as the different application modes.

Methods: A total of 40 BALB/c mice were provided with dorsal skin fold chambers and were divided into 3 therapy groups (n = 30) and one control group (n = 10). The 3 therapy groups were treated with shock waves at different pulse rates (500-1,000 pulses/min) and application frequencies (day 0 and day 6 or day 0 only). Photographic documentation and intravital microscopy were carried out on day 1, 2, 4, and 6 after wounding.

Results: Using the newly developed Diver Box, shock waves could be applied in vivo without mechanical tissue damage. Shock wave therapy to skin wounds demonstrated to induce faster wound closure rates in the beginning than controls in groups with higher pulse rates and frequencies of the shock waves. Furthermore, the regeneration of microcirculation and perfusion in the healing skin was significantly improved after the application of, in particular, higher pulse rates as given by increased numbers of perfused capillaries and functional vessel density. The study of inflammation showed, especially in high-pulse ESW groups, higher leukocyte counts, and rolling leukocytes over time until day 6 as a response to the induction of inflammatory reaction after ESW application. Angiogenesis showed a marked increase in positive areas as given by sprouts, coils, and recruitments in all ESW groups, especially between days 4 and 6.

Conclusion: The major findings of this trial demonstrate that ESW therapy to skin wounds is effective and safe. This is demonstrated by the initially faster wound closure rate, but later the same wound closure rate in the treatment groups than in controls. Furthermore, during the regeneration of microcirculation and perfusion in the healing skin, a significant improvement was observed after the application of, in particular, higher ESW pulse rates, suggesting an ESW-related increase in nutrient and oxygen supply in the wound tissue.

Study Performance: **dermagold100**

6.1.2. Mechanical Stimulation of Fibroblasts by Extracorporeal Shock Waves: Modulation of Cell Activation and Proliferation Through a Transient Proinflammatory Milieu (Basoli et al., 2020)

Department of Biomedical Sciences, University of Sassari, Sassari, Italy.

Abstract

Extracorporeal shock waves (ESWTs) are "mechanical" waves, widely used in regenerative medicine, including soft tissue wound repair. Although already being used in the clinical practice, the mechanism of action underlying their biological activities is still not fully understood. In the present paper we tried to elucidate whether a proinflammatory effect may contribute to the regenerative potential of shock waves treatment. For this purpose, we exposed human foreskin fibroblasts (HFF1 cells) to an ESWT treatment (100 pulses using energy flux densities of 0.19 mJ/mm² at 3 Hz), followed by cell analyses after 5 min, up to 48 h. We then evaluated cell proliferation, reactive oxygen species generation, ATP release, and cytokine production. Cells cultured in the presence of lipopolysaccharide (LPS), to induce inflammation, were used as a positive control, indicating that LPS-mediated induction of a proinflammatory pattern in HFF1 increased their proliferation. Here, we provide evidence that ESWTs affected fibroblast proliferation through the overexpression of selected cytokines involved in the establishment of a proinflammatory program, superimposable to what was observed in LPS-treated cells. The possibility that inflammatory circuits can be modulated by ESWT mechanotransduction may



disclose novel hypothesis on their biological underpinning and expand the fields of their biomedical application.

Study Performance: **orthogold100**

6.1.3. Extracorporeal Shockwave Therapy as Supplemental Therapy for Closure of Large Full Thickness Defects—Rat Full-Thickness Skin Graft Model (Antonic et al., 2018)

Walter Reed Army Institute of Research, Silver Spring, MD, United States.

Skin grafting is one of the most common treatment options for permanent replacement of lost skin. Successful healing and engraftment are destined by degree of ischemia, angiogenesis and inflammation in the graft tissue. Extracorporeal shockwave therapy (ESWT) has been shown to have beneficial effects in soft tissue wounds through increase in perfusion, angiogenesis and suppression of inflammation. The objective of this study was to evaluate effects of single and repeated ESWT on skin graft survival and healing.

Study Performance: **dermagold100**

6.1.4. In Vitro Effects of Extracorporeal Shockwave Therapy (ESWT) on Proliferation and Metabolic Activity of Adult Human Keratinocytes (Ottomann MD & Antonic PhD, 2015)

Walter Reed Army Institute of Research, Silver Spring, MD, United States.

Background: The objective of the presented study is to investigate in vitro effects of low energy extracorporeal shockwave therapy (ESWT) on the keratinocytes and their metabolic and proliferative properties for their therapeutic applications.

Materials: Primary culture of keratinocytes was isolated from clinical samples and after passaging into 12 flasks exposed to the various number of ESWT impulses (n=25, 50 and 100 impulses) in combination with several frequencies (1, 3 or 5 Hz) and distances from the applicator head (5, 6 or 7 cm with corresponding energy flux densities (EFD)=0.04, 0.025 and 0.015 mJ/mm², respectively) using modified water bath at constant temperature 37°C. Flasks were assigned to receive one combination of treatment parameters. The individually tested distances/EFD with the various impulse numbers and frequencies were summarized to experimental series. Cell viability was measured using trypan blue, cell cytotoxicity was measured using lactate dehydrogenase assay, and cell metabolic activity was measured by level of glucose metabolism.

Results: Our results indicate that low energy ESWT has both cytotoxic and stimulating effects on the keratinocytes. These effects depend on number of impulses, distance from the applicator head, and frequency. A proliferation stimulating effect and a higher viable cell count could be observed for a distance of 5 cm with 100 impulses at 1 Hz and EFD=0.04 mJ/mm².

Conclusion: Our results indicate that ESWT (EFD=0.04 mJ/mm², 100 impulses, 1 Hz at 5 cm) augmented proliferative capacity of keratinocytes in vitro. These promising results grant further investigation and have practical potential in keratinocyte research and production.

Study Performance: **orthowave180C**

6.1.5. Extracorporeal Shockwaves (ESW) Promote Proliferation and Differentiation of Keratinocytes In Vitro—Histology and Immunohistochemistry (Antonic V, Hartmann B, Münch S, Belfekroun C, Niedobitek G, 2015)

Wound Infection Department, Walter Reed Army Institute of Research, Silver Spring, MD, United States.

The objective of presented study was to evaluate in vitro effects of extracorporeal shockwave therapy (ESWT) on the keratinocyte morphology, cytoskeleton and mitotic activity. To determine in vitro effects of ESWT on keratinocytes, we applied 100 pulses with an energy flux density 0.1 mJ/mm² and a frequency of 1 Hz at a distance of 5 cm between therapy head and culture flask. The treatment parameters were determined in a pilot study. Haematoxylin and Eosin staining, as well as immunohistochemistry for Ki-67, CK5, CK14 and CK10 was performed on the cultured keratinocytes and results were compared between ESW treated group and Controls. No pathomorphological abnormalities or alterations in the cell's monolayer could be observed. When assessing histological images of all HE-stained sections of ESW-treated and untreated keratinocytes (control group), no morphological differences could be seen between or within the groups. The proliferation marker Ki-67 was found at a frequency of 14% for ESW-treated and 10% for untreated keratinocytes. There were also figures of 95% (CK5 staining) and 90% (CK14 staining) for ESW-treated, as well as 85% (CK5 staining) and 85% (CK14 staining) for untreated keratinocytes. CK10-positive cells showed a frequency of 24% in the ESW-treated and 33% in the untreated cell cultures. Immunohistochemical observations indicated an increased proliferation behavior following treatment with extracorporeal shockwaves in vitro and maturation of the exposed keratinocytes. Our results suggest an increase in proliferation activity of keratinocytes after in vitro treatment with ESWT. Further investigations of the effects of ESWT on the keratinocyte expression of the chemokines and cytokines are underway.

Study Performance: **orthowave180c**

6.1.6. Shock Wave Treatment Enhances Cell Proliferation and Improves Wound Healing by ATP Release-Coupled Extracellular Signal-Regulated Kinase (ERK) Activation (Weihs et al., 2014)

From the Department of Biochemical Engineering, University of Applied Sciences Technikum Wien, 1200 Vienna, Austria.

Shock wave treatment accelerates impaired wound healing in diverse clinical situations. However, the mechanisms underlying the beneficial effects of shock waves have not yet been fully revealed. Because cell proliferation is a major requirement in the wound healing cascade, we used in vitro studies and an in vivo wound healing model to study whether shock wave treatment influences proliferation by altering major extracellular factors and signaling pathways involved in cell proliferation. We identified extracellular ATP, released in an energy- and pulse number-dependent manner, as a trigger of the biological effects of shock wave treatment. Shock wave treatment induced ATP release, increased Erk1/2 and p38 MAPK activation, and enhanced proliferation in three different cell types (C3H10T1/2 murine mesenchymal progenitor cells, primary human adipose tissue-derived stem cells, and a human Jurkat T cell line) in vitro. Purinergic signaling-induced Erk1/2 activation was found to be essential for this proliferative effect, which was further confirmed by in vivo studies in a rat wound healing model where shock wave treatment induced proliferation and increased wound healing in an Erk1/2-dependent fashion. In summary, this report demonstrates that shock wave treatment triggers release of cellular ATP, which subsequently activates purinergic receptors and finally enhances proliferation in vitro and in vivo via downstream Erk1/2 signaling. In conclusion, our findings shed further light on the molecular mechanisms by which shock wave treatment exerts its beneficial effects. These findings could help to improve the clinical use of shock wave treatment for wound healing.

Study Performance: **dermagold100** with applicator OP155



6.1.7. *Extracellular ATP Enhances Proliferation After In Vitro Shockwave Treatment by ERK Dependent Pathways (Weihs et al., 2013)*

University of Applied Sciences Technikum Wien, Department of Biochemical Engineering, Vienna, Austria.

Introduction: Shockwave treatment, a mode of mechanical stress, accelerates wound healing *in vivo*. Yet the mechanisms underlying the beneficial effect of shockwave treatment still remain largely unknown. In this study, we investigated whether shockwave induced ATP release is essential for the proliferative effect of shockwave treatment and if the ERK1/2 signaling pathway is involved in this phenomenon.

Methods: In our *in vitro* model C3H10T1/2 mouse mesenchymal stem cells were subjected to shockwave treatment and ATP release was assessed. Cell cycle phase distribution after application of shockwaves was evaluated by propidium iodide staining followed by flow cytometry. Proliferating cells were also quantified using a BrdU incorporation assay. Western blot analysis was performed to assess the activation of ERK1/2. Apyrase and suramin were used to evaluate the roles of ATP release and P2 purinergic receptors in the effect of shockwave treatment on proliferation.

Results: Shockwave treatment released ATP in C3H10T1/2 cells dependent on applied energy and pulse number. Shockwave treatment significantly increased the amount of cells in S-phase in an energy dependent manner. Hydrolysis of released ATP with apyrase completely diminished the proliferative effect of shockwave treatment. Shockwaves induced significant pERK1/2 activation. Pretreatment of cells with the P2 receptor antagonist suramin as well as depletion of ATP prevented this activation.

Discussion: We conclude that *in vitro* shockwave treatment releases cellular ATP that activates downstream signaling such as ERK1/2 via purinergic receptors, ultimately causing the proliferative effects of shockwave treatment.

Conclusion: This signaling cascade could be one of the underlying principles of the beneficial effects of shockwave treatment in wound healing.

16th ISMST Congress Salzburg, Austria. Abstract No. P3.

Study Performance: **dermagold100**

6.1.8. *Effect of Unfocused Extracorporeal Shock Wave Therapy on Growth Factor Gene Expression in Wounds and Intact Skin of Horses (Link et al., 2013)*

Department of Clinical Studies, Ontario Veterinary College, University of Guelph, N1G 2W1 Guelph, ON, Canada.

Objective: To compare the effect of extracorporeal shock wave therapy (ESWT) on expression of fibroblast growth factor-7 (FGF-7), transforming growth factor- β 1 (TGF- β 1), insulin-like growth factor-1 (IGF-1), platelet-derived growth factor-A (PDGF), and vascular endothelial growth factor-A (VEGF) in skin with surgically created skin wounds and intact skin in horses.

Animals: 14 healthy horses.

Procedure: 8 horses were treated with ESWT at 6 locations along the neck at 36, 24, 12, 6, 2, or 1 hour prior to collection of full-thickness biopsy specimens from each location; a control specimen was collected from a sham-treated location. In 6 horses, 5 full-thickness wounds were created in each forelimb. Wounds in 1 forelimb/horse received ESWT immediately after creation and subsequently on days 7, 14, and 21; wounds in the contralateral forelimb remained untreated. Biopsy specimens were collected from 1 wound on each forelimb on days 7, 14, 21, 28, and 35. Expression levels of FGF-7, TGF- β 1, IGF-1, PDGF, and VEGF were assessed in tissue samples from the horses' necks and forelimbs.



Results: In surgically created wounds, ESWT treatment was associated with reduced TGF- β 1 expression, compared with expression in control wounds, during the entire study period. At 28 days following wound creation, IGF-1 expression was significantly increased for treated and untreated wounds, compared with findings on days 7, 14, 21, and 35. There was no significant effect of treatment on FGF-7, TGF- β 1, IGF-1, PDGF, or VEGF expression in intact skin.

Conclusions and clinical relevance: Intervention with ESWT to suppress TGF- β 1 may decrease granulation tissue production, resulting in improved wound healing on the distal portion of horses' limbs.

Study Performance: **dermagold180C**, CP155

6.1.9. Extracorporeal Shock Wave Therapy (ESWT) Minimizes Ischemic Tissue Necrosis Irrespective of Application Time and Promotes Tissue Revascularization by Stimulating Angiogenesis (Mittermayr et al., 2011)

Ludwig Boltzmann Institute for Experimental and Clinical Traumatology, Vienna, Austria.

Objective: To assess the time-dependent treatment effects of extracorporeal shock wave therapy (ESWT) in a standard rodent ischemic epigastric flap model.

Background: ESWT has been shown to accelerate tissue repair in acute and chronic wounds and improve graft survival, but the mechanism remains incompletely understood.

Methods: Shock waves at 0.1 mJ/mm and 5 impulses/s (total 300 impulses) were applied to the epigastric flap ischemic region at various times pre-, immediately and 24 hours postischemic insult. Flap survival; vascular perfusion; vessel number; von Willebrand factor and smooth muscle actin protein expression as well as in vivo vascular endothelial growth factor receptor 2 expression were evaluated at 1, 3, and 7 days postoperatively in ESWT-treated and untreated controls.

Results: Flap perfusion, microvessel number, and survival (through reduced flap contraction and necrosis) were significantly enhanced in the treated groups compared with controls, irrespective of timing of shock wave treatment (preischemia vs. postischemia). Vascular endothelial growth factor receptor 2 expression was dynamically upregulated in response to ESWT.

Conclusion: Shock wave preconditioning and treatment postischemic insult improves skin flap survival through neovascularization and early upregulation of angiogenesis-related growth factors.

Study Performance: **dermagold100**

6.1.10. Effects of Unfocused Extracorporeal Shock Wave Therapy on Healing of Wounds of the Distal Portion of the Forelimb in Horses (Silveira A, Koenig JB, Arroyo LG, Trout D, Moens NM, LaMarre J, 2010)

Department of Clinical Studies, Ontario Veterinary College, University of Guelph, Guelph, ON N1G 2W1, Canada.

Objective: To determine effects of extracorporeal shock wave therapy (ESWT) on healing of wounds in the distal portion of the forelimb in horses.

Animals: 6 horses.

Procedures: Five 6.25-cm² superficial wounds were created over both third metacarpi of 6 horses. Forelimbs were randomly assigned to treatment (ESWT and bandage) or control (bandage only) groups. In treated limbs, each wound was treated with 625 shock wave pulses from an unfocused electrohydraulic shock wave generator. In control limbs, each wound received sham treatment. Wound appearance was recorded weekly as inflamed or healthy and scored for the amount of



protruding granulation tissue. Standardized digital photographs were used to determine the area of neoepithelialization and absolute wound area. Biopsy was performed on 1 wound on each limb every week for 6 weeks to evaluate epithelialization, fibroplasia, neovascularization, and inflammation. Immunohistochemical staining for α smooth muscle actin was used to label myofibroblasts.

Results: Control wounds were 1.9 times as likely to appear inflamed, compared with treated wounds. Control wounds had significantly higher scores for exuberant granulation tissue. Treatment did not affect wound size or area of neoepithelialization. No significant difference was found for any of the histologic or immunohistochemical variables between groups.

Conclusions and clinical relevance: Treatment with ESWT did not accelerate healing of equine distal limb wounds, but treated wounds had less exuberant granulation tissue and appeared healthier than controls. Therefore, ESWT may be useful to prevent exuberant granulation tissue formation and chronic inflammation of such wounds, but further studies are necessary before recommending ESWT for clinical application.

Study Performance: **dermagold180c**

6.1.11. *Extracorporeal Shock Wave Therapy Suppresses the Early Proinflammatory Immune Response to a Severe Cutaneous Burn Injury* (Davis et al., 2009)

Combat Casualty Care, Department of Regenerative Medicine, Naval Medical Research Center, Silver Spring, MD 20910, USA.

Following severe burn injury, persistent inflammation perpetuated by surface eschar, bacterial colonisation and neutrophil proteolytic activity can impede normal healing and result in further tissue damage. Extracorporeal shock wave treatment (ESWT) has been shown in the clinical setting to promote the healing of burn and difficult-to-heal wounds; however, the mechanism is unclear. We investigated the role of ESWT on the early proinflammatory response using a severe, full-thickness and highly inflammatory cutaneous burn wound in a murine model. Various wound-healing parameters were measured and leukocyte infiltration quantitated. A panel of 188 candidate genes known to be involved in acute inflammation and wound healing was screened. We show that ESWT of burn wounds 1-hour postwounding significantly blunts polymorphonuclear neutrophil and macrophage infiltration into the wound. ESWT treatment potentially attenuates both CC- and CXC-chemokine expression, acute proinflammatory cytokine expression and extracellular matrix proteolytic activity at the wound margin. Given these findings and the clinical success of ESWT, we speculate that ESWT may be a potential therapeutic modality to treat severe wounds wherein excessive inflammatory responses involving increased levels of inflammatory cells, proinflammatory cytokines and proteases may become self-resolving allowing wound healing to progress by way of normal physiological repair processes.

Study Performance: **dermagold100**

6.1.12. *Angiogenic Response to Extracorporeal Shock Wave Treatment in Murine Skin Isografts* (Stojadinovic et al., 2008)

Combat Wound Initiative Program, Department of Surgery, Walter Reed Army Medical Center, Washington, DC, USA.

Skin grafts are commonly utilized and proven effective methods of open wound coverage. Revascularization through neoangiogenesis is a pivotal mechanism for skin graft integration and durability. Extracorporeal shock-wave treatment (ESWT) has been demonstrated to accelerate wound

repair; however, its mechanism-of-action is unclear. We investigated the role of ESWT in early revascularization of full-thickness skin isografts in a murine model. Cohorts of mice were euthanized and skin grafts were harvested 6 h, 2, 4, and 7 days post grafting +/- ESWT. Various aspects of graft neovascularization were measured including gross morphology, quantitative microscopy (vessel number, density), immunohistochemistry (CD31), cDNA SuperArrays for 84 angiogenesis-specific genes, and custom-designed 'Wound Repair' TaqMan Low Density Array (TLDA) cards to assess expression of 188 wound repair genes. We demonstrate that a single administration of ESWT immediately following skin grafting significantly enhances recipient graft revascularization (increased vessel number, size, and density). An augmented early pro-angiogenic and suppressed delayed pro-inflammatory response to ESWT was accompanied by significantly increased expression of both skin graft CD31 and angiogenesis pathway-specific genes, including ELR-CXC chemokines (CXCL1, CXCL2, CXCL5), CC chemokines (CCL2, CCL3, CCL4), cytokines (IL-1 beta, IL-6, G-CSF, VEGF-A), matrix metalloproteinases (MMP3, MMP9, MMP13), hypoxia-inducible factors (HIF-1 alpha), and vascular remodeling kinase (Mst1), as early as 6 h and up to 7 days post grafting and treatment. These findings suggest that early pro-angiogenic and anti-inflammatory effects of ESWT promote tissue revascularization and wound healing by augmenting angiogenesis and dampening inflammation.

Study Performance: **dermagold180c**

6.1.13. *A Study of the Biological Factors and Wound Healing of a Skin Flap Model (Vasconez et al., 2007)*

University of Kentucky Chandler Medical Center Division of Plastic and Reconstructive Surgery.

Introduction: This animal study was performed to assess the effectiveness of extracorporeal shock wave (ESWT) treatment to promote cell differentiation with neovascularization, thus minimizing the measurable area of necrosis and enhancing epigastric skin flap survival. In addition, we measured the expression level of the mRNAs of the growth factors known to play a major role during normal wound healing angiogenesis using Real-Time PCR. In particular, we studied the expression of basic fibroblast growth factor (bFGF), transforming growth factor beta, (TGF- β), platelet derived growth factor (PDGF), epidermal growth factor (EGF) and vascular endothelial cell growth factor (VEGF) at several time points following the skin flap surgery. We studied the localized changes in expression as well as systemic changes that were initiated by the treatment with ESWT.

Methods: Experimental Design: This study was approved by our Institutional Animal Care and Use Committee. This study was conducted in two phases. Sprague-Dawley rats with a weight range of 400-500g were used for both phases. Phase I The rats were randomized into two groups of eight: a control group and an ESWT group. Immediately following surgery, while the animals were anesthetized, the flap area was treated with Level 1 (500 pulses at 0.15 mJ/mm²) in the ESWT group. The control group underwent the same surgery but did not receive ESWT. On Day 7 post-op, the animals were euthanatized and clinical measurements of healing were collected post-mortem. The control group underwent the same surgery but did not receive ESWT. Phase II The rats were randomized into two groups of eight: a control group and an ESWT group. Immediately following surgery, while the animals were still anesthetized, the flap area was treated with Level 1 (500 pulses at 0.15 mJ/mm²) in the ESWT group. Two rats from each group were euthanatized at 12 hours, 24 hours, 48 hours and 72 hours. The necrotic area plus 2-3 mm of adjacent healthy tissue was obtained postmortem and stored in liquid nitrogen for growth factor and stem cell marker analysis.

Results: When the area of necrosis was analyzed using the PictZar imaging software, we found that the area of skin flap necrosis for the control group (n=8) was an average of 11.7 cm². In the treatment group (n=8) necrosis of the same flaps were an average of 3.8 cm². Statistical analysis using the Mann



Whitney t-test showed significance at $P=0.0006$. The expression of EGF, PDGF and VEGFG was detectable at 12, 24, 48 and 72 hours in the control and shockwave treated animal on both, the treated and the untreated side of the flap. This was true when the expression was compared to actin as well as compared to GAPDH.

Discussion: The results of our animal study showed that the treatment of skin flaps with unfocused ESWT had a significant beneficial effect on survival and viability of the skin flaps. Additionally, this effect appears similar with unfocused as compared to focused shockwaves. The area of necrosis on the skin flap was significantly smaller in the treated group compared to the untreated group without apparent side effects. ($p=0.0006$) The second phase of the study demonstrated local and systemic effects of various growth factors, which could prove to be of invaluable help in wound healing. Some of the groups who experimented with injection of growth factor or with gene therapy using growth factors remarked that, because growth factors expression is orchestrated in a specific way, it would be necessary to inject several factors over a specific time frame in order to mimic what is naturally happening in the body.

Conclusion: The range of applications of shockwave therapy is as yet undefined and is an area of active interest and research. Further work in the field of wound healing may result in establishing a painless, noninvasive, modality of therapy for wounds that have been up to now recalcitrant to other forms of established treatment.

10th International Congress of the ISMST 2007 in Toronto, Canada, Abstract 45.

Study Performance: **vetwave140**

6.2. Chronic Wounds and Ulcers

6.2.1. Compare the Effectiveness of Extracorporeal Shockwave and Hyperbaric Oxygen Therapy on Enhancing Wound Healing in a Streptozotocin-Induced Diabetic Rodent Model (R. Chen et al., 2023)

Division of Plastic and Reconstructive Surgery, Department of Surgery, Kaohsiung Medical University Hospital, Kaohsiung, Taiwan.

Studies have revealed that both extracorporeal shock-wave therapy (ESWT) and hyperbaric oxygen therapy (HBOT) can accelerate wound healing. This study aimed to compare the effectiveness of ESWT and HBOT in enhancing diabetic wound healing. A dorsal skin defect in a streptozotocin-induced diabetes rodent model was used. Postoperative wound healing was assessed once every 3 days. Histologic examination was performed with hematoxylin and eosin staining. Proliferation marker protein Ki-67 (Ki-67), endothelial nitric oxide synthase (eNOS), vascular endothelial growth factor (VEGF), and 8-hydroxy-2-deoxyguanosine (8-OHdG) were evaluated with immunohistochemical (IHC) staining. The wound area was significantly reduced in the ESWT and HBOT groups compared to that in the diabetic controls. However, the wound healing time was significantly increased in the HBOT group compared to the ESWT group. Histological findings showed a statistical increase in neovascularization and suppression of the inflammatory response by both HBOT and ESWT compared to the controls. IHC staining revealed a significant increase in Ki-67, VEGF, and eNOS but suppressed 8-OHdG expression in the ESWT group compared to the HBOT group. ESWT facilitated diabetic wound healing more effectively than HBOT by suppressing the inflammatory response and enhancing cellular proliferation and neovascularization and tissue regeneration.

Study Performance: dermagold100, OP155.

6.2.2. *The Potential Effect of Shock Wave Treatment on Cellular Senescence (D. Swarc-Hofbauer et al., 2022)*

*University of Applied Sciences Technikum Wien, Department Life Science Engineering, Vienna, Austria
Austrian Cluster for Tissue Regeneration, Vienna, Vienna, Austria.*

Introduction

Cellular senescence describes the process that drives cells into a controlled and irreversible cell cycle arrest and is initiated by diverse stress-triggering stimuli. Though halted in their cellular growth, senescent cells maintain high metabolic activity and control various physiological functions, such as counteracting tumor formation. Senescence can induce highly opposing effects, depending on whether it occurs in its transient or chronic form. Transiently active senescence is essential in development, regeneration and acute wound repair. On the contrary, cells that accumulate during chronological aging contribute to chronic senescence, leading to numerous tissue pathologies such as diabetic foot ulcers. Shock waves have been reported to be an effective treatment option for this type of pathologies – including impaired wound healing and excessive scar tissue formation. However, the role of cellular senescence in shock wave-induced effects in wound healing has not been investigated yet. Therefore, the current study aims to explore the potential effects of shock wave treatment on cellular senescence and their link to shock wave induced wound healing.

Material & Method

Human primary dermal BJ fibroblasts cultured under standard cell culture conditions were driven into either stress-induced premature senescence (SIPS) by doxorubicin treatment of cells with less than 40 population doublings or replicative senescence (achieved by their long-term subcultivation). Cells were treated in a standardized *in vitro* set-up using the electrohydraulic dermagold100 shock wave device (MTS Medical, Konstanz, Germany).

Treatment was performed at different stages of SIPS as well as on cells that were continuously subcultivated (towards replicative senescence). Onset, progression or changes in cellular senescence were analyzed by monitoring senescence markers such as SA- β -gal activity, γ -H2A.X foci formation or expression of tumor suppressor p53, and cyclin dependent kinase inhibitors p21 and p16 using immunofluorescent/immunohistochemical staining, quantitative real time PCR and Western blot techniques.

Results

Our preliminary data indicate a senescence-regulating effect of shock wave treatment, depending on the parameters of treatment (number of pulses, energy), type of senescence (SIPS or replicative senescence) and timepoint of shock wave application (before, during or after the induction of senescence).

Discussion

The underlying mechanisms to the beneficial effects of shock wave treatment have been investigated thoroughly in the last years. Adding to already identified signaling pathways, the findings of this study will for the first time address the potential role of shock waves as a modulator of cellular senescence that might play a vital part in wound healing effects of shock wave treatment.

24rd World Congress of the ISMST 2022 in Prague, Czech Republic, oral presentation ISMST22-0052.

Study Performance: dermagold100



6.2.3. Shockwaves Increase In Vitro Resilience of Rhizopus Oryzae Biofilm Under Amphotericin B Treatment (Slezak, Anderson, et al., 2022)

Department of Physics, Utah Valley University, Orem, UT 84058, USA

Ludwig Boltzmann Institute for Traumatology, The Research Center in Cooperation with the AUVA, 1200 Vienna, Austria

Austrian Cluster for Tissue Regeneration, 1200 Vienna, Austria.

Abstract: Acoustical biophysical therapies, including ultrasound, radial pressure waves, and shockwaves, have been shown to harbor both a destructive and regenerative potential depending on physical treatment parameters. Despite the clinical relevance of fungal biofilms, little work exists comparing the efficacy of these modalities on the destruction of fungal biofilms. This study evaluates the impact of acoustical low-frequency ultrasound, radial pressure waves, and shockwaves on the viability and proliferation of in vitro *Rhizopus oryzae* biofilm under Amphotericin B induced apoptosis. In addition, the impact of a fibrin substrate in comparison with a traditional polystyrene well-plate one is explored. We found consistent, mechanically promoted increased Amphotericin B efficacy when treating the biofilm in conjunction with low frequency ultrasound and radial pressure waves. In contrast, shockwave induced effects of mechanotransduction results in a stronger resilience of the biofilm, which was evident by a marked increase in cellular viability, and was not observed in the other types of acoustical pressure waves. Our findings suggest that fungal biofilms not only provide another model for mechanistical investigations of the regenerative properties of shockwave therapies, but warrant future investigations into the clinical viability of the therapy.

Study Performance: **dermagold100**

6.2.4. The Acceleration of Diabetic Wound Healing by Low-Intensity Extracorporeal Shockwave Involves in the GSK-3 β Pathway (R.-F. Chen et al., 2020)

Division of Plastic Surgery, Department of Surgery, Kaohsiung Medical University Hospital, Kaohsiung 807, Taiwan.

Previous studies have demonstrated that extracorporeal shock wave therapy (ESWT) could accelerate diabetic wound healing and that the inhibition of glycogen synthase kinase-3 β (GSK-3 β) is involved in epithelial differentiation during wound healing. This study investigated whether the enhancement of diabetic wound healing by ESWT is associated with the GSK-3 β -mediated Wnt/ β -catenin signaling pathway. A dorsal skin wounding defect model using streptozotocin-induced diabetic rodents was established. Rats were divided into 4 groups: group 1, normal controls without diabetes; group 2, diabetic controls without treatment; group 3, diabetic rats receiving ESWT; and group 4, rats receiving 6-bromoindirubin-3'-oxime (BIO), a GSK-3 β inhibitor, to trigger Wnt/ β -catenin signaling. Tissue samples were collected and analyzed by immunohistochemical (IHC) staining and quantitative RT-PCR. The ESWT and BIO-treated groups both exhibited significant promotion of wound healing compared to the healing in controls without treatment. RT-PCR analysis of Wnt-1, -3a, -4, -5a, and -10 and β -catenin expression showed significantly increased expression in the ESWT group. The IHC staining showed that Wnt-3a and -5a and β -catenin levels were significantly increased in the ESWT and BIO treatment groups compared to the control groups. ESWT enhancement of diabetic wound healing is associated with modulation of the GSK-3 β -mediated Wnt/ β -catenin signaling pathway.

Study Performance: **orthowave180c**, with applicator CP155

6.2.5. Proteomic Analysis of Peri-Wounding Tissue Expressions in Extracorporeal Shock Wave Enhanced Diabetic Wound Healing in a Streptozotocin-Induced Diabetes Model (R. F. Chen et al., 2020)

Department of Surgery, Division of Plastic Surgery, Kaohsiung Medical University Hospital, Kaohsiung, Taiwan.

Our former studies have demonstrated that extracorporeal shock wave therapy (ESWT) could enhance diabetic wound healing but the bio-mechanisms remain elusive. This study investigated the changes of topical peri-wounding tissue expressions after ESWT in a rodent streptozotocin-induced diabetic wounding model by using the proteomic analysis and elucidated the molecular mechanism. Diabetic rats receiving ESWT, normal control, and diabetic rats receiving no therapy were analyzed. The spots of interest in proteome analysis were subjected to mass spectrometry to elucidate the peptide mass fingerprints. Protein expression was validated using immunohistochemical staining and related expression of genes were analyzed using real-time RT-PCR. The proteomic data showed a significantly higher abundance of hemopexin at day 3 of therapy but down-regulation at day 10 as compared to diabetic control. In contrast, the level of serine proteinase inhibitor (serpin) A3N expression was significantly decreased at day 3 therapy but expression was upregulated at day 10. Using real-time RT-PCR revealed that serpin-related EGFR-MAPK pathway was involved in ESWT enhanced diabetic wound healing. In summary, proteome analyses demonstrated the expression change of hemopexin and serpin with related MAPK signaling involved in ESWT-enhanced diabetic wound healing. Modulation of hemopexin and serpin related pathways are good strategies to promote wound healing.

Study Performance: **orthowave180c**, with applicator CP155

6.2.6. Modulation of VEGF and MAPK-Related Pathway Involved in Extracorporeal Shockwave Therapy Accelerate Diabetic Wound Healing: Modulation of VEGF Pathway Involved in ESWT Accelerate Wound Healing (R. F. Chen et al., 2019)

Department of Surgery, Division of Plastic Surgery, Kaohsiung Medical University Hospital, Kaohsiung, Taiwan.

Extracorporeal shockwave therapy (ESWT) has a significant positive effect to accelerate chronic wound healing. This study investigated whether the vascular endothelial growth factor (VEGF)-related pathway has involved in ESWT enhancement of diabetic wound healing. A dorsal skin defect (area, 6 × 5 cm) in a streptozotocin-induced diabetes rodent model was used. Thirty-two male Wistar rats were divided into four groups. Group I consisted of nondiabetic control; group II, diabetic control without treatment; group III, diabetic rats received ESWT; and group IV, rats received Avastin (a VEGF monoclonal antibody) on day 0 (post-wounding immediately) to day 7 and ESWT on day 3 and day 7. The wound healing was assessed clinically. The VEGF, endothelial nitric oxide synthase (eNOS), and Ki-67 were analyzed with immunohistochemical staining. The mRNA expression of mitogen-activated protein kinase-related genes was measured by real-time quantitative real-time polymerase chain reaction. The results revealed wound size was significantly reduced in the ESWT-treated rats as compared to the diabetic control ($p < 0.01$). The positive effect of ESWT-increasing wound healing was significantly suppressed in pretreatment of the Avastin group. Histological findings revealed significant increase in neo-vessels in the ESWT group as compared to the control. In immunohistochemical stain, significant increases in VEGF, eNOS, and Ki-67 expressions were noted in the ESWT group as compared to that in controls. However, Avastin suppressed the shockwave effect and down-regulation of VEGF, eNOS, and Ki-67 expressions in the Avastin-ESWT group as compared to that in the ESWT alone group. We found that highly mRNA expression of Kras, Raf1, Mek1, Jnkk, Jnk, and Jun at early stage in the



ESWT group, as compared to the diabetic control. These evidences indicated treatment with multiple sessions of ESWT significantly enhanced diabetic wound healing associated with increased neovascularization and tissue regeneration. The bio-mechanism of ESWT-enhanced wound healing is correlated with VEGF and mitogen-activated protein kinase-mediated pathway.

Study Performance: **orthowave180c**, with applicator CP155

6.2.7. Serum Proteomic Analysis of Extracorporeal Shock Wave Therapy-Enhanced Diabetic Wound Healing in a Streptozotocin-Induced Diabetes Model (Yang et al., 2014)

Graduate Institute of Clinical Medical Sciences, College of Medicine, Chang Gung University; and the Department of Plastic and Reconstructive Surgery, Medical Research, and the Department of Orthopedics, Kaohsiung Chang Gung Memorial Hospital and Chang Gung University College of Medicine.

Background: Previous studies have demonstrated that extracorporeal shock wave therapy has a significant positive effect on accelerating diabetic wound healing. However, the systemic effect after therapy is still unclear.

Methods: This study investigated the plasma protein expression in the extracorporeal shock wave therapy group and diabetic controls using proteomic study. A dorsal skin defect (6 × 5 cm) in a streptozotocin-induced diabetic Wistar rat model was used. Diabetic rats receiving either no therapy or extracorporeal shock wave therapy after wounding were analyzed. The spots of interest were subjected to in-gel trypsin digestion and matrix-assisted laser desorption ionization time-of-flight mass spectrometry to elucidate the peptide mass fingerprints. The mass spectrometric characteristics of the identified proteins, including their theoretical isoelectric points, molecular weights, sequence coverage, and Mascot score, were analyzed. Protein expression was validated using immunohistochemical analysis of topical periwounding tissues.

Results: The proteomic study revealed that at days 3 and 10 after therapy rats had significantly higher abundance of haptoglobin and significantly lower levels of the vitamin D-binding protein precursor as compared with the diabetic controls. Immunohistochemical staining of topical periwounding tissue also revealed significant upregulation of haptoglobin and downregulation of vitamin D-binding protein expression in the extracorporeal shock wave therapy group, which was consistent with the systemic proteome study.

Conclusion: Proteome analyses demonstrated an upregulation of haptoglobin and a downregulation of vitamin D-binding protein in extracorporeal shock wave therapy-enhanced diabetic wound healing.

Study Performance: **dermagold180c**

6.2.8. Comparative Analysis of Angiogenic Gene Expression in Normal and Impaired Wound Healing in Diabetic Mice: Effects of Extracorporeal Shock Wave Therapy (Zins et al., 2010)

Regenerative Medicine Department, Operational and Undersea Medicine Directorate, Naval Medical Research Center, Room 2W06, 503 Robert Grant Avenue, Silver Spring, MD 20910, USA.

Impaired wound healing is a persistent clinical problem which has been treated with mixed results. Studies aimed at elucidating the mechanism of impaired wound healing have focused on small cohorts of genes which leave an incomplete picture of the wound healing process. We aimed to investigate impaired wound healing via a comprehensive panel of angiogenic/inflammation-related genes and wound closure kinetics with and without the application of extracorporeal shock wave therapy (ESWT), which has been demonstrated to improve wound healing. Full-thickness skin from the dorsal surface

of "normal" (BALB/c) and "impaired" (db (+)/db (+)) mice was excised, and wound margin tissue was harvested 2, 7, and 10 days post injury. A separate, but identical wound model was established over 40 days in order to measure wound closure kinetics. Over time, the normal non-ESWT treated wounds exhibited varying patterns of elevated expression of 25-30 genes, whereas wounds with impaired healing displayed prolonged elevated expression of only a few genes (CXCL2, CXCL5, CSF3, MMP9, TGF- α). In response to ESWT, gene expression was augmented in both types of wounds, especially in the expression of PECAM-1; however, ESWT had no effect on wound closure in either model. In addition, multiple doses of ESWT exacerbated the delayed wound healing, and actually caused the wounds to initially increase in size. These data provide a more complete picture of impaired wound healing, and a way to evaluate various promising treatments.

Study Performance: **dermagold180c**

6.2.9. Extracorporeal Shock-Wave Therapy Enhanced Wound Healing via Increasing Topical Blood Perfusion and Tissue Regeneration in a Rat Model of STZ-Induced Diabetes (Kuo et al., 2009)

Department of Plastic and Reconstructive Surgery, Chang Gung Memorial Hospital, Kaohsiung Medical Center, Chang Gung University College of Medicine, Niao-Sung Hsiang, Kaohsiung 83305, Taiwan.

Extracorporeal shock-wave therapy (ESWT) has a significant positive effect in accelerating chronic wound healing. However, the bio-mechanisms operating during ESWT of wounds remain unclear. This study investigated the effectiveness of ESWT in the enhancement of diabetic wound healing. A dorsal skin defect (area, 6 x 5 cm) in a streptozotocin-induced diabetes rodent model was used. Fifty male Wistar rats were divided into five groups. Group I consisted of nondiabetic control; group II included diabetic control receiving no ESWT; group III included rats that underwent one session of ESWT (ESW-1) on day 3 (800 impulses at 0.09 mJ/mm²) postwounding; group IV included rats that underwent two sessions of ESWT (ESW-2) on days 3 and 7; and group V included rats that underwent three sessions of ESWT (ESW-3) on days 3, 7, and 10. The wound healing was assessed clinically. Blood perfusion scan was performed with laser Doppler. The VEGF, eNOS, and PCNA were analyzed with immunohistochemical stain. The results revealed that the wound size was significantly reduced in the ESWT-treated rats, especially in the ESW-2 and ESW-3 groups, as compared with the control ($p < 0.01$). Blood perfusion was significantly increased after ESWT compared with the controls. Histological findings revealed a significant reduction in the topical pro-inflammatory reaction in the ESWT group as compared with the control. In immunohistochemical stain, significant increases in VEGF, eNOS, and PCNA expressions were observed in the ESWT group, especially in the ESW-2 and ESW-3 groups, as compared with the control. In conclusion, treatment with an optimal session of ESWT significantly enhanced diabetic wound healing associated with increased neo-angiogenesis and tissue regeneration, and topical anti-inflammatory response.

Study Performance: **dermagold100** with applicator OP155

6.2.10. How Many Shock Waves are Enough? Dose-Response Relationship in Ischemic Challenged Tissue (Mittermayr et al., 2008)

Ludwig-Boltzmann-Institute for experimental and clinical Traumatology, Austrian Cluster for Tissue Regeneration. Trauma Center Meidling, AUVVA, Vienna, Austria.

Introduction: Recently, we showed beneficial effects of extracorporeal shock wave therapy (ESWT) on ischemic challenged tissue. We were able to show that ESWT improved flap outcome irrespective of



application time (elective treatment 24h preoperatively, 1h postoperatively or treating manifest ischemic tissue 24h postoperatively). In the current study we investigated flap outcome in response to various total amounts of impulses.

Methods: In the ischemic area of a rodent epigastric flap, different amounts of total shock wave impulses were applied (30, 300, and 1,000) which corresponds to 1.4, 14, and 47 pulses/cm², respectively. Parameter of effectiveness included planimetry (necrosis, shrinkage), flap perfusion (assessed by 2-D laser Doppler imaging), and immunohistochemistry over a 7-day follow-up period.

Results: All shock wave treated groups showed substantial reduced tissue necrosis compared to control. Looking at the total amount of pulses within treatment groups, animals receiving 300 impulses showed the best results (less necrosis). Neither lower nor higher amounts (30 and 1,000, respectively) further improved flap outcome. No significant differences were found in the perfusion and immunohistochemical parameters.

Conclusion: ESWT in soft tissue complications such as ischemia has clear beneficial effects. A dose response relationship was found in reducing tissue necrosis.

11th ISMST Congress in Juan le Pins, France Abstract No. 64.

Study Performance: **dermagold180c**

6.2.11. Shockwave Therapy is Protective Against Ischemia Induced Tissue Necrosis Irrespective of Application Time (Mittermayr et al., 2007)

Ludwig-Boltzmann-Institute for experimental and clinical Traumatology – Research Center of the AUVA, Vienna, Austria Austrian Cluster for Tissue Regeneration, Vienna, Austria. Trauma Hospital Meidling, Vienna, Austria.

Introduction: Tissue necrosis following hypoxic/ischemic events is critical in many surgical disciplines. Recently, interest in shockwave therapy has grown in many clinical and experimental fields. However, primarily only positive empirical clinical data exist with rare data on underlying mechanisms. The aim of this study was to evaluate if shockwave application is effective either as an elective, post-surgical or follow-up therapy alternative in reducing/avoiding tissue necrosis following ischemic insult.

Methods: In the ischemic area of a rodent epigastric flap, 300 shockwave impulses (electromagnetic generation; 0.1mJ/mm²) were applied to different time points (24h pre-OP, post-OP, 24h post-OP). The parameters of effectiveness included planimetry (necrosis, shrinkage) and flap perfusion (assessed by 2-D laser Doppler imaging) over a 7-day follow-up period.

Results: In comparison to the control group (no treatment) all shockwave treated groups showed substantially reduced tissue necrosis regardless of whether the shockwaves were applied prior, post or 24 hours post induction of ischemia. There was no difference within the shockwave groups. Flap perfusion was also enhanced in comparison to the control group, dependent on what time the shockwaves were applied. Perfusion values increased from the time the flaps were treated with shockwaves and were comparable within the shockwave groups on the 7th postoperative day.

Discussion: Shockwave therapy on ischemia-challenged flaps shows clear protective effect in reducing tissue necrosis. This was independent of the time at which the shockwaves were applied. In addition, flap perfusion was enhanced after shockwave treatment.

Conclusion: Reduction of tissue necrosis with consecutive increased perfusion due to the upregulation of angiogenesis related receptors (e.g. VEGF-R2) as well as the alteration of the nitric oxide homeostasis might be of pivotal importance.

10th International Congress of the ISMST 2007 in Toronto, Canada, Abstract 46.

Study Performance: **DermaGold**

6.3. Pathologic Scarring

6.3.1. A Development of Biological Reparative Model in Human Tendon Derived from Fibroblasts Healing Process with unfocused ESWT (Saggini et al., 2014)

"G. d'Annunzio" University, Chieti, Italy.

Introduction: Alterations of tendon collagen due to overload are represented by degeneration, disorganization and thickening of collagen fibers, increase in collagen degradation and interfibrillar glycosaminoglycans, alteration in the normal ratio between type I and type III collagen. A similar process happens in pathological skin scarring, so recently we investigated biological and histopathological modifications of human skin in pathological scars after ESWT.

Methods: We compared 2 groups of subjects with retracting scars; the first group was treated with ESWT, the second did not receive the treatment (control group). 4 mm punch-biopsy of human skin samples were taken from all patients. We made histopathological and immunohistochemical analysis to get a quantitative evaluation of fibroblasts, angiogenesis and collagen concentrations in human skin samples.

Results: Results in the ESWT group showed: a significant increase of fibroblasts infiltration and increase in angiogenesis at the immunohistochemical analysis with Factor XIII marker; a significant increase in type I collagen concentration and an increase in angiogenesis in CD34 stained samples; an improvement in angiogenesis in CD31 stained samples. The collagen fibers were placed parallel to the skin surface and type III collagen was replaced by type I collagen. Dermal collagen appeared finer and more fibrillar if compared to pretreatment. No increase in fibroblasts infiltration and angiogenesis and no change in collagen composition was found in the control group.

Discussion: We can assume that the biological response to ESWT is the same in the different tissues and shock waves are able to get deep up to tendon thanks to the possibility of modulating the depth of treatment through parameters of focal pressure and intensity.

Conclusion: Compatibly with what observed in the human skin, where the tissue regeneration process is characterized by fibroblasts infiltration and collagen remodeling, with the replacement of type III with type I collagen, and considering the scientific evidence of the clinical effectiveness of ESWT on tendon diseases, we can assume a similar model of tissue repair in vivo also in human tendon.

17th ISMST Congress in Milano, Italy. Abstract No. 4.

Study Performance: **dermaGold100**

7. Urology

7.1. Peyronie's Disease

7.1.1. Low-intensity Extracorporeal Shockwave Therapy as an Adjunct to Xiaflex® in the Treatment of Peyronie's Disease (Soubra et al., 2022)

Tulane University School of Medicine, New Orleans, Louisiana, USA.

Introduction



Low-intensity extracorporeal shockwave therapy (Li-ESWT) may have physiologic effects including neo-angiogenesis, upregulation of vasoactive endothelial growth factors, nerve recovery, reduction of fibrotic changes, cavernosal tissue remodeling, and reduction in sympathetic tone. Collagenase clostridium histolyticum (CCH) is the only US FDA-approved drug for the non-surgical treatment of Peyronie's disease (PD). Treatment is intended to be completed in conjunction with penile traction therapy, but studies have demonstrated poor patient compliance. New adjunct therapies that have synergistic effects when used in combination with CCH are desirable but have not been explored.

Objective

To study if Li-ESWT has additive, synergistic, or no effect when used in combination with CCH to treat PD-associated fibrosis and PD-associated erectile dysfunction.

Methods

40 adult male Sprague-Dawley rats were divided evenly into five groups: sham (S), control (T), CCH only (XT), low setting Li-ESWT and CCH (XTL), and CCH and high setting Li-ESWT (XTH). Normal saline was injected sub-tunical in the sham group. Transforming growth factor beta-1 (TGF-B1) was injected into the tunica albuginea of the remaining groups to induce Peyronies-like fibrosis. After 4 weeks of TGF-B1 induction, CCH was injected in all three groups over two injections separated by 48 hours, and then treatment with Li-ESWT (UroGold™ 100) was initiated. Treatment was delivered biweekly for 3 weeks (6 total sessions). Device settings were 600 shocks at 3 Hz, at level 6 (0.093 mJ/mm²) for the XTL group and at level 12 (0.125 mJ/mm²) for the XTH group. After 10 weeks, erectile function was measured by ratio of intracavernosal pressure (ICP) to mean arterial pressure (MAP). Histological analysis by H&E, Trichome stain, and Western blot analysis of Collagen I (COL1A1), III (COL3A1), and alpha-smooth muscle actin (a-SMA) were also performed.

Results

There was no significant difference found in erectile function as measured by ICP/MAP between PD model and treatment groups ($P > 0.05$). Histological comparison showed no significant reduction of fibrosis when Li-ESWT was added to CCH, despite intensity, on microscopic examination. On Western blot analysis, there was a reduction of ~500% in COL1A1 expression when the XT group was compared to the T group. While there was no significant change of COL1A1 between the XT group and the XTL group, there was found to be a decrease of ~500% expression when the XT group was compared to the XTH group. Expression of COL3A1 in the treatment groups XTL and XTH was comparable to that of the XT group. There was no observable trend in a-SMA expression.

Conclusions

Different adjunct treatments to CCH need to be explored to augment the effect of the only approved non-surgical treatment for PD. Decreased COL1A1 expression seen in the XTH group, but not XTL, relative to the T group may suggest an energy-dependent effect to decrease fibrosis. Li-ESWT was hypothesized to be a promising candidate, but we have failed to show substantial benefit in our proposed setting.

2ndnd Annual Fall Scientific Meeting of SMSNA. Abstract No. 53.

Study Performance: **urogold100**

7.1.2. Evaluating Different Low-intensity Extracorporeal Shockwave Therapy Intensities in the Treatment of Peyronie's Disease in a Rat Model (Kim et al., 2022)

Tulane University School of Medicine, New Orleans, Louisiana, USA.

Introduction

Low-intensity extracorporeal shockwave therapy (Li-ESWT) is postulated to have physiologic effects including neo-angiogenesis, upregulation of vasoactive endothelial growth factors, nerve recovery, reduction of fibrotic changes, cavernosal tissue remodeling, and reduction in sympathetic tone. To date, randomized clinical trials have failed to demonstrate a change in penile curvature, with mixed results on erectile function, in Peyronie's disease (PD) patients.

Objective

To evaluate the treatment effect of Li-ESWT for amelioration of PD-associated fibrosis and PD-associated erectile dysfunction using a rat model of PD.

Methods

32 adult male Sprague-Dawley rats were divided evenly into four groups: sham (S), control (T), low setting Li-ESWT (TL), and high setting Li-ESWT (TH). Normal saline was injected into the tunica albuginea (TA) of the sham group. Transforming growth factor beta-1 (TGF-B1) was injected into the TA of the remaining groups to induce Peyronies-like fibrosis. After 5 weeks of TGF-B1 induction, treatment with Li-ESWT shockwave (UroGold 100™) was initiated. Treatment was delivered biweekly for 3 weeks (6 total sessions). Device settings were 600 shocks at 3 Hz, at level 6 (0.093 mJ/mm²) for the Low group and at level 12 (0.125 mJ/mm²) for the High group. Two weeks after the end of treatment, erectile function was measured by ratio of intracavernosal pressure (ICP) to mean arterial pressure (MAP). Histological analysis by H&E and Trichrome staining was performed. Western blot analysis of Collagens I (COL1A1), III (COL3A1), elastin, alpha-smooth muscle actin (α-SMA), and TGF-B1 was performed.

Results

There was no significant difference demonstrated in erectile function between T control group and TL and TH groups ($P > 0.05$). However, there seems to be a trend in decreased amount of fibrosis upon examination of the prepared histologic sections. Animals in the TL and TH groups had decreased COL1A1, COL3A1, elastin, and TGF-B1 expression in the TA compared to the T group. α-SMA expression in the treatment groups was found to be increased compared to both S and T groups.

Conclusions

Our preliminary data shows that Li-ESWT treatments, at different intensities, may decrease fibrosis induced by TGF-B1 TA injections. Additionally, Li-ESWT was not found to have conclusive positive effects on erectile function.

2nd^d Annual Fall Scientific Meeting of SMSNA. Abstract No. 63.

Study Performance: **urogold100**

7.2. Erectile Dysfunction

7.2.1. Low-energy Shock Wave Therapy Ameliorates Erectile Dysfunction in a Pelvic Neurovascular Injuries Rat Model (Li et al., 2016)

University of California, San Francisco.

Introduction: Erectile dysfunction (ED) caused by pelvic injuries is a common complication of civil and battlefield trauma with multiple neurovascular factors involved, and no effective therapeutic approach is available.

Aims: To test the effect and mechanisms of low-energy shock wave (LESW) therapy in a rat ED model induced by pelvic neurovascular injuries.

Methods: Thirty-two male Sprague-Dawley rats injected with 5-ethynyl-2'-deoxyuridine (EdU) at newborn were divided into 4 groups: sham surgery (Sham), pelvic neurovascular injury by bilateral



cavernous nerve injury and internal pudendal bundle injury (PVNI), PVNI treated with LESW at low energy (Low), and PVNI treated with LESW at high energy (High). After LESW treatment, rats underwent erectile function measurement and the tissues were harvested for histologic and molecular study. To examine the effect of LESW on Schwann cells, in vitro studies were conducted.

Main outcome measurements: The intracavernous pressure (ICP) measurement, histological examination, and Western blot (WB) were conducted. Cell cycle, Schwann cell activation-related markers were examined in in vitro experiments.

Results: LESW treatment improves erectile function in a rat model of pelvic neurovascular injury by leading to angiogenesis, tissue restoration, and nerve generation with more endogenous EdU(+) progenitor cells recruited to the damaged area and activation of Schwann cells. LESW facilitates more complete re-innervation of penile tissue with regeneration of neuronal nitric oxide synthase (nNOS)-positive nerves from the MPG to the penis. In vitro experiments demonstrated that LESW has a direct effect on Schwann cell proliferation. Schwann cell activation-related markers including p-Erk1/2 and p75 were upregulated after LESW treatment.

Conclusion: LESW-induced endogenous progenitor cell recruitment and Schwann cell activation coincides with angiogenesis, tissue, and nerve generation in a rat model of pelvic neurovascular injuries.

Study Performance: **dermagold100**

7.2.2. Effects of Low-Energy Shockwave Therapy on the Erectile Function and Tissue of a Diabetic Rat Model (Qiu et al., 2013)

Knappe Molecular Urology Laboratory, Department of Urology, School of Medicine, University of California, San Francisco, CA 94143-0738, USA.

Introduction. Low-energy shockwave therapy (LESWT) has been shown to improve erectile function in patients suffering from diabetes mellitus (DM)-associated erectile dysfunction (ED). However, the underlying mechanism remains unknown.

Aim. The aim of this study is to investigate whether LESWT can ameliorate DM-associated ED in a rat model and examine the associated changes in the erectile tissues.

Methods. Newborn male rats were intraperitoneally injected with 5-ethynyl-2-deoxyuridine (EdU; 50 mg/kg) for the purpose of tracking endogenous mesenchymal stem cells (MSCs). Eight weeks later, eight of these rats were randomly chosen to serve as normal control (N group). The remaining rats were injected intraperitoneally with 60 mg/kg of streptozotocin (STZ) to induce DM. Eight of these rats were randomly chosen to serve as DM control (DM group), whereas another eight rats were subject to shockwave (SW) treatment (DM+SW group). Each rat in the DM+SW group received 300 shocks at energy level of 0.1 mJ/mm² and frequency of 120/minute. This procedure was repeated three times a week for 2 weeks. Another 2 weeks later, all 24 rats were evaluated for erectile function by intracavernous pressure (ICP) measurement. Afterward, their penile tissues were examined by histology.

Main Outcome Measures. Erectile function was measured by ICP. Neuronal nitric oxide synthase (nNOS)-positive nerves and the endothelium were examined by immunofluorescence staining. Smooth muscle and MSCs were examined by phalloidin and EdU staining, respectively.

Results. STZ treatment caused a significant decrease in erectile function and in the number of nNOS-positive nerves and in endothelial and smooth muscle contents. These DM-associated deficits were all partially but significantly reversed by LESWT. MSCs (EdU-positive cells) were significantly more numerous in DM+SW than in DM rats.

Conclusion. LESWT can partially ameliorate DM-associated ED by promoting regeneration of nNOS-positive nerves, endothelium, and smooth muscle in the penis. These beneficial effects appear to be mediated by recruitment of endogenous MSCs. Qiu X, Lin G, Xin Z, Ferretti L, Zhang H, Lue TF, and Lin C-S. Effects of low-energy shockwave therapy on the erectile function and tissue of a diabetic rat model.

Study Performance: **dermagold100**

7.3. Chronic Pelvic Pain / Chronic Prostatitis

--

7.4. Stress Urinary Incontinence

7.4.1. Delayed Treatment with Low-intensity Extracorporeal Shock Wave Therapy in an Irreversible Rat Model of Stress Urinary Incontinence (Zhang et al., 2020)

Department of Urology, Knuppe Molecular Urology Laboratory, School of Medicine, University of California, San Francisco, CA.

Objective: To determine the outcomes and mechanisms of delayed low-intensity extracorporeal shock wave therapy (Li-ESWT) in a rat model of irreversible stress urinary incontinence (SUI).

Materials and methods: Twenty-four female Sprague-Dawley rats were randomly assigned into 3 groups: sham control, vaginal balloon dilation + β -aminopropionitrile (BAPN; SUI group), and vaginal balloon dilation + BAPN + treatment with Li-ESWT (SUI-Li-ESWT group). An irreversible SUI model was developed by inhibiting the urethral structural recovery with BAPN daily for 5 weeks. Thereafter, in the SUI-Li-ESWT group, Li-ESWT was administered twice per week for 2 weeks. After a 1-week washout, all 24 rats were evaluated with functional and histologic studies at 17 weeks of age. Endogenous progenitor cells were detected via the EdU-labeling method.

Results: Functional analysis with leak point pressure testing showed that the SUI-Li-ESWT group had significantly higher leak point pressures compared with untreated rats. Increased urethral and vaginal smooth and striated muscle content and increased thickness of the vaginal wall were noted in the SUI-Li-ESWT group. The SUI group had significantly decreased neuronal nitric oxide /tyrosine hydroxylase positive nerves ratio in the smooth muscle layers of the urethra, while the SUI-Li-ESWT group had neuronal nitric oxide/tyrosine hydroxylase+ nerves ratio similar to that of the control group. The continuity of urothelial cell lining was also improved in the SUI-Li-ESWT group. In addition, there were significantly increased EdU-positive cells in the SUI-Li-ESWT group.

Conclusion: Li-ESWT appears to increase smooth muscle content in the urethra and the vagina, increase the thickness of urethral wall, improve striated muscle content and neuromuscular junctions, restore the integrity of the urothelium, and increase the number of EdU-retaining progenitor cells in the urethral wall.

Study Performance: **dermagold100**

7.4.2. Treatment of Stress Urinary Incontinence with Low-Intensity Extracorporeal Shock Wave Therapy in a Vaginal Balloon Dilation Induced Rat Model (A. K. Wu et al., 2018)

Knuppe Molecular Urology Laboratory, Department of Urology, School of Medicine, University of California, San Francisco, CA, USA.



Background: To investigate the outcomes and mechanisms of low-intensity extracorporeal shock wave therapy (Li-ESWT) on stress urinary incontinence (SUI) in a vaginal balloon dilation (VBD) rat model.

Methods: Thirty Sprague-Dawley rats were randomly grouped into normal controls, VBD only, and VBD with Li-ESWT. Li-ESWT was administered twice per week for 3 weeks. Afterward, all 30 rats were assessed with functional and histological studies. To explore the acute effect of Li-ESWT, another 25 rats, given intraperitoneal 5-ethynyl-2-deoxyuridine (EdU) at birth, were treated with Li-ESWT followed by assessment of vascular endothelial growth factor (VEGF) expression and endogenous progenitor cells distribution at 24 hours or 1 week after the last Li-ESWT therapy. Additionally, rat myoblast L6 cells were used for myotube formation assay *in vitro*.

Results: Functional analysis with leak-point pressure (LPP) testing showed that rats treated with Li-ESWT following VBD had significantly higher LPP relative to those receiving VBD only (44.8 ± 3.2 versus 27.0 ± 2.9 cmH₂O, $P < 0.01$). Histological examinations showed increased urethral sphincter regeneration in Li-ESWT group. The rats treated with Li-ESWT also had increased vascularity, which was confirmed by immunohistochemistry of rat endothelial cell antigen, while reverse-transcriptase polymerase chain reaction (RT-PCR) showed VEGF expression was significantly enhanced. Additionally, there were significantly increased EdU+ cells in Li-ESWT treated rats at 24 hours. *In vitro*, Li-ESWT promoted myotube formation from L6 cells.

Conclusions: Li-ESWT ameliorated SUI by promoting angiogenesis, progenitor cell recruitment, and urethral sphincter regeneration in a rat model induced by VBD. Li-ESWT represents a potential novel non-invasive therapy for SUI.

Study Performance: **dermagold100**

7.5. Lithotripsy - Kidney and Ureter Stone Disease

7.5.1. Evaluation of the LithoGold LG-380 Lithotripter: In Vitro Acoustic Characterization and Assessment of Renal Injury in the Pig Model (Pishchalnikov et al., 2013)

Department of Anatomy and Cell Biology, Indiana University School of Medicine, 635 Barnhill Dr., Indianapolis, IN 46202-5120, USA.

Purpose: Conduct a laboratory evaluation of a novel low-pressure, broad focal zone electrohydraulic lithotripter (TRT LG-380).

Methods: Mapping of the acoustic field of the LG-380, along with a Dornier HM3, a Storz Modulith SLX, and a XiXin CS2012 (XX-ES) lithotripter was performed using a fiberoptic hydrophone. A pig model was used to assess renal response to 3000 shockwaves (SW) administered by a multistep power ramping protocol at 60 SW/min, and when animals were treated at the maximum power setting at 120 SW/min. Injury to the kidney was assessed by quantitation of lesion size and routine measures of renal function.

Results: SW amplitudes for the LG-380 ranged from (P(+)/P(-)) 7/-1.8 MPa at PL-1 to 21/-4 MPa at PL-11 while focal width measured ~20 mm, wider than the HM3 (8 mm), SLX (2.6 mm), or XX-ES (18 mm). For the LG-380, there was gradual narrowing of the focal width to ~10 mm after 5000 SWs, but this had negligible effect on breakage of model stones, because stones positioned at the periphery of the focal volume (10 mm off-axis) broke nearly as well as stones at the target point. Kidney injury measured less than 0.1% FRV (functional renal volume) for pigs treated using a gradual power ramping protocol at 60 SW/min and when SWs were delivered at maximum power at 120 SW/min.

Conclusions: The LG-380 exhibits the acoustic characteristics of a low-pressure, wide focal zone lithotripter and has the broadest focal width of any lithotripter yet reported. Although there was a gradual narrowing of focal width as the electrode aged, the efficiency of stone breakage was not

affected. Because injury to the kidney was minimal when treatment followed either the recommended slow SW-rate multistep ramping protocol or when all SWs were delivered at fast SW-rate using maximum power, this appears to be a relatively safe lithotripter.

Study Performance: lithoGold380

8. Neurology

8.1. Spinal Cord Injury

8.1.1. Neuronal Pre- and Postconditioning via Toll-like Receptor 3 Agonist or Extracorporeal Shock Wave Therapy as New Treatment Strategies for Spinal Cord Ischemia: An In Vitro Study (Lobenwein et al., 2022)

Department of Vascular Surgery, Medical University of Innsbruck, 6020 Innsbruck, Austria.

Spinal cord ischemia (SCI) is a devastating and unpredictable complication of thoracoabdominal aortic repair. Postischemic Toll-like receptor 3 (TLR3) activation through either direct agonists or shock wave therapy (SWT) has been previously shown to ameliorate damage in SCI models. Whether the same applies for pre- or postconditioning remains unclear. In a model of cultured SHSY-5Y cells, preconditioning with either poly(I:C), a TLR3 agonist, or SWT was performed before induction of hypoxia, whereas postconditioning treatment was performed after termination of hypoxia. We measured cytokine expression via RT-PCR and utilized Western blot analysis for the analysis of signaling and apoptosis. TLR3 activation via poly(I:C) significantly reduced apoptotic markers in both pre- and postconditioning, the former yielding more favorable results through an additional suppression of TLR4 and its downstream signaling. On the contrary, SWT showed slightly more favorable effects in the setting of postconditioning with significantly reduced markers of apoptosis. Pre- and post-ischemic direct TLR3 activation as well as post-ischemic SWT can decrease apoptosis and proinflammatory cytokine expression significantly in vitro and might therefore pose possible new treatment strategies for ischemic spinal cord injury.

Study Performance: OrthoGold180, applicator CG050

8.1.2. Shock Waves Induce an Evolutionary Conserved Mechanism of Spinal Cord Regeneration (Gollmann-Tepeköylü et al., 2021)

Medical University of Innsbruck, Innsbruck, Austria.

Introduction

Spinal cord ischemia (SCI) remains a devastating complication after aortic dissection or repair. A primary hypoxic damage is followed by a secondary damage resulting in further cellular loss via apoptosis. Affected patients have a poor prognosis and limited therapeutic options. In this study we aimed to (a) investigate the efficacy of SWT for regeneration of SCI and (b) to highlight underlying mechanisms.

Material & Method

SCI was performed in a murine contusion model in wild-type (WT) and Tlr3^{-/-} mice with subsequent SWT. Functional performance of animals was evaluated. Spinal cord lesions and bladder size were quantified and evaluated via MRI. Dorsal root ganglia (DRGs) were isolated and neuronal sprouting,



survival and metabolism were evaluated. Human spinal slice culture was performed. Zebrafish were subjected to traumatic spinal cord injuries followed by treatment with a TLR3 inhibitor or a TLR3 agonist.

Results

SWT improves motor function and decreases lesion size in wild-type but not *Tlr3*^{-/-} mice via inhibition of neuronal degeneration and IL6-dependent recruitment and differentiation of neuronal progenitor cells. SWT reduced the number of ROS positive cells and apoptosis upon ischemia via induction of the antioxidative factor NRF2. Both SWT and TLR3 stimulation enhance neuronal sprouting and improve neuronal survival, even in human spinal cord cultures. We identify TLR3 as crucial enhancer of spinal cord regeneration in zebrafish. To translate our findings into a clinical setting, we treated five patients with spinal cord ischemia using SWT (mean age 65.3 years). Four patients presented with acute aortic dissection (80%), 2 of them exhibited preoperative neurological symptoms (40%). Impairment was ASIA A in 1 patient (20%), ASIA B in 3 patients (60%) and ASIA D in 1 patient (20%) at baseline. At follow up, 2 patients were graded as ASIA A (40%) and 3 patients as ASIA B (60%). SCIM score showed significant improvement. Examination of WHOQOL questionnaires revealed increased scores at follow up.

Discussion

Our findings indicate that TLR3-signalling is an evolutionary conserved pathway involved in spinal cord regeneration and suggest its stimulation via SWT could become a potent regenerative treatment option.

23rd World Congress of the ISMST 2017 in Vienna, Austria, 2. Basic Research.

Study Performance: **orthogold180c**

8.1.3. Shock Waves Promote Spinal Cord Repair via TLR3 (Gollmann-Tepeköylü et al., 2020)

Medical University of Innsbruck, Innsbruck, Austria.

Spinal cord injury (SCI) remains a devastating condition with poor prognosis and very limited treatment options. Affected patients are severely restricted in their daily activities. Shock wave therapy (SWT) has shown potent regenerative properties in bone fractures, wounds, and ischemic myocardium via activation of the innate immune receptor TLR3. Here, we report on the efficacy of SWT for regeneration of SCI. SWT improved motor function and decreased lesion size in WT but not *Tlr3*^{-/-} mice via inhibition of neuronal degeneration and IL6-dependent recruitment and differentiation of neuronal progenitor cells. Both SWT and TLR3 stimulation enhanced neuronal sprouting and improved neuronal survival, even in human spinal cord cultures. We identified *tlr3* as crucial enhancer of spinal cord regeneration in zebrafish. Our findings indicate that TLR3 signaling is involved in neuroprotection and spinal cord repair and suggest that TLR3 stimulation via SWT could become a potent regenerative treatment option.

Study Performance: **orthogold180c** with applicator CG050-P

8.1.4. Shock Waves Enhance Neuronal Survival and Improve Motor Function After Traumatic Spinal Cord Injury (Tepeköylü C., Nägele F., ...Holfeld J. et al., 2017)

Department of Cardiac Surgery, Medical university of Innsbruck, Austria.

Introduction: We hypothesized that SWT induces regeneration in traumatic spinal cord injury.

Material and Method: SCI was performed in a murine contusion model in wild-type (WT) and TLR3^{-/-} mice. Animals received 500 shock waves at 0.1 mJ/mm². Functional performance of animals was evaluated. Spinal cord lesions and bladder size were quantified and evaluated via

MRI. Dorsal root ganglia (DRGs) were isolated and neuronal sprouting, survival and metabolism were evaluated. Human spinal slice culture was performed

Results: SW treated animals showed significantly improved motor function and decreased neuronal degeneration. MRI revealed reduction of lesion size. SWT resulted in upregulation of angiogenic genes and modulation of inflammation. Treated animals showed a survival benefit. We found enhanced neuronal sprouting, reduced apoptosis, improved metabolism after SWT. Effects were TLR3-dependent.

Discussion: SWT induces spinal cord regeneration via enhanced neuronal sprouting, reduction of apoptosis and stimulation of cell metabolism. Treated animals show improved motor function, improved vegetative symptoms and enhanced survival. All observed effects are TLR3-dependent.

Conclusion: SWT could develop a potent regenerative treatment option for patients with spinal cord injury.

20th International Congress of the ISMST 2017 in San Sebastian, Spain, Abstract P31.

Study Performance: **orthogold180C** with applicator CP050

8.1.5.ESWT In Experimental Traumatic Spinal Cord (SCI) Injury (Posa et al., 2016)

Ludwig Boltzmann Institut for Experimental and Clinical Traumatology, Vienna, Austria Austrian Cluster for Tissue Regeneration.

Introduction: Traumatic spinal cord injury (SCI) affects annually 250,000 to 500,000 people worldwide and significantly changes their daily living. More than 60% of individuals with SCI develop symptoms of spasticity and over 80% suffer from chronic neuropathic pain in the paralyzed body parts below the lesion. Altogether, these SCI induced impairments result in severe decline in the patient's quality of life. Although enormous progress was achieved in understanding the pathophysiology of SCI in the past treatment options to cure or improve symptoms at least are still very limited. The aim of the present study was to develop an experimental model of traumatic spinal cord injury and to investigate the influence of low-energy shockwave therapy at clinically relevant time points, i.e. sub-acute and chronic phases after SCI.

Methods: A traumatic rodent spinal cord injury model was established by using Sprague Dawley rats which were subjected initially to a laminectomy at the THX1 level. Thereafter, a contusion with a force of 150 kdynes was induced directly to the spinal cord using the Infinite Horizon Impactor (Precision Systems and Instrumentation, LLC, Lexington, KY, USA). Depending on the group allocation animals received 500 shockwaves at an energy flux density of 0.11mJ/mm² at 5Hz once a week for 3 consecutive weeks whether 2 weeks after the traumatic impact (sub-acute model) or 5 weeks thereafter (chronic model) and were compared to control animals. Analysis in the initial phase of the study included the open field walking test (BBB).

Results: A reliable and clinically relevant experimental model of traumatic spinal cord injury could be established. ESWT proved to be well tolerated by the animals without clinically relevant impact on lung tissue. In the first analysis control animals were compared with animals in the chronic model receiving shockwaves after 5 weeks. The induced traumatic injury resulted in a low BBB score of approximately 4 in all animals having no ESWT at this time point. Until week 2 after injury a continuous improvement was observed but maintained at a level of approximately 12 with no significant differences between groups. After the first ESW treatment the BBB score in the chronic model improved becoming significantly different at week 17 after impact compared to controls in which the BBB score remained constant.



Discussion: This study gives first hints that ESWT is able to positively influence spinal cord recovery after traumatic infliction in this experimental spinal cord injury model as indicated in improved BBB scores in the chronic model.

19th ISMST Congress in Kuching, Malaysia. Abstract No. 33.

Study Performance: **dermagold100**

8.1.6. Shock Wave Therapy Enhances Neuronal Sprouting and Improves Neuronal Survival (An A., Nägele F, ...Tepeköylü C. et al., 2016)

Department for Cardiac Surgery, Medical University of Innsbruck, Innsbruck, Austria.

Background: Shock wave therapy (SWT) has been shown to induce tissue regeneration and improve function in spinal cord ischemia via TLR3. Thereby, induction of angiogenesis and alteration of microglial response could be observed. However, it remains unknown whether SWT exerts a regenerative effect on neurons, too. We aimed to analyze whether (1) SWT improves neuronal survival and enhances neurite growth and (2) TLR3 signaling is involved.

Methods: Dorsal Root Ganglia (DRG) were isolated from Wild Type (WT) and TLR3 ^{-/-} mice and subsequently treated with SWT (0.01mJ/mm², 250 Impulses, 3Hz) or TLR3 agonist Poly(I:C). Control groups remained untreated. DRGs were analyzed via neuronal sprouting assay and survival was evaluated by TUNEL assay. Transmission electron microscopy (TEM) was used to evaluate the morphology of neurons and to assess vesicle release.

Results: SWT lead to enhanced neurite growth and an increase of branch points (CTR 1433 ± 76.61 vs. SWT 2061 ± 151.5, p<0.0001). Treated neurons showed improved survival rates. SWT effects were missing in neurons isolated from TLR3 ^{-/-} animals. Poly(I:C) treatment mimicked SWT effects. TEM analysis revealed release of microvesicles in treated neurons.

Conclusion: SWT enhances neurite growth and improves neuronal survival via activation of TLR3. It could therefore develop as a potent therapeutic intervention for neuronal regeneration.

4th ISMST Basic Research Meeting, 2016 in Vienna, Austria.

Study Performance: **orthogold180C** with applicator CP050

8.1.7. Shock Wave Treatment Reduces Neuronal Degeneration Upon Spinal Cord Ischemia via Toll-like Receptor 3 Dependent Mechanism (Lobenwein D, Tepeköylü C., ... Holfeld J. et al., 2016)

Department for Cardiac Surgery, Medical University of Innsbruck, Innsbruck, Austria.

OBJECTIVES: Paraplegia following spinal cord ischemia represents the most severe complication of aortic surgery. Shock wave treatment (SWT) was shown to induce angiogenesis and regeneration in ischemic tissue. In pre-clinical as well as clinical studies SWT had a favorable effect on ischemic myocardium. We therefore hypothesized that SWT may have a beneficial effect on spinal cord ischemia as well.

METHODS: Aortic cross clamp was performed between left carotid and left subclavian artery in mice. Animals were randomly divided in a treatment group (SWT, 500 shock waves at 0.1mJ/mm², 5Hz) and untreated controls (CTR), n=6 per group. RNA expression of angiogenic and inflammatory cytokines was measured after 24 and 48 hours. immunofluorescence staining for degenerating neurons and macrophages was performed after 7 days. An ex-vivo spinal slice culture was performed

for evaluation of Toll-like receptor (TLR) signaling. Spinal cords from wild type, TLR3 knockout and TLR4 knockout animals were cultured and set under hypoxia for 24 hours. Treatment groups (SWT) received shock wave treatment following hypoxia.

RESULTS: Real-time PCR analysis revealed higher gene expression of angiogenic factors VEGF-A after 24h (SWT 0.21 ± 0.06 vs. CTR 0.07 ± 0.01 , $p=0.028$) and 48h (SWT 0.11 ± 0.02 vs. CTR 0.07 ± 0.01 , $p>0.05$) as well as HIF-1 α after 24h (SWT 0.11 ± 0.04 vs. CTR 0.04 ± 0.01 , $p>0.05$) and 48h (SWT 0.09 ± 0.02 vs. CTR 0.01 ± 0 , $p=0.016$). Early increase of inflammatory mRNA expression was observed after 24h by TNF α (SWT 0.03 ± 0.003 vs. CTR 0.005 ± 0.003 , $p=0.007$) and TGF β (SWT 0.57 ± 0.05 vs. CTR 0.17 ± 0.08 , $p=0.003$). This resulted in a markedly decreased number of degenerating neurons in the treatment group 7 days after ischemia (SWT 74.50 ± 8.14 vs. CTR 250.2 ± 42.98 , $p=0.0025$). Standardized coordination and motor tests performed at day 1, 3 and 7 postoperatively revealed a significantly better performance and outcome of the animals in the treatment group. In addition, a Kaplan-Meier analysis revealed a survival benefit of SWT compared to normal animals. Effects of SWT were abolished in TLR3 knockout animals, whereas it was unchanged in TLR4 knockouts.

CONCLUSIONS: Shock wave treatment induces angiogenesis and modulates inflammation in spinal cord ischemia via the activation of TLR3. This results in a marked decrease of degenerating neurons and may therefore develop as an adjunct to the treatment armamentarium for paraplegia upon aortic cross clamp.

4th ISMST Basic Research Meeting, 2016 in Vienna, Austria.

Study Performance: orthogold180C with applicator CP050

8.1.8. Shock Wave Treatment Protects from Neuronal Degeneration via a Toll-Like Receptor 3 Dependent Mechanism: Implications of a First-Ever Causal Treatment for Ischemic Spinal Cord Injury (Lobenwein et al., 2015)

University Hospital for Cardiac Surgery, Innsbruck Medical University, Innsbruck, Austria.

Background: Paraplegia following spinal cord ischemia represents a devastating complication of both aortic surgery and endovascular aortic repair. Shock wave treatment was shown to induce angiogenesis and regeneration in ischemic tissue by modulation of early inflammatory response via Toll-like receptor (TLR) 3 signaling. In preclinical and clinical studies, shock wave treatment had a favorable effect on ischemic myocardium. We hypothesized that shock wave treatment also may have a beneficial effect on spinal cord ischemia.

Methods and results: A spinal cord ischemia model in mice and spinal slice cultures ex vivo were performed. Treatment groups received immediate shock wave therapy, which resulted in decreased neuronal degeneration and improved motor function. In spinal slice cultures, the activation of TLR3 could be observed. Shock wave effects were abolished in spinal slice cultures from TLR3(-/-) mice, whereas the effect was still present in TLR4(-/-) mice. TLR4 protein was found to be downregulated parallel to TLR3 signaling. Shock wave-treated animals showed significantly better functional outcome and survival. The protective effect on neurons could be reproduced in human spinal slices.

Conclusions: Shock wave treatment protects from neuronal degeneration via TLR3 signaling and subsequent TLR4 downregulation. Consequently, it represents a promising treatment option for the devastating complication of spinal cord ischemia after aortic repair.

Study Performance: orthogold180c with applicator CG050-P



8.2. Nerve Grafting / Peripheral Nerve Regeneration

8.2.1. *Effects of ESWT on Neuroregeneration after Median Nerve Reconstruction with Autologous Nerve Grafts or Three Different Conduits in the Rat (Heinzel et al., 2021)*

*Department of Hand-, Plastic, Reconstructive and Burn Surgery, BG Klinik Tübingen, Eberhard Karls University, Tübingen, Germany.
Ludwig Boltzmann Institute for Experimental and Clinical Traumatology, Vienna, Austria.
Austrian Cluster for Tissue Regeneration.*

Introduction

Several studies evaluating the effects of ESWT on nerve regeneration in the sciatic nerve model of the rat have shown proregenerative effects of this non-invasive treatment method. Effects of ESWT on nerve conduits remain mostly unstudied so far. A feasible alternative to the murine sciatic nerve model, which has some severe disadvantages regarding animal welfare and evaluation of experimental outcome, is the median nerve model of the rat. The aim of this work was to evaluate nerve regeneration following conduit repair of the median nerve with and without immediate ESWT in rats.

Material & Method

We microsurgically resected a 7-mm segment of the right median nerve in 123 male Lewis rats. The nerve defect was reconstructed with either an autologous nerve graft, muscle-in-vein conduit, chitosan-conduit, or silk fibroin conduit. Half of the animals in each group received a single application of ESWT (MTS, defocused, electrohydraulic applicator, 300 impulses, 3 Hz, 0.1 mJ/mm²). Functional recovery during the 12-weeks observation period was assessed via the grasping test, computerized gait analysis and electrophysiological evaluations.

Results

Regarding grasping strength, no significant effects of ESWT were apparent when comparing different reconstructive techniques, despite some positive tendencies. Electrophysiological evaluations did also not reveal any significant differences between reconstructive techniques, although autologous nerve grafts + ESWT were superior to both groups treated with muscle-in-vein conduits ($p < 0.05$) and animals treated with silk fibroin conduits ($p < 0.05$). Computerized gait analysis did also not reveal any significant effects of ESWT when comparing different reconstructive techniques.

Discussion

No significant effects of ESWT on peripheral nerve regeneration were observable in our study. This could on the one hand be related to the animal model we used, on the other hand the exact modes of action and optimum application forms of ESWT remain to be elucidated in future studies. The same applies to the materials used to manufacture nerve conduits. While evaluation of functional recovery via the grasping test was impeded in our study due to the animals' limited motivation to participate in the procedure, we were able to show that functional recovery was evaluable via computerized gait analysis.

23rd World Congress of the ISMST 2017 in Vienna, Austria, 2. Basic Research.

Study Performance: **OW100, applicator OP155**

8.2.2. *Motor and Sensory Schwann Cell Phenotype Commitment is Diminished by Extracorporeal Shockwave Treatment In Vitro (Hercher et al., 2020)*

Ludwig Boltzmann Institute for Experimental and Clinical Traumatology/AUVA Research Center, Vienna, Austria.

The gold standard for peripheral nerve regeneration uses a sensory autograft to bridge a motor/sensory defect site. For motor nerves to regenerate, Schwann cells (SC) myelinate the newly grown axon. Sensory SCs have a reduced ability to produce myelin, partially explaining low success rates of autografts. This issue is masked in pre-clinical research by the excessive use of the rat sciatic nerve defect model, utilizing a mixed nerve with motor and sensory SCs. Aim of this study was to utilize extracorporeal shockwave treatment as a novel tool to influence SC phenotype. SCs were isolated from motor, sensory and mixed rat nerves and in vitro differences between them were assessed concerning initial cell number, proliferation rate, neurite outgrowth as well as ability to express myelin. We verified the inferior capacity of sensory SCs to promote neurite outgrowth and express myelin-associated proteins. Motor Schwann cells demonstrated low proliferation rates, but strongly reacted to pro-myelination stimuli. It is noteworthy for pre-clinical research that sciatic SCs are a strongly mixed culture, not representing one or the other. Extracorporeal shockwave treatment (ESWT), induced in motor SCs an increased proliferation profile, while sensory SCs gained the ability to promote neurite outgrowth and express myelin-associated markers. We demonstrate a strong phenotype commitment of sciatic, motor, and sensory SCs in vitro, proposing the experimental use of SCs from pure cultures to better mimic clinical situations. Furthermore, we provide arguments for using ESWT on autografts to improve the regenerative capacity of sensory SCs.

Study Performance: **dermagold100** with applicator OP155

8.2.3. Efficacy of Extracorporeal Shockwaves Therapy on Peripheral Nerve Regeneration (Sağır et al., 2019)

Nursing Department, Health College, Sinop University, Sinop.

Purpose: This study was conducted to determine the effects of different doses and methods of extracorporeal shock wave treatment (ESWT) on the sciatic nerve regeneration of rat model using unbiased quantitative stereological techniques and to know which method and dose were effective.

Methods: Twenty-five Wistar albino rats were used in the experiment. All animals were randomly divided into 5 groups. To the first group (control, n = 5) ESWT and surgery were not applied. To 2nd group (E300*2, n = 5), twice doses of 300 impulses uESWs (unfocused) were applied. To 3rd group (E500*2, n = 5), twice doses of 500 impulses uESWs (unfocused) were applied. To 4th group (E300*2, n = 5), twice doses of 300 impulses of fESWs (focused) were applied. To 5th group (E500*2, n = 5), twice doses of 500 impulses of fESWs (focused) were applied. Rats were sacrificed and nerve samples analyzed on the 22nd day following the operation.

Results: There is a variable increase in the axon numbers among the shockwave treated groups in compare to the control group. The focused groups showed better improvement and the 300-focused group has shown the highest regeneration rate.

Conclusion: The authors found that ESWT promotes nerve regeneration, increases the thickness of the myelin sheath and that the most effective result is in the 300 shock waves.

Study Performance: **orthogold100** with applicator OE050

8.2.4. ESWT Affects Schwann Cell Phenotype In Vitro and In Vivo Thereby Accelerating Nerve Regeneration (Hercher et al., 2018)

Introduction

Peripheral nerve injuries are common and a frequent cause of hospitalization displaying a major burden to patients and social health-care systems. ESWT has been shown to be one of very few treatment options which accelerates peripheral nerve regeneration. Despite recent advances in



understanding the underlying mechanisms of ESWT, little is known of the effect on Schwann cells (SCs) and peripheral nerve regeneration. In this study we investigated these two aspects.

Methods

Schwann cells have been isolated from motor, sensory and mixed nerves, respectively. Dissected nerves have been treated with ESWT prior to isolation. Cultured SCs were evaluated using FACS analysis and western blot. *in vivo*: A femoral nerve defect model was established in the rat. The effects of ESWT on motor fibers regenerating through a sensory environment have been evaluated using automated gait analysis, electrophysiology, histology and qPCR.

Results

In vitro data indicate a strong influence of ESWT on the activation status of SCs of different phenotype. Motor SCs differ from sensory SCs regarding proliferation and expression of myelination associated proteins. ESWT is able to induce proliferation of motor and sensory SCs. *In vivo* data indicate inferior regeneration of motor axons through a sensory nerve graft compared to a phenotypically matched graft. ESWT can ameliorate this effect and accelerate nerve regeneration.

Discussion

This study indicates that ESWT is able to accelerate peripheral nerve regeneration in a model which reflects the clinical reality after autologous nerve transplantation. Thereby providing support for the use of ESWT after peripheral nerve injury.

TERMIS World Congress 2018 in Kyoto, Japan.

Study Performance: **dermagold100**

8.2.5.Extracorporeal Shockwave Treatment: A Novel Tool to Improve Schwann Cell Isolation and Culture (Schuh et al., 2016)

AUVA Research Center, Ludwig Boltzmann Institute for Experimental and Clinical Traumatology, Vienna, Austria; Austrian Cluster for Tissue Regeneration, Vienna, Austria.

Background aims: As new approaches for peripheral nerve regeneration are sought, there is an increasing demand for native Schwann cells for *in vitro* testing and/or reimplantation. Extracorporeal shockwave treatment (ESWT) is an emergent technology in the field of regenerative medicine that has also recently been shown to improve peripheral nerve regeneration.

Methods: In this study, we elucidate the effects of ESWT on Schwann cell isolation and culture. Rat sciatic nerves were dissected and treated with ESWT, and Schwann cells were isolated and cultured for 15 passages.

Results: Single treatment of the whole nerve *ex vivo* led to significantly increased extracellular adenosinetriphosphate as an immediate consequence, and subsequently a number of effects on the culture were observed, starting with a significantly increased Schwann cell yield after isolation. In the ESWT group, the quality of culture, reflected in consistently higher purity (S100b, morphology), proliferation rate (5-bromo-2-deoxyuridine, population doublings per passage) and expression of regenerative phenotype-associated markers (P75, glial fibrillary acidic protein, c-Jun), was significantly improved. In contrast, the control group exhibited progressively senescent behavior, reflected in a decrease of proliferation, loss of specific markers and increase in P16(INK4A) expression.

Conclusions: ESWT has beneficial effects on Schwann cell isolation and culture.

Study Performance: **dermagold100**

8.2.6.Regenerating Peripheral Nerves – Shockwave Treatment as A Supportive Mean (Hercher et al., 2016)

Ludwig Boltzmann Institut for Experimental and Clinical Traumatology, Vienna, Austria Austrian Cluster for Tissue Regeneration.

Introduction: Peripheral nerve injuries are common and a frequent cause of hospitalization displaying a major burden to patients and social health-care systems. ESWT has been shown to be one of very few treatment options which accelerates peripheral nerve regeneration. Despite recent advances in understanding the underlying mechanisms of ESWT, little is known of the effects on Schwann cells (SCs) and peripheral nerve regeneration. In this study we investigated these two aspects.

Methods: *in vitro*: Schwann cells have been isolated from motor, sensory and mixed nerves, respectively. Dissected nerves have been treated with ESWT prior to isolation. Cultured SCs were evaluated using FACS analysis and western blot. *in vivo*: A femoral nerve defect model was established in the rat. The effects of ESWT on motor fibers regenerating through a sensory environment have been evaluated using automated gait analysis, electrophysiology, histology and qPCR.

Results: *In vitro* data indicate a strong influence of ESWT on the activation status of SCs of different phenotype. Motor SCs differ from sensory SCs regarding proliferation and expression of myelination associated proteins. ESWT is able to induce proliferation of motor and sensory SCs. *In vivo* data indicate inferior regeneration of motor axons through a sensory nerve graft compared to a phenotypically matched graft. ESWT can ameliorate this effect and accelerate nerve regeneration.

Discussion: This study indicates that ESWT is able to accelerate peripheral nerve regeneration in a model which reflects the clinical reality after autologous nerve transplantation. Thereby providing support for the use of ESWT after peripheral nerve injury.

Setup: *in vitro*: waterbath, whole nerve. *in vivo*: 1x transcutaneously after wound closure

19th ISMST Congress in Kuching, Malaysia. Abstract No. 32.

Study Performance: **Derma**gold100

8.2.7.ESWT Affects Schwann Cell Phenotype In Vitro and In Vivo thereby Accelerating Nerve Regeneration (Hercher D., Schuh C., et al., 2016)

Ludwig Boltzmann Institute for Experimental and Clinical Traumatology, Vienna.

Introduction: Peripheral nerve injuries are common and a frequent cause of hospitalization displaying a major burden to patients and social health-care systems. ESWT has been shown to be one of very few treatment options which accelerate peripheral nerve regeneration. Despite recent advances in understanding the underlying mechanisms of ESWT, little is known of the effect on Schwann cells (SCs) and peripheral nerve regeneration. In this study we investigated these two aspects.

Methods: *In vitro*: Schwann cells have been isolated from motor, sensory and mixed nerves, respectively. Dissected nerves have been treated with ESWT prior to isolation. Cultured SCs were evaluated using FACS analysis and western blot.

In vivo: A femoral nerve defect model was established in the rat. The effects of ESWT on motor fibers regenerating through a sensory environment have been evaluated using automated gait analysis, electrophysiology, histology and qPCR.

Results: *In vitro* data indicate a strong influence of ESWT on the activation status of SCs of different phenotype. Motor SCs differ from sensory SCs regarding proliferation and expression of myelination associated proteins. ESWT is able to induce proliferation of motor and sensory SCs.

In vivo data indicate inferior regeneration of motor axons through a sensory nerve graft compared to a phenotypically matched graft. ESWT can ameliorate this effect and accelerate nerve regeneration.



Discussion: This study indicates that ESWT is able to accelerate peripheral nerve regeneration in a model which reflects the clinical reality after autologous nerve transplantation. Thereby providing support for the use of ESWT after peripheral nerve injury.

4th ISMST Basic Research Meeting, 2016 in Vienna, Austria.

Study Performance: **dermagold100**

8.2.8.ESWT Affects Schwann Cell Phenotype in Vitro and in Vivo Thereby Accelerating Nerve Regeneration (Hercher et al., 2015)

Ludwig-Boltzmann-Institute, Vienna, Austria.

Introduction:

Peripheral nerve injuries are common and a frequent cause of hospitalization displaying a major burden to patients and health-care systems. ESWT has been shown to be one of very few treatment options which accelerate regeneration of peripheral nerves. Despite recent advances in understanding the underlying mechanisms of ESWT, little is known of the effect on Schwann Cells (SCs) and peripheral nerve regeneration. In this study we investigated these two aspects.

Methods:

In vitro: Schwann cells have been isolated from motor, sensory and mixed nerves, respectively. Dissected nerves have been treated with ESWT prior to isolation. Cultured SCs were evaluated using FACS analysis and western blot.

In vivo: A femoral nerve defect model was established in the rat. The effects of ESWT on motor fibers regenerating through a sensory environment have been evaluated using automated gait analysis, electrophysiology, histology and qPCR.

Results:

In vitro data indicate a strong influence of ESWT on the activation status of SCs of different phenotype. Motor SCs differ from sensory SCs regarding proliferation and expression of myelination associated proteins. ESWT is able to enhance proliferation of motor and sensory SCs by a multiple of the control levels. In vivo data show inferior regeneration of motor axons through a sensory nerve graft compared to a phenotypically matched graft. ESWT can ameliorate this effect.

Discussion:

This study indicates that ESWT is able to accelerate peripheral nerve regeneration in a model which reflects the clinical reality after autologous nerve transplantation.

Conclusion:

This study provides support for the use of ESWT after peripheral nerve injury.

18th International Congress of the ISMST 2015, Mendoza, Argentina. Abstract No. 4.

Study Performance: **dermagold180**

8.2.9.The Activating Effect of ESWT on Schwann Cells In Vitro and In Vivo (Hercher D., Schuh C., 2014)

Ludwig Boltzmann Institute, Vienna, Austria.

Introduction: Peripheral nerve injuries are common and a frequent cause of hospitalization displaying a major burden to patients and social health-care systems. Extracorporeal shockwave therapy (ESWT) has been shown to accelerate peripheral nerve regeneration but the underlying mechanisms are still

unclear. Schwann cells (SCs) are activated after injury, switch from a myelinating to a proliferating, axonal growth promoting state. In this study we investigated the effect of ESWT on SCs and peripheral nerve regeneration on a molecular level.

Methods: Schwann cells have been isolated from motor, sensory and mixed nerves, respectively, using an established protocol. Dissected nerves have been treated with ESWT prior to isolation. Their activation status has been evaluated using FACS analysis. Additionally, an in vivo femoral nerve defect model in the rat has been established. RNA has been extracted from whole nerves at different timepoints after injury to evaluate the influence of ESWT on the expression profiles of injured and regenerating nerves by qPCR.

Results: Myelination markers like P0 are down-regulated in ESWT treated SCs whereas p75 is upregulated, representing an activated state of SCs. This effect is confirmed by in vivo data, where an upregulation of p75 and other pro-regenerative markers is observed up to 10 weeks after injury in the ESWT treated animals.

Discussion: In vitro and in vivo data indicate a strong influence of ESWT on the activation status of Schwann cells.

Conclusion: We hypothesize that ESWT has a beneficial effect on the pro-regenerative status of SCs in vitro and in vivo.

17th International Congress of the ISMST 2014, Milano, Italy.

Study Performance: **orthogold100**

8.2.10. Improved Rate of Peripheral Nerve Regeneration Induced by Extracorporeal Shock Wave Treatment in the Rat (Hausner et al., 2012)

Austrian Cluster for Tissue Regeneration and Ludwig Boltzmann Institute for Experimental and Clinical Traumatology at the Research Centre for Traumatology of the Austrian Workers' Compensation Board (AUVA), Donaueschingenstr. 13, A-1200 Vienna, Austria.

De-focused low energy extracorporeal shock wave therapy (ESWT) has been widely used in various clinical and experimental models for the treatment of painful conditions such as epicondylitis and plantar fasciitis and also bone and wound healing. There is evidence that ESWT improves the metabolic activity of various cell types, e.g. chondrocytes and endothelial cells but little is known about its effects on nervous tissue. The aim of this study was to investigate whether ESWT improves the regeneration of injured nerves in an experimental rat model. Sprague-Dawley rats received an 8mm long homotopic nerve autograft into the right sciatic nerve, fixed with epineural sutures. Two experimental groups were set up: the group 1 animals received ESWT (300 impulses, 3 Hz) immediately after nerve grafting whereas the group 2 (control) animals received only nerve autografts. Serial CatWalk automated gait analysis, electrophysiological studies and morphological investigations were carried out. The survival time was either 3 weeks or 3 months. At 6 to 8 weeks of survival the ESWT group of animals exhibited a significantly improved functional recovery relative to the controls. Electrophysiological observations at 3 weeks after surgery revealed marked values of amplitude (3.9 ± 0.8 mV, S.E.M.) and compound nerve action potential (CNAP, 5.9 ± 1.4 mV·ms, S.E.M.) in the ESWT group, whereas there were no detectable amplitudes in the control group. This finding was accompanied by significantly greater numbers of myelinated nerve fibers in the middle of the graft (4644 ± 170 [S.E.M., ESWT] vs 877 ± 68 [S.E.M., control]) and in the distal stump (1586 ± 157 [S.E.M., ESWT] vs 308 ± 29 [S.E.M., control]) of ESWT animals relative to the controls 3 weeks after surgery. Three weeks after surgery the nerve grafts of control animals contained great numbers of phagocytes and unmyelinated nerve fibers, while the ESWT nerve grafts were filled with well-myelinated regenerating axons. There was no significant



difference between the numbers of endoneural vessels in the ESWT and the control nerves. Three months after surgery, no significant differences were observed in the functional and electrophysiological data. Equally high numbers of myelinated axons distal to the graft could be found in both groups (7693 ± 673 [S.E.M., ESWT] vs 6090 ± 716 [S.E.M., control]). These results suggest that ESWT induces an improved rate of axonal regeneration, this phenomenon probably involving faster Wallerian degeneration, the improved removal of degenerated axons and a greater capacity of the injured axons to regenerate.

Study Performance: **orthowave180c**

8.2.11. Shock wave Therapy in Peripheral Nerve Repair: Investigation in a Rat Sciatic Nerve Repair Model (Halat et al., 2008)

Ludwig-Boltzmann-Institute for experimental and clinical traumatology and Austrian Cluster for Tissue Regeneration, Vienna, Austria. Lorenz Böhler Trauma Center AUVA, Vienna, Austria.

Introduction: De-focused low energy extracorporeal shock wave therapy has been used in various clinical and experimental models. Reports showed a significant increase of angiogenesis following shock wave application. The aim of our study was to investigate the effects of shock wave therapy on peripheral nerve regeneration, applied after a nerve grafting procedure.

Methods: 72 Sprague Dawley rats underwent mid-thigh sciatic nerve transection at two different levels creating an 8mm nerve graft. The nerve graft was now rotated 180 degrees and epineurial coaptation was performed immediately. All animals were randomly assigned to two experimental groups: Group 1: Shock wave therapy (300 impulses, 3 Hz) was applied over the graft using an ultrasound gel as a conductive and protective layer immediately after wound closure. Group 2: (sham control) Nerve graft without shock wave therapy. Serial functional tests (BBB locomotor rating scale, Inclined plane test, Toe spread test, Sensory and Proprioceptive placing tests as well as Catwalk® locomotion assessment device) were performed in weekly intervals within the period between the 1st and the 12th week after the grafting procedure. Electrophysiological studies were carried out 3, 6 and 12 weeks after surgery. Histologic and immuno-histochemical evaluation of neural collagenic connective tissue, axonal sprouting, axonal diameter and axonal count as well as angiogenesis was performed 1, 3 and 12 weeks after surgery.

Results: The shock wave group showed a significantly better functional recovery. The sensory function in the shock wave group reached a maximum (1.0 out of 1.2 mean points) 8 weeks after the surgery. In the control group, sensory performance reached a maximum (0.7 out of 1.2 mean points) 12 weeks following the surgery. The motor performance showed a significant improvement in the shock wave group in all intervals. The histological assessment indicated an increase of neural vessel count and a slight decrease of neural collagenic connective tissue within the nerve graft in the shock wave treated group in all intervals. The immuno-histochemical evaluation indicated an increase in the axonal sprouting rate distal of the nerve graft in the shock wave treated group. Moreover, electrophysiologic assessment illustrated the positive effect of the therapy on the regeneration of the sciatic nerve.

11th ISMST Congress in Juan le Pins, France Abstract No. 67.

Study Performance: **orthowave180c**

8.2.12. Shock Wave Therapy in Peripheral Nerve Repair (Halat et al., 2007)

Ludwig-Boltzmann-Institute for Traumatology and Austrian Cluster for Tissue Regeneration, Vienna, Austria. Lorenz Böhler Trauma Center AUVA, Vienna, Austria.

Introduction: De-focused low energy extracorporeal shock wave therapy has been used in various clinical and experimental models. Reports showed a significant increase of angiogenesis following shock wave application. The aim of our study was to investigate the effects of shock wave therapy on peripheral nerve regeneration, applied after a nerve grafting procedure.

Methods: Seventy-two Sprague Dawley rats underwent mid-thigh sciatic nerve transection at two different levels creating an 8mm nerve graft. The nerve graft was rotated 180 degrees and epineurial coaptation was performed immediately. All animals were randomly assigned to three experimental groups: Group1 - Shock wave therapy (300 impulses, 3 Hz) was applied through the closed wound over the graft using an ultrasound gel as a conductive and protective layer immediately after wound closure; Group 2 - Shock wave therapy was applied 2 days after surgery (assessments were carried out 1 week, 3 weeks, and 3 months after surgery); Group 3 - Control (nerve graft without shock wave therapy). Serial functional tests (BBB locomotor rating scale, Inclined plane test, Toe spread test, Sensory- and Proprioceptive placing tests) were performed at weekly intervals during the period between the 3rd and 12th week after the grafting procedure. At weeks 3 and 12, electrophysiological assessment was commenced. Additionally, at weeks 1, 3 and 12 histological samples were examined. Neural collagenic connective tissue and the number of vessels were evaluated.

Results: The shock wave groups showed a significantly better functional recovery. The sensory function in the shock wave groups reached their maximum (1.0 out of 1.2 mean points) 8 weeks after surgery. In the control group, sensory performance reached a maximum (0.7 out of 1.2 mean points) 12 weeks after surgery. The motor performance showed a significant improvement in all shock wave groups at all intervals. In all shock wave treated groups the histological examination indicated an increase of the vessel count and a slight decrease of neural collagenic connective tissue within the nerve graft at all intervals, corroborated to the control group. Moreover, electrophysiologic assessment illustrated the positive effect of the therapy on the regeneration of the sciatic nerve.

Discussion: It seems that improvement of angiogenesis may result in enhanced functional recovery. Further research for better understanding is necessary.

Conclusion: In a rat sciatic nerve graft repair model, shock wave therapy improves functional recovery, probably due to an increase of neural angiogenesis.

10th International Congress of the ISMST 2007 in Toronto, Canada, Abstract 44.

Study Performance: **OrthoWave180**

8.3. Transcranial ESWT

8.3.1.A Comparative Feasibility Study for Transcranial Extracorporeal Shock Wave Therapy (Slezak, Flatscher, et al., 2022)

The potential beneficial regenerative and stimulatory extracorporeal shock wave therapy (ESWT) applications to the central nervous system have garnered interest in recent years. Treatment zones for these indications are acoustically shielded by bones, which heavily impact generated sound fields. We present the results of high-resolution tissue-realistic simulations, comparing the viability of different ESWT applicators in their use for transcranial applications. The performances of electrohydraulic, electromagnetic, and piezoelectric transducers for key reflector geometries are compared. Based on density information obtained from CT imaging of the head, we utilized the non-linear wave propagation toolset MATLAB k-Wave to obtain spatial therapeutic sound field geometries and



waveforms. In order to understand the reliability of results on the appropriate modeling of the skull, three different bone attenuation models were compared. We find that all currently clinically ESWT applicator technologies show significant retention of peak pressures and energies past the bone barrier. Electromagnetic transducers maintain a significantly higher energy flux density compared to other technologies while low focusing strength piezoelectric applicators have the weakest transmissions. Attenuation estimates provide insights into sound field degradation and energy losses, indicating that effective transcranial therapies can readily be attained with current applicators. Furthermore, the presented approach will allow for future targeted in silico development and the design of applicators and therapy plans to ultimately improve therapeutic outcomes.

Study Performance: **orthogold100**, applicator OE050 & OP155

9. (Stem / Progenitor) Cell Activation

9.1. Advantages of Preconditioning of ASCs by Shockwave Therapy (Freitag et al., 2021)

DKF, Spain.

Introduction: Objective: Benefits of preconditioning of ASCs with shockwave therapy

Material & Method: Manual fat collection by liposuction to avoid cell trauma and isolation of mesenchymal cells in the laboratory.

Choice of plastic with fine thickness and moldable to favor the direct application of DEFOCUSED SHOCK WAVES (Orthogold), a total of 1000 IMPULSES with 0.2 MJ/mm², 4hz.

4 Groups: Group 1: no shock wave treatment, Group 2: shock waves applied to the stromal vascular fraction, Group 3: shock waves on liposuction, Group 4: shock waves on enzyme-treated liposuction
Comparison between the groups: Cellular viability study with XLSTAT program and application of Friedman's test. Adipogenic and osteogenic differentiation study, Cell growth study (cumulative growth). Study of colony formation. Study of cell migration.

Results: Shock waves do not affect the viability of ASCs (no change in cell morphology and power). Shock waves do not affect differentiation into adipose and osteogenic lineage.

Shock waves do not alter the ability of ASCs to form colonies of cellular progenitors.

Shock waves IMPROVE CELL GROWTH AND CELL MIGRATION.

Discussion: Shock waves can be the "link" of mechanotransduction for stimulating cell biology.

23rd World Congress of the ISMST 2021 in Vienna, Austria, 2. Basic Research.

Study Performance: **orthogold100** with applicator OP155

9.2. Improvement of Adipose Tissue-Derived Cells by Low-Energy Extracorporeal Shock Wave Therapy (Priglinger et al., 2017)

Ludwig Boltzmann Institute for Experimental and Clinical Traumatology, Austrian Workers' Compensation Board (AUVA) Research Center, Vienna, Austria; Austrian Cluster for Tissue Regeneration, Vienna, Austria.

Background: Cell-based therapies with autologous adipose tissue-derived cells have shown great potential in several clinical studies in the last decades. The majority of these studies have been using the stromal vascular fraction (SVF), a heterogeneous mixture of fibroblasts, lymphocytes, monocytes/macrophages, endothelial cells, endothelial progenitor cells, pericytes and adipose-

derived stromal/stem cells (ASC) among others. Although possible clinical applications of autologous adipose tissue-derived cells are manifold, they are limited by insufficient uniformity in cell identity and regenerative potency.

Methods: In our experimental set-up, low-energy extracorporeal shock wave therapy (ESWT) was performed on freshly obtained human adipose tissue and isolated adipose tissue SVF cells aiming to equalize and enhance stem cell properties and functionality.

Results: After ESWT on adipose tissue we could achieve higher cellular adenosine triphosphate (ATP) levels compared with ESWT on the isolated SVF as well as the control. ESWT on adipose tissue resulted in a significantly higher expression of single mesenchymal and vascular marker compared with untreated control. Analysis of SVF protein secretome revealed a significant enhancement in insulin-like growth factor (IGF)-1 and placental growth factor (PLGF) after ESWT on adipose tissue.

Discussion: Summarizing we could show that ESWT on adipose tissue enhanced the cellular ATP content and modified the expression of single mesenchymal and vascular marker, and thus potentially provides a more regenerative cell population. Because the effectiveness of autologous cell therapy is dependent on the therapeutic potency of the patient's cells, this technology might raise the number of patients eligible for autologous cell transplantation.

Study Performance: **dermagold100**

9.3. Shock Wave Treatment for In Vitro Engineering Applications (Anna M. Weihs et al., 2016)

University of Applied Sciences Technikum Wien, Vienna, Austria.

Introduction: Recently, the cellular effects of shock wave treatment have been thoroughly studied using *in vitro* approaches. We already described intracellular pathways involved in the shock wave treatment effect using *in vitro* shock wave treatment (IVSWT) water bath set-up and various cell types. We suppose that the beneficial cellular effects of shock waves – such as increased proliferation or enhanced growth factor expression – could also be exploited in the emerging field of tissue engineering. The adaptation of *in vitro* shock wave treatment parameters for the application on 3D cell culture systems and cell/scaffold constructs would therefore provide a promising tool for tissue engineering purposes.

Methods: Several three-dimensional cell culture systems such as spheroids of stem cells, various cell-loaded hydrogels and scaffolds, were subjected to *in vitro* shock wave treatment.

Results: Diverse protocols were developed and tested to establish optimal treatment set-ups and parameters, e.g. stiffness of the used scaffolds, medium density as well as optimal number of shock wave treatments were evaluated in order to find the optimal conditions for diverse 3D systems.

Discussion: The potential of shock wave treatment to trigger mechanosensitive pathways can be used to improve proliferation or differentiation in 3D systems *in vitro* in order to support scaffold maturation and ultimately enhance cell-scaffold performance. Thus, the experience on the application of shock waves on 3D cell culture systems and scaffolds will help to establish shock wave treatment as a potent tool in the field of tissue engineering and regenerative medicine.

4th ISMST Basic Research Meeting in Vienna, Austria.

Study Performance: **dermagold100** with applicator OP155

9.4. In Vitro Extracorporeal Shock Wave Treatment Enhances Stemness and Preserves Multipotency of Rat and Human Adipose-Derived Stem Cells (Schuh et al., 2014)



Ludwig Boltzmann Institute for Experimental and Clinical Traumatology, AUVA Research Center, Vienna, Austria; Austrian Cluster for Tissue Regeneration, Vienna, Austria; University of Applied Sciences Technikum Wien-Department of Biochemical Engineering, Vienna, Austria.

Background aims: Adipose-derived progenitor/stem cells (ASCs) are discussed as a promising candidate for various tissue engineering approaches. However, its applicability for the clinic is still difficult due to intra- and inter-donor heterogeneity and limited life span in vitro, influencing differentiation capacity as a consequence to decreased multipotency.

Methods: Extracorporeal shock wave treatment has been proven to be a suitable clinical tool to improve regeneration of a variety of tissues for several decades, whereas the mechanisms underlying these beneficial effects remain widely unknown.

Results: In this study we show that human and rat adipose derived stem cells respond strongly to repetitive shock wave treatment in vitro, resulting not only in maintenance and significant elevation of mesenchymal markers (CD73, CD90, CD105), but also in significantly increased differentiation capacity towards the osteogenic and adipogenic lineage as well as toward Schwann-cell like cells even after extended time in vitro, preserving multipotency of ASCs.

Conclusions: ESWT might be a promising tool to improve ASC quality for cell therapy in various tissue engineering and regenerative medicine applications.

Study Performance: **dermagold100** applicator OP155

9.5. Adipose Derived Stem Cells: In Vitro Treatment with Extracorporeal Shockwaves Enhances Stemness and Preserves Multipotency (Schuh et al., 2013)

Ludwig Boltzmann Institute for Experimental and Clinical Traumatology, AUVA Research Center, Vienna, Austria; Austrian Cluster for Tissue Regeneration, Vienna, Austria; University of Applied Sciences Technikum Wien-Department of Biochemical Engineering, Vienna, Austria.

Introduction: Adipose derived progenitor/stem cells (ASCs) are a promising tool for tissue engineering, addressing the problem of tissue and organ shortage. Limiting factors for the use of ASCs are donor variation and senescence, loss of differentiation capacity as a consequence to loss of multipotency. Extracorporeal shockwave treatment (ESWT) has been shown to have beneficial effects on regeneration of a variety of tissues in vivo.

Methods: Human and rat ASCs were treated in vitro with ESWT and evaluated concerning viability with MTT and BrdU assay, concerning stemness with flow cytometry (CD73, CD90, CD105) and concerning multipotency with differentiation into osteogenic lineage (von Kossa staining, PCR), adipogenic lineage (Oilred O staining) and Schwann like cells (flow cytometry: P75, S100b, P0).

Results: Human and rat ASCs respond strongly to repetitive shockwave treatment in vitro, resulting in maintenance and significant elevation of mesenchymal markers, while cell viability and proliferation remain at a comparable level to control group. Another effect observed was a significant increase in differentiation capacity into osteogenic and adipogenic lineage as well as into Schwann like cells in high passages.

Discussion: Our results indicate that with ESWT multipotency of ASCs can be preserved in high passages after extensive expansion. Hence, ESWT might be a promising tool to improve ASCs for cell therapy in tissue engineering and regenerative medicine.

16th ISMST Congress Salzburg, Austria. Abstract No. P5.

Study Performance: **dermagold100**

9.6. Shockwave Therapy on Human Fat-Derived Stem Cells (Morton et al., 2008)

Ludwig-Boltzmann-Institute for Experimental and Clinical Traumatology / AUVA Research Centre, Vienna, Austria. Austrian Cluster for Tissue Regeneration, Austria. Trauma Center Meidling, Vienna, Austria.

Introduction: The field of application for shockwave therapy has widened over the last few years. Electro-hydraulic shock wave technology has been used successfully for improved healing of chronic wounds. Little is known about the mechanism of action of shockwave therapy. In this study we treated isolated and cultured human adipose-derived stem cells to find out more about the influence of shockwave therapy on cells in vitro.

Methods: Human adipose-derived stem cells were seeded 24 hours before shockwave treatment into 6-well plates and covered with DMEM/HAM'sF12 medium containing 2% FCS. Thirty or 50 pulses with a frequency of 1 Hz and an energy flux density of 0.1 mJ/mm² (DermaGold, MTS Europe GmbH, Germany) were applied on the bottom of the cell culture plates. At certain time points, photographs for evaluation of the cell morphology were taken. On days 2, 7 and 14, cells were collected and RNA expression levels of different markers were analyzed.

Results: Macroscopically, human adipose-derived stem cells contracted their cytoskeleton to be only half the size directly after shockwave treatment. By day 2, cells had fully recovered their original size. Interestingly, shockwave therapy did not improve cell proliferation within 14 days. However, an upregulation of specific osteogenic expression genes in treated cells could be observed. Collagen 1 alpha 1 and the bone sialo protein showed significantly higher RNA expression levels in both treated groups compared to the control group (without shockwave therapy). Vimentin, desmin and alpha smooth muscle actin were also up-regulated in treated human adipose-derived stem cells.

Conclusion: In conclusion, shockwave therapy on isolated and cultured human adipose-derived stem cells does not influence cell proliferation but seems to induce or accelerate osteogenic differentiation in these cells.

11th ISMST Congress in Juan le Pins, France Abstract No. 57.

Study Performance: **DermaGold**

10. (Lymph-) Angiogenesis, Inflammatory Control and Cardiology

10.1. Hippo/YAP/TAZ Mediates Angiogenic Response and Exosome Release Upon SWT (Nägele et al., 2021)

Medical University of Innsbruck, Austria.

Introduction: SWT has been shown to induce tissue heart regeneration via (a) the release of angiogenic exosomes and (b) stimulating innate immune receptor TLR3. Hippo/YAP/TAZ is a crucial mechanosensing pathway mediating cardiac regeneration by stimulating the TLR-IFN pathway via exosome release. We therefore hypothesized that the mechanical stimulation of SWT causes the release of TLR3-activating exosomes via the Hippo/YAP/TAZ pathway.

Material & Method: Human endothelial cells were treated with SWT in vitro. Hippo/YAP/TAZ signaling was analyzed via immunostaining and western blotting. Transcriptional YAP/TAZ target gene expression was analyzed via RT-PCR upon SWT. A wound healing assay, a tube formation assay and proliferation were performed upon SWT in the presence of Hippo/YAP/TAZ stimulation or inhibition.



Hippo/YAP/TAZ dependent exosome release upon SWT was analyzed via nanoparticle-tracking analysis and FACS.

Results: SWT induced nuclear translocation of YAP/TAZ and subsequent upregulation. This resulted in transcription of *CYR61*, *ANKRD1* and *CTGF*, the transcriptional target genes of YAP/TAZ. SWT resulted in improved wound healing, increased tube formation and proliferation of endothelial cells. However, SW effects were abolished upon inhibition of YAP/TAZ, whereas stimulation with its agonist LPA could mimic SW effects. SWT induced release of exosomes. This was again dependent on YAP/TAZ signaling. Released exosomes stimulated innate immune receptor TLR3 and subsequent interferon signaling.

Discussion: SWT activates Hippo/YAP/TAZ with concomitant downstream signaling. Hippo/YAP/TAZ activation upon SWT induces exosome release. Released exosomes stimulate TLR3. The Hippo/YAP/TAZ pathway plays a crucial role in the mechanotransduction of SWT.

Study Performance: **orthogold180c**

23rd World Congress of the ISMST 2017 in Vienna, Austria, 2. Basic Research.

10.2. *miR-19a-3p Containing Exosomes Improve Function of Ischemic Myocardium Upon Shock Wave Therapy (Pölzl et al., 2021)*

Medical University of Innsbruck, Austria.

Introduction: As many current approaches for heart regeneration exert unfavorable side effects, the induction of endogenous repair mechanisms in ischemic heart disease is of particular interest. Recently, exosomes carrying angiogenic miRNAs have been described to improve heart function. However, it remains challenging to stimulate specific release of reparative exosomes in ischemic myocardium. In the present study, we sought to test the hypothesis that the physical stimulus of SWT causes the release of exosomes. We aimed to substantiate the pro-angiogenic impact of the released factors, to identify the nature of their cargo, and to test their efficacy in vivo supporting regeneration and recovery after myocardial ischemia.

Material & Method: Ischemic muscle and human umbilical vein endothelial cells underwent SWT. Exosomes were isolated subsequently from the supernatant and characterized by transmission electron microscopy, nanoparticle tracking analysis and flow cytometry. Exosome content was evaluated via a miRNA sequencing array. To investigate a potential effect of SWT in chronic ischemic heart failure, SWT was applied to chronic ischemic myocardium. Heart function was analyzed via transthoracic echocardiography and pressure/volume measurements and myocardial scar was quantified.

Results: Mechanical stimulation of ischemic muscle via SWT caused extracellular vesicle (EV) release from endothelial cells both in vitro and in vivo. Characterization of EVs via electron microscopy, nanoparticle tracking analysis and flow cytometry revealed specific exosome morphology and size with presence of exosome markers CD 9, CD81 and CD63. Exosomes exhibited angiogenic properties activating protein kinase b (Akt) and extracellular-signal regulated kinase (ERK) resulting in enhanced endothelial tube formation and proliferation. A miRNA array and transcriptome analysis via next-generation sequencing were performed to specify exosome content. miR-19a-3p was identified as responsible cargo, antimir-19a-3p antagonized angiogenic exosome effects. Exosomes and target miRNA were injected intramyocardially in mice after left anterior descending artery (LAD) ligation. Exosomes resulted in improved vascularization, decreased myocardial fibrosis and increased left ventricular ejection fraction.

Discussion: The mechanical stimulus of SWT causes release of angiogenic exosomes. miR-19a-3p is the vesicular cargo responsible for the observed effects. Released exosomes induce angiogenesis, decrease myocardial fibrosis and improve left ventricular function after myocardial ischemia.

Study Performance: **orthogold180c**

23rd World Congress of the ISMST 2017 in Vienna, Austria, 2. Basic Research.

10.3. Therapeutic Transdifferentiation of Fibroblasts to Functional Endothelial Cells Upon Shock Wave Therapy (Graber et al., 2021)

Medical University of Innsbruck, Austria.

Introduction: Reprogramming of cardiac fibroblasts towards functional endothelial cells is a promising strategy for the vascular regeneration of ischemic myocardium. Recent studies reveal that stimulation of inflammatory signaling is required for effective chromatin remodeling and nuclear reprogramming. Mechanical conditioning of myocardium via shock wave therapy (SWT) has been shown to activate TLR3. We hypothesized that the activation of TLR3 via SWT might facilitate reprogramming of fibroblasts towards endothelial cells.

Material & Method: Human cardiac fibroblasts were treated with SWT or TLR3 agonist poly(I:C) in the presence of a specific induction medium known to promote endothelial lineage and analyzed for the expression of endothelial- specific markers. Induced endothelial cells (iECs) were subjected to functional endothelial cell assays including NO production and tube formation. iECs were suspended in matrigel and injected subcutaneously. A lineage tracing experiment was performed in a transgenic mouse model of Fsp1- Cre/LacZ mice after coronary occlusion and SWT. Myocardial scarring was evaluated histologically, whereas left ventricular (LV) function was assessed via transthoracic echocardiography. Chromatin remodeling and epigenetic plasticity were evaluated via Western Blot and ATAC sequencing.

Results: SWT activated TLR3 signaling and triggered the expression of endothelial genes in a TLR3 dependent fashion. SWT resulted in higher numbers of iECs. iECs were capable of producing endothelial nitric oxide (NO) and of forming tube-like structures. In vivo, the subcutaneous injection of iECs resulted in higher numbers of vessels and improved perfusion in a Matrigel plug assay. In a lineage tracing experiment in Fsp1-Cre/LacZ mice, we found higher numbers of LacZ/CD31 positive cells after coronary occlusion and subsequent SWT indicating transdifferentiation in vivo. Myocardial scar size was reduced after SWT, whereas LV function was improved. Mechanistically, SWT enhanced epigenetic plasticity via the TLR3 – NFkB - IL-6 –STAT3 – PRDM14 axis. SWT and Poly(I:C) induced significant changes in chromatin organization, with chromatin being more accessible after both treatments in 1705 genomic regions.

Discussion: We provide evidence for the induction of transdifferentiation in ischemic myocardium via SWT. Therapeutic transdifferentiation may contribute to the beneficial effects of SWT in the clinic.

23rd World Congress of the ISMST 2017 in Vienna, Austria, 2. Basic Research.

Study Performance: **orthogold180c**

10.4. A Standardized Murine Model of Extracorporeal Shockwave Therapy Induced Soft Tissue Regeneration (Hirsch et al., 2021)

Department for Cardiac Surgery, Innsbruck Medical University.



Shockwave therapy (SWT) shows promising regenerative effects in several different tissues. However, the underlying molecular mechanisms are poorly understood. Angiogenesis, a process of new blood vessel formation is a leading driver of regeneration in softer tissues as well as a recently discovered effect of SWT. How the mechanical stimulus of SWT induces angiogenesis and regeneration and which pathways are involved is not fully understood. To further improve the clinical use of SWT and gain valuable information about how mechanical stimulation can affect tissue and tissue regeneration, a standardized model of SWT is needed. We, hereby, describe a standardized, easy to implement murine model of shockwave therapy induced regeneration, utilizing the hind-limb ischemia model.

Study Performance: **orthogold180c** with applicator CE50

10.5. *Defining a Therapeutic Range for Regeneration of Ischemic Myocardium via Shock Waves* (Pözl L et al., 2021)

Department of Cardiac Surgery, Medical University of Innsbruck, Innsbruck, Austria.

Shockwave therapy (SWT) represents a promising regenerative treatment option for patients with ischemic cardiomyopathy. Although no side-effects have been described upon SWT, potential cellular damage at therapeutic energies has not been addressed so far. In this work, we aimed to define a therapeutic range for shock wave application for myocardial regeneration. We could demonstrate that SWT does not induce cellular damage beneath energy levels of 0.27 mJ/mm² total flux density. Endothelial cell proliferation, angiogenic gene expression and phosphorylation of AKT and ERK are enhanced in a dose dependent manner until 0.15 mJ/mm² energy flux density. SWT induces regeneration of ischemic muscle in vivo via expression of angiogenic gene expression, enhanced neovascularization and improved limb perfusion in a dose-dependent manner. Therefore, we provide evidence for a dose-dependent induction of angiogenesis after SWT, as well as the absence of cellular damage upon SWT within the therapeutic range. These data define for the first time a therapeutic range of SWT, a promising regenerative treatment option for ischemic cardiomyopathy.

Also presented at the 23rd World Congress of the ISMST 2017 in Vienna, Austria, P1 Poster Presentation.

Study Performance: **orthogold180c** with applicator CE50

10.6. *Exosome Isolation after in vitro Shock Wave Therapy* (Pözl et al., 2020)

Department of Cardiac Surgery, Medical University Innsbruck; Institute of Clinical and Functional Anatomy, Innsbruck Medical University.

Shock wave therapy is routinely applied in orthopedic indications including tendinopathies such as lateral epicondylitis (tennis elbow) and Achilles tendinitis (heel spurs) as well as non-healing wounds and bones. Despite different pathologies, the combination of an angiogenic and an anti-inflammatory effect of shock wave therapy leads to regeneration in soft tissue and bones. In over 30 years of clinical application, no side effects were observed. Furthermore, basic research even revealed regenerative effects on ischemic myocardium. In a previous work we could show that the mechanical stimulus of cultured cells is translated via an exosome release into a biological response. However, the exact mechanism remains to be elucidated. Mechanical coupling is crucial when applying shock wave therapy as even small air bubbles can absorb shock waves. The previously described water bath method is a valid method to guarantee adequate and reproducible shock wave application in vitro. We were able to develop a feasible and replicable protocol to isolate exosomes from cultured cells after shock wave application. Thereby we demonstrate a possibility to study underlying mechanisms of

mechanotransduction as well as the regenerative and angiogenic potential of shock wave released exosomes.

Study Performance: **orthogold180C** with applicator CP050

10.7. *miR-19a-3p Containing Exosomes Improve Function of Ischemic Myocardium Upon Shock Wave Therapy* (Gollmann-Tepeköylü et al., 2019)

Department of Cardiac Surgery, Medical University of Innsbruck, Anichstrasse 35, 6020 Innsbruck, Austria.

Aims: As many current approaches for heart regeneration exert unfavourable side effects, the induction of endogenous repair mechanisms in ischaemic heart disease is of particular interest. Recently, exosomes carrying angiogenic miRNAs have been described to improve heart function. However, it remains challenging to stimulate specific release of reparative exosomes in ischaemic myocardium. In the present study, we sought to test the hypothesis that the physical stimulus of shock wave therapy (SWT) causes the release of exosomes. We aimed to substantiate the pro-angiogenic impact of the released factors, to identify the nature of their cargo, and to test their efficacy in vivo supporting regeneration and recovery after myocardial ischaemia.

Methods and results: Mechanical stimulation of ischaemic muscle via SWT caused extracellular vesicle (EV) release from endothelial cells both in vitro and in vivo. Characterization of EVs via electron microscopy, nanoparticle tracking analysis and flow cytometry revealed specific exosome morphology and size with the presence of exosome markers CD9, CD81, and CD63. Exosomes exhibited angiogenic properties activating protein kinase b (Akt) and extracellular-signal regulated kinase (ERK) resulting in enhanced endothelial tube formation and proliferation. A miRNA array and transcriptome analysis via next-generation sequencing were performed to specify exosome content. miR-19a-3p was identified as responsible cargo, antimir-19a-3p antagonized angiogenic exosome effects. Exosomes and target miRNA were injected intramyocardially in mice after left anterior descending artery ligation. Exosomes resulted in improved vascularization, decreased myocardial fibrosis, and increased left ventricular ejection fraction as shown by transthoracic echocardiography.

Conclusion: The mechanical stimulus of SWT causes release of angiogenic exosomes. miR-19a-3p is the vesicular cargo responsible for the observed effects. Released exosomes induce angiogenesis, decrease myocardial fibrosis, and improve left ventricular function after myocardial ischaemia. Exosome release via SWT could develop an innovative approach for the regeneration of ischaemic myocardium.

Study Performance: **orthogold180c** with applicator CG050-P

10.8. *Shock Wave Therapy Improves Cardiac Function in a Model of Chronic Ischemic Heart Failure: Evidence for a Mechanism Involving VEGF Signaling and the Extracellular Matrix* (Gollmann-Tepeköylü et al., 2018)

Cardiac Surgery Medical University of Innsbruck Austria.

Background Mechanical stimulation of acute ischemic myocardium by shock wave therapy (SWT) is known to improve cardiac function by induction of angiogenesis. However, SWT in chronic heart failure is poorly understood. We aimed to study whether mechanical stimulation upon SWT improves heart function in chronic ischemic heart failure by induction of angiogenesis and postnatal vasculogenesis and to dissect underlying mechanisms. Methods and Results SWT was applied in a mouse model of chronic myocardial ischemia. To study effects of SWT on postnatal vasculogenesis, wild-type mice



received bone marrow transplantation from green fluorescence protein donor mice. Underlying mechanisms were elucidated in vitro in endothelial cells and murine aortic rings. Echocardiography and pressure/volume measurements revealed improved left ventricular ejection fraction, myocardial contractility, and diastolic function and decreased myocardial fibrosis after treatment. Concomitantly, numbers of capillaries and arterioles were increased. SWT resulted in enhanced expression of the chemoattractant stromal cell-derived factor 1 in ischemic myocardium and serum. Treatment induced recruitment of bone marrow-derived endothelial cells to the site of injury. In vitro, SWT resulted in endothelial cell proliferation, enhanced survival, and capillary sprouting. The effects were vascular endothelial growth factor receptor 2 and heparan sulfate proteoglycan dependent. Conclusions SWT positively affects heart function in chronic ischemic heart failure by induction of angiogenesis and postnatal vasculogenesis. SWT upregulated pivotal angiogenic and vasculogenic factors in the myocardium in vivo and induced proliferative and anti-apoptotic effects on endothelial cells in vitro. Mechanistically, these effects depend on vascular endothelial growth factor signaling and heparan sulfate proteoglycans. SWT is a promising treatment option for regeneration of ischemic myocardium.

Study Performance: **orthogold180c** with applicator CG050-P

10.9. *Shock Wave Treatment After Hindlimb Ischaemia Results in Increased Perfusion and M2 Macrophage Presence* (Tepeköylü et al., 2018)

University Hospital for Cardiac Surgery, Innsbruck Medical University, Austria.

Shock wave therapy (SWT) has been shown to induce angiogenesis in ischemic muscle. However, the mechanism of action remains unknown. Macrophages are crucial for angiogenic responses after ischemic injury. The M2 macrophage subset enables tissue repair and induces angiogenesis. It was hypothesized that the angiogenic effects of SWT are at least partly caused by enhanced macrophage recruitment. C57BL/6 mice were subjected to hind limb ischemia with subsequent SWT or sham treatment. Muscles were analyzed via immunofluorescence staining, reverse-transcription polymerase chain reaction and western blot. Gene expression and proteins involved in macrophage recruitment were analyzed and tissue sections were stained for macrophages, including subsets, capillaries and arterioles. Laser Doppler perfusion imaging was performed to assess functional outcome. Treated muscles showed increased expression of the pivotal macrophage recruiting factor monocyte chemoattractant protein 1 (MCP-1). Higher levels of macrophage marker CD14 were found. Increased numbers of macrophages after SWT could be confirmed by immunofluorescence staining. The expression of the M2 polarization promoting chemokine interleukin 13 was significantly elevated in the treatment group. Elevated mRNA expression of the M2 scavenger receptor CD163 was found after SWT. Immunofluorescence staining confirmed increased numbers of M2 macrophages after treatment. It was found that SWT resulted in higher number of capillaries and arterioles. Assessment of functional outcome revealed significantly improved limb perfusion in treated animals. Shock wave therapy causes increased macrophage recruitment and enhanced polarization towards reparative M2 macrophages in ischemic muscle resulting in angiogenesis and improved limb perfusion and therefore represents a promising new treatment option for the treatment of ischemic heart disease.

Study Performance: **orthogold180c** with applicator CG050-P

10.10. *Shockwaves Prevent from Heart Failure After Acute Myocardial Ischaemia via RNA/Protein Complexes* (Tepeköylü et al., 2017)

Department for Cardiac Surgery, Medical University of Innsbruck, Innsbruck, Austria.

Shock wave treatment (SWT) was shown to induce regeneration of ischemic myocardium via Toll-like receptor 3 (TLR3). The antimicrobial peptide LL37 gets released by mechanical stress and is known to form complexes with nucleic acids thus activating Toll-like receptors. We suggested that SWT in the acute setting prevents from the development of heart failure via RNA/protein release. Myocardial infarction in mice was induced followed by subsequent SWT. Heart function was assessed 4 weeks later via transthoracic echocardiography and pressure-volume measurements. Human umbilical vein endothelial cells (HUVECs) were treated with SWT in the presence of RNase and proteinase and analysed for proliferation, tube formation and LL37 expression. RNA release and uptake after SWT was evaluated. We found significantly improved cardiac function after SWT. SWT resulted in significantly higher numbers of capillaries and arterioles and less left ventricular fibrosis. Supernatants of treated cells activated TLR3 reporter cells. Analysis of the supernatant revealed increased RNA levels. The effect could not be abolished by pre-treatment of the supernatant with RNase, but only by a sequential digestion with proteinase and RNase hinting strongly towards the involvement of RNA/protein complexes. Indeed, LL37 expression as well as cellular RNA uptake were significantly increased after SWT. We show for the first time that SWT prevents from left ventricular remodeling and cardiac dysfunction via RNA/protein complex release and subsequent induction of angiogenesis. It might therefore develop a potent regenerative treatment alternative for ischemic heart disease.

Study Performance: **orthogold180c** with applicator CG050-P

10.11. *Shock Waves Induce Angiogenesis via Exosome Release (Graber et al., 2017)*

Medical university of Innsbruck, Department of Cardiac Surgery.

Introduction: The mechanism of mechanotransduction of shock wave therapy (SWT) remains unknown. We hypothesized that SWT induces exosome release and thus exerts its angiogenic effects.

Material and Method: Human umbilical vein endothelial cells (HUVECs) were treated with SWT. Exosomes were isolated from the supernatant and analyzed by nanoparticle tracking analysis. The angiogenic potential was analyzed in vitro and exosomes were injected into subcutaneously implanted matrigel plugs in nude mice. Perfusion of the plugs was measured via Laser Doppler perfusion imaging (LDPI) and quantified histologically.

Results: Supernatants of treated HUVECs showed significantly higher concentrations of exosomes. Released exosomes enhanced tube formation and endothelial cell proliferation. Exosome-release inhibitor GW4869 abolished the angiogenic effects of SWT. Injection of exosomes into subcutaneously implanted matrigel plugs resulted in higher perfusion and increased number of capillaries and arterioles.

Discussion: We show for the first time how the mechanical stimulus of SWT is translated into a biological response. SWT causes exosome release which have and highly angiogenic potential in vitro and in vivo.

Conclusion: Exosomes released by SWT might develop a therapeutic treatment option for ischemic heart disease.

20th International Congress of the ISMST 2017 in San Sebastian, Spain, Abstract P25.

Study Performance: **orthogold180C** with applicator CP050

10.12. *Elucidating the Molecular Mechanisms Underlying Cardiac Shock Wave Therapy (Szwarc D., Fuchs C. et al., 2017)*



Department of Biochemical Engineering, University of Applied Sciences Technikum Wien, Vienna, Austria.

Introduction: Despite the existence of established therapy strategies for coronary heart disease, the incidence of death is predicted to keep rising. Therefore, substitute methods are pursued

Material and Methods: Cardiac SWT may offer a non-invasive alternative, yet the molecular mechanisms of its efficacy in the heart remain unknown. Murine embryonic stem cells (ESCs)- and cardiovascular progenitor cell (CVPCs)-30 models were subjected to SWT of 0.4-0.13 mJ/mm² using a Dermagold100 device (MTS). Intracellular signaling was assessed with Western blot and the differentiation into the cardiac lineage was determined with qPCR.

Results: We observed a dose-dependent activation of ERK1/2 immediately after SWT in both cell types, consistent with previously shown results. No effect on the mTOR and PI3K pathways was visible up to 6 hours post SWT. A higher expression of the mesodermal marker Brachyury and the early cardiac marker Nkx2.5 was shown in mESCs following SWT, compared to controls. In contrast, no clear effect of SWT could be observed in CVPCs.

Discussion: Our studies aim to justify the use of SWT in the therapy of patients who suffered from myocardial infarction. We could confirm the transduction of the mechanical signal triggered by SWT within the cell, which could potentially underlie the altered transcription of certain genes. Despite obvious trends visible in gene expression profile, the superiority of certain treatment regimens over others remains unclear. The lack of conclusive evidence that SWT affects differentiation of committed cells points to a different putative mechanism affecting the heart cells and leading to their regeneration.

Conclusion: All in all, SWT of the postischemic myocardium could contribute to its regeneration by improving differentiation of circulating stem cells, yet other mechanisms cannot be excluded.

20th International Congress of the ISMST 2017 in San Sebastian, Spain, Abstract P28.

Study Performance: **dermagold100**

10.13. Shock Waves Induce Angiogenesis via Exosome Release (Tepeköylü C., ... Holfeld J. et al., 2016)

Department of Cardiac Surgery, Innsbruck Medical University, Innsbruck, Austria.

Background: Shock wave therapy (SWT) is developing a promising approach for the regeneration of ischemic myocardium by induction of angiogenesis. However, the mechanism of action remains unknown. Exosomes are released by mechanical shear stress and have been shown to induce angiogenic effects. We hypothesized that SWT induces exosome release and thus exerts its angiogenic effects.

Methods: Human umbilical vein endothelial cells (HUVECs) were treated with SWT. Subsequently, exosomes were isolated from the supernatant and analyzed by transmission electron microscopy (TEM) and nanoparticle tracking analysis. In a next step, exosomes were characterized and analyzed for their angiogenic potential in vitro. Exosome content was evaluated via a sequencing array. Finally, isolated exosomes were injected into subcutaneously implanted matrigel plugs in nude mice. Perfusion of the plugs was measured via Laser Doppler perfusion imaging (LDPI). Arterioles and capillaries were quantified histologically. In vivo imaging was performed to analyze functionality of the vessels.

Results: SWT caused exosome release in HUVECs. Supernatants of treated cells showed significantly higher concentrations of exosomes. Exosomes showed a characteristic cup shaped morphology in TEM analysis. Treatment of HUVECs with exosomes induced phosphorylation of Akt and ERK, caused increased tube formation (CTR $19,5 \pm 7,79$ vs. SWT $178,5 \pm 31,14$, $p=0,004$) and endothelial cell proliferation (CTR $0,59 \pm 0,02$ vs. SWT $0,77 \pm 0,04$, $p=0,011$). Pre-treatment with exosome-release inhibitor GW4869 abolished the angiogenic effects of SWT. Sequencing array showed the presence of angiogenic miRNAs in exosomes released after SWT. Injection of isolated exosomes into subcutaneously implanted matrigel plugs resulted in higher perfusion and increased number of capillaries (CTR $0,53 \pm 0,19$ vs. SWT $1,7 \pm 0,26$, $p=0,0006$) and arterioles (CTR $0,8 \pm 0,23$ vs. SWT $4,5 \pm 0,54$, $p<0,0001$). In vivo imaging of the matrigel plugs showed formation of functional vessels after exosome injection.

Conclusion: We show for the first time how the mechanical stimulus of SWT is translated into a biological response. SWT causes exosome release. Released exosomes show a very potent angiogenic effect. SWT might develop a potent therapeutic intervention for the treatment of ischemic heart disease.

4th ISMST Basic Research Meeting, 2016 in Vienna, Austria.

Study Performance: orthogold180C with applicator CP050

10.14. *Toll-Like Receptor 3 Signalling Mediates Angiogenic Response Upon Shock Wave Treatment of Ischaemic Muscle* (Holfeld, Tepeköylü, et al., 2016)

Department of Cardiac Surgery, Innsbruck Medical University, Innsbruck, Austria.

Aims: Shock wave therapy (SWT) represents a clinically widely used angiogenic and thus regenerative approach for the treatment of ischaemic heart or limb disease. Despite promising results in preclinical and clinical trials, the exact mechanism of action remains unknown. Toll-like receptor 3, which is part of the innate immunity, is activated by binding double-stranded (ds) RNA. It plays a key role in inflammation, a process that is needed also for angiogenesis. We hypothesize that SWT causes cellular cavitation without damaging the target cells, thus liberating cytoplasmic RNA that in turn activates TLR3.

Methods and results: SWT induces TLR3 and IFN- β 1 gene expression as well as RNA liberation from endothelial cells in a time-dependent manner. Conditioned medium from SWT-treated HUVECs induced TLR3 signaling in reporter cells. The response was lost when the medium was treated with RNase III to abolish dsRNAs or when TLR3 was silenced using siRNAs. In a mouse hind limb ischemia model using wt and TLR3(-/-) mice ($n = 6$), SWT induced angiogenesis and arteriogenesis only in wt animals. These effects were accompanied by improved blood perfusion of treated limbs. Analysis of main molecules of the TLR3 pathways confirmed TLR3 signaling in vivo following SWT.

Conclusion: Our data reveal a central role of the innate immune system, namely Toll-like receptor 3, to mediate angiogenesis upon release of cytoplasmic RNAs by mechanotransduction of SWT.

Study Performance: orthogold180c with applicator CG050-P

10.15. *Antimicrobial Peptide LL37/RNA Complexes Stimulate Toll-Like Receptor 3 Upon Shock Wave Therapy* (Graber et al., 2016)

Department of Cardiac Surgery, Innsbruck Medical University, Innsbruck, Austria.



Background: Shock wave therapy (SWT) induces angiogenesis in ischemic heart disease. It is mediated via Toll-like receptor 3 (TLR3), an endosomal receptor of the innate immune system recognizing RNA. How TLR3 is activated upon SWT remains unknown. The antimicrobial peptide LL37 has been shown to be released after mechanical stress and to form complexes with RNA.

Purpose: We hypothesized that mechanical stimulation upon SWT leads to LL37 release, which forms complexes with RNA and leads to activation of endosomal TLR3.

Methods: Supernatant of treated human umbilical vein endothelial cells (HUVEC) was transferred onto TLR3 reporter cells and TLR3 activation was measured. To find out whether protein/RNA complexes play a role after SWT, supernatants were treated with RNase and proteinase. Treated HUVECs were analyzed for LL37 expression. To investigate the uptake of LL37/RNA complexes, premarket TNA was added to cells prior to treatment and uptake was tracked. C57BL/6 mice were subjected to acute myocardial infarction and subsequently treated with SWT. Echocardiography and pressure volume measurements were performed to evaluate cardiac function. Histological quantification of vessels and assessment of fibrosis was performed.

Results: Supernatants of treated cells activated TLR3 reporter cells (CTR $7.346 \pm 2,173$ vs. SWT 146.005 ± 12.508 ; $p < 0.0001$). Analysis of the supernatant revealed increased RNA levels (CTR 21 ± 2.444 vs. SWT $37 \pm 1,5$; $p < 0,0174$). The effect could not be abolished by pretreatment of the supernatant with RNase hinting strongly towards the involvement of protein/RNA complexes. Indeed, LL37 expression was significantly increased after SWT. Pre-marked RNA was added to HUVECs, followed by subsequent SWT. Cellular RNA uptake was significantly increased after SWT (CTR $31.67 \pm 28,17$ vs. SWT 19757 ± 1054 ; $p < 0.0001$). Finally, SWT resulted in significantly higher numbers of capillaries (SWT 1262 vs CTR 461; $p < 0.001$) and arterioles (SWT 461 vs. CTR 160.5; $p < 0,001$), decreased fibrosis (CTR $\pm 2,76$ vs. SWT $8,97 \pm 3,08$; $p < 0,01$) and improved ejection fraction (CTR 35.25 ± 1.11 vs. SWT 46 ± 2.83 ; $p < 0.01$) in treated hearts.

Conclusion: TLR3 activation upon SWT is mediated via the release of LL37. The antimicrobial peptide forms complexed with extracellular RNA and can thus stimulate endosomal TLR3. SWT subsequently induces angiogenesis in ischemic myocardium and might therefore develop a potent regenerative treatment alternative for ischemic heart disease.

4th ISMST Basic Research Meeting in Vienna, Austria.

Study Performance: **orthogold180c** with applicator CG050-P

10.16. *Epicardial Shock-Wave Therapy Improves Ventricular Function in a Porcine Model of Ischaemic Heart Disease* (Holfeld, Zimpfer, et al., 2016)

Department of Cardiac Surgery, Innsbruck Medical University, Innsbruck, Austria.

Previously we have shown that epicardial shock-wave therapy improves left ventricular ejection fraction (LVEF) in a rat model of myocardial infarction. In the present experiments we aimed to address the safety and efficacy of epicardial shock-wave therapy in a preclinical large animal model and to further evaluate mechanisms of action of this novel therapy. Four weeks after left anterior descending (LAD) artery ligation in pigs, the animals underwent re-thoracotomy with (shock-wave group, $n = 6$) or without (control group, $n = 5$) epicardial shock waves (300 impulses at 0.38 mJ/mm^2) applied to the infarcted anterior wall. Efficacy endpoints were improvement of LVEF and induction of angiogenesis 6 weeks after shock-wave therapy. Safety endpoints were hemodynamic stability during treatment and myocardial damage. Four weeks after LAD ligation, LVEF decreased in both the shock-wave ($43 \pm 3\%$, $p < 0.001$) and control ($41 \pm 4\%$, $p = 0.012$) groups. LVEF markedly improved in shock-wave animals 6 weeks after treatment ($62 \pm 9\%$, $p = 0.006$); no improvement was observed in controls ($41 \pm 4\%$, $p =$

0.36), yielding a significant difference. Quantitative histology revealed significant angiogenesis 6 weeks after treatment (controls 2 ± 0.4 arterioles/high-power field vs treatment group 9 ± 3 ; $p = 0.004$). No acute or chronic adverse effects were observed. As a potential mechanism of action *in vitro* experiments showed stimulation of VEGF receptors after shock-wave treatment in human coronary artery endothelial cells. Epicardial shock-wave treatment in a large animal model of ischemic heart failure exerted a positive effect on LVEF improvement and did not show any adverse effects. Angiogenesis was induced by stimulation of VEGF receptors.

Study Performance: **orthogold180c** with applicator CG050-P

10.17. *The Beneficial Effects of In Vitro Shock Wave Treatment on Cardiomyogenesis are Energy Dependent (Fuchs C., Weihs A. M. et al., 2016)*

University of Applied Sciences Technikum Wien, Vienna, Austria.

Introduction: Recently, the cellular effects of shock wave treatment have been thoroughly studied using *in vitro* approaches. We already described intracellular pathways involved in the shock wave treatment effect using the *in vitro* shock wave treatment (IVSWT) water bath set-up and various cell types. We suppose that the beneficial cellular effects of shock waves – such as increased proliferation or enhanced growth factor expression – could also be exploited in the emerging field of tissue engineering. The adaptation of *in vitro* shock wave treatment parameters for the application on 3D cell culture systems and cell/scaffold constructs would therefore provide a promising tool for tissue engineering purposes.

Methods: Several three-dimensional cell culture systems such as spheroids of stem cells, various cell-loaded hydrogels and scaffolds, were subjected to *in vitro* shock wave treatment.

Results: Diverse protocols were developed and tested to establish optimal treatment set-ups and parameters, e.g. stiffness of the used scaffolds, medium density as well as optimal number of shock wave treatments were evaluated in order to find the optimal conditions for diverse 3D systems.

Discussion: The potential of shock wave treatment to trigger mechanosensitive pathways can be used to improve proliferation or differentiation in 3D systems *in vitro* in order to support scaffold maturation and ultimately enhance cell-scaffold performance. Thus, the experience on the application of shock waves on 3D cell culture systems and scaffolds will help to establish shock wave treatment as a potent tool in the field of tissue engineering and regenerative medicine.

4th ISMST Basic Research Meeting, 2016 in Vienna, Austria.

Study Performance: **dermagold100** with applicator OP155

10.18. *Low-Energy Shock Waves Treatment Induces Angiogenesis in Ischemic Muscle by Stimulation of Toll-Like Receptor 3 Signalling (Holfeld J., Tepeköylü C et al., 2016)*

Department of Cardiac Surgery, Medical University Innsbruck.

Background: Low energy shock waves (SW) have been shown to induce angiogenesis in ischemic myocardium. The mechanism translating the physical stimulus to a biological signal is unknown. Toll-like receptor (TLR)-3 is activated by RNA binding. It plays a key role in inflammation and angiogenesis. We therefore hypothesized that SW cause cellular cavitation, thus liberating cytoplasmic mRNA that activates TLR-3 as does the specific agonist Poly I:C. Effects are suppressed in TLR-3 silenced cells and in TLR-3 knock out mice.



Methods: The effect of SW was tested in human umbilical vein endothelial cells (HUVECs): untreated (control) vs. SW treated (SW group) vs. treated with 200 µg/ml Poly I:C (agonist). TLR-3 gene silencing was done with siRNA. Hind limb ischemia was performed in wild type and TLR-3 knock-out mice. Expression of mRNA and proteins of the TLR-3 signaling pathway as well as typical angiogenic genes and proteins were measured. Laser Doppler perfusion imaging and necrosis score were assessed for clinical outcome evaluation (n=6).

Results: Shock wave treatment of HUVECs shows increase of mRNA expression (% of control) as does Poly I:C after 2 hours: TLR-3 (SW group 123.8 ± 8.0 and agonist group 237.7 ± 14.1 , $p < 0.0001$), Tie-2 (SW group 154.3 ± 20.0 and agonist 125.7 ± 12.3 , $p < 0.008$).

TLR-3 gene silencing in SW treated HUVECs causes loss of response for TLR-3 mRNA (107.0 ± 13.3) as compared to SW group (378.3 ± 14.2) or agonist (1261 ± 72.1), both $p < 0.0001$.

SW treated TLR-3 knock-out mice showed no improvement of perfusion ratio 4 weeks after hind limb ischemia (0.52 ± 0.07 vs. 0.53 ± 0.02 controls, $p > 0.05$), whereas SW treated wild type animals improved significantly (0.78 ± 0.03 vs. 0.48 ± 0.08 controls, $p = 0.015$). Pro angiogenic genes and proteins were up-regulated significantly. All known TLR-3 signaling pathways were involved as shown by significant increase of key proteins Trif, TRAF6 and IRF3.

Conclusion: Low energy shock waves induce angiogenesis in ischemic muscle by stimulation of Toll-like receptor 3 signaling in endothelial cells. Effects are suppressed in TLR-3 silenced cells and in TLR-3 knock-out mice.

4th ISMST Basic Research Meeting, 2016 in Vienna, Austria.

Study Performance: orthogold180C with applicator CP050

10.19. Shock Wave Therapy Causes Increased Macrophage Recruitment and Enhances M2 Polarization (Nägele F., Graber M., ...Tepeköylü C., Holfeld J., 2016)

Department of Cardiac Surgery, Medical University Innsbruck.

Objective

Shock wave therapy (SWT) has been shown to induce angiogenesis in ischemic muscle. However, the mechanism of action remains unknown. Macrophages are crucial for angiogenic responses after ischemia. Proinflammatory M1 macrophages phagocytize necrotic tissue. M2 macrophages create a milieu of regeneration and enable angiogenesis. We hypothesized that the angiogenic effects of SWT are caused by enhanced macrophage recruitment.

Methods

C57BL/6 mice were subjected to unilateral hind limb ischemia with subsequent SWT (0,1mJ/mm², 500 Impulses, 5 Hz) or sham treatment. Successful limb ischemia was confirmed via Laser Doppler perfusion imaging. Gastrocnemius muscle was harvested 72h and 28d after ischemia induction and further processed for immunofluorescence staining and RT-PCR analysis.

Results

Treated muscles show increased expression of the pivotal recruiting factor monocyte chemoattractant protein 1 (MCP-1) ($217,9 \pm 30,18$ vs. $102,7 \pm 14,08$, $p = 0,0016$). Indeed, an increase of the macrophage marker CD14 could be observed after SWT ($118,1 \pm 20,9$ vs. $22,16 \pm 2,874$, $p = 0,0001$). The higher numbers of macrophages could be confirmed in immunofluorescence stainings. The expression of the M2 polarization promoting chemokine IL-13 was significantly increased in the treatment group ($517.7 \pm 81,83$ vs. 3087 ± 1043 , $p = 0,0138$). Increased levels of the M2 scavenger receptor CD163 could be found after SWT compared to untreated controls ($172,4 \pm 35,84$ vs. $40,56 \pm 6,266$, $p = 0,0008$). We found higher numbers of capillaries (CTR 8.18 ± 1.9 vs. SWT 16.25 ± 2.09 ,

p=0.009) and arterioles (CTR 1.11 ± 0.26 vs. SWT 3.78 ± 0.52 , p=0.0003) after SWT. Treated animals showed significantly improved limb perfusion (CTR 0.45 ± 0.67 vs. SWT 0.76 ± 0.09 , p=0.027).

Conclusion

SWT causes increased macrophage recruitment and enhanced polarization towards reparative M2 macrophages in ischemic muscle. It could therefore become a promising tool for the regeneration of ischemic myocardium.

4th ISMST Basic Research Meeting, 2016 in Vienna, Austria.

Study Performance: **orthogold180C** with applicator CP050

10.20. *Effect of Shock Waves on Macrophages: A Possible Role in Tissue Regeneration and Remodeling* (Sukubo et al., 2015)

Humanitas Clinical and Research Center, Rozzano, Milan, Italy; Department of Medical Biotechnologies and Translational Medicine, University of Milan, Milan, Italy.

Introduction: Extracorporeal Shock Wave Therapy (ESWT) is broadly used as a non-surgical therapy in various diseases for its pro-angiogenic and anti-inflammatory effects. However, the molecular mechanisms translating tissue exposure to shock waves (SW) in a biological response with potential therapeutic activity are largely unknown. As macrophages take part in both the onset and amplification of the inflammatory response, and well in its resolution, we investigated the effect of SW on their biology.

Methods: Human monocyte-derived macrophages were polarized to classic (M1) pro-inflammatory macrophages or alternative (M2) anti-inflammatory macrophages and exposed to SW at different intensities. Expression levels of marker genes of macrophage activation were measured by qPCR at different time points.

Results: SW did not induce activation of resting macrophages at any energy level used. Conversely, when used at low energy SW caused a significant inhibition of some M1 marker genes (CD80, COX2, CCL5) in M1 macrophages and a significant synergistic effect for some M2 marker genes (ALOX15, MRC1, CCL18) in M2 macrophages. SW also affected cytokine and chemokine production, inducing in particular a significant increase in IL-10 and reduction in IL-1 β production.

Conclusions: Macrophage exposure to low energy SW dampens the induction of the pro-inflammatory profile characterizing M1 macrophages and promotes the acquisition of an anti-inflammatory profile synergizing with macrophage alternative activation.

Study Performance: **orthogold100** with applicator OP155

10.21. *Shockwave Treatment Promotes the Expression of Alox15 in Pro-Resolving Macrophages* (Sukubo et al., 2014) (Sukubo et al., 2015)

Dept. of Medical Biotechnologies and Translational Medicine, University of Milan, Italy.

Introduction: Extracorporeal Shock Wave (SW) treatment is broadly used as a nonsurgical therapy in various diseases, demonstrating its pro-angiogenic and anti-inflammatory effects. However, the molecular mechanisms translating shock waves in a biological response with potential therapeutic activity are largely unknown. As macrophages take part in both the onset and amplification of the inflammatory response, and well in its resolution, we investigated the effect of SWT on their biology.

Methods: Human monocyte-derived macrophages were polarized to pro-inflammatory classic macrophages (M1) by over-night exposure to LPS+IFN or anti-inflammatory alternative macrophages



(M2) by overnight exposure to IL-4. Using an Orthogold100 device as electrohydraulic SW source, macrophages were then exposed in a thermostated water bath to SW (400 impulses, 3.5Hz, 0.1-0.03 mJ/mm²) at different time points. RNA was then extracted and expression levels of M1 (CD80, CCL5, CXCL9, CXCL10, COX2) and M2 (CD206, ALOX15, IL-10, TGF β) genes were analyzed by qRT-PCR.

Results: SW had no direct effect on any transcript investigated, when applied to resting macrophages. Though the effect did not reach statistical significance for the elevated variability among different experiments, when applied to inflammatory macrophages SW showed a faint downmodulatory effect on some M1 markers (CCL5, CD80), while others (including COX2) were not affected. Conversely, at low energy level (0.03 mJ/mm²) SW had a significant reproducible and time-dependent synergistic effect with IL-4 for the induction of ALOX15 in M2 macrophages. Interestingly, other M2 genes (including IL-10) were not affected by SW exposure.

Discussion: Synergism with IL-4 in the induction of some M2 genes, suggesting that SW therapeutic potential may be at least in part mediated by their effect on macrophage biology.

Conclusion: Our results demonstrate that SW at low energy level act in conclusion, we did not detect any synergistic effect of SW on the anti-inflammatory cytokine IL-10, but we identified ALOX15 as a SW-responsive gene in M2 macrophages. ALOX15 has a key role in the resolution of the inflammatory response via production of the proresolving eicosanoid lipoxin A4 and of endogenous agonists of the PPAR γ pathway and could therefore be involved in the therapeutic effects observed after exposure to SW.

17th ISMST Congress Milano, Italy. Abstract No. 5.

Study Performance: **orthogold100**

10.22. *Alteration of Inflammatory Response by Shock Wave Therapy Leads to Reduced Calcification of Decellularized Aortic Xenografts in Mice* (Tepeköylü et al., 2015)

University Hospital for Cardiac Surgery, Medical University of Innsbruck, Innsbruck, Austria Division of Clinical and Functional Anatomy, Department of Anatomy, Histology and Embryology, Medical University of Innsbruck, Innsbruck, Austria.

Objectives: Tissue-engineered xenografts represent a promising treatment option in heart valve disease. However, inflammatory response leading to graft failure and incomplete in vitro repopulation with recipient cells remain challenging. Shock waves (SWs) were shown to modulate inflammation and to enhance re-epithelialization. We therefore aimed to investigate whether SWs could serve as a feasible adjunct to tissue engineering.

Methods: Porcine aortic pieces were decellularized using sodium deoxycholate and sodium dodecylsulphate and implanted subcutaneously into C57BL/6 mice (n = 6 per group). The treatment (shock wave therapy, SWT) group received SWs (0.1 mJ/mm², 500 impulses, 5 Hz) for modulation of inflammatory response directly after implantation; control animals remained untreated (CTR). Grafts were harvested 72 h and 3 weeks after implantation and analyzed for inflammatory cytokines, macrophage infiltration and polarization, osteoclastic activity and calcification. Transmission electron microscopy (TEM) was performed. Endothelial cells (ECs) were treated with SWs and analyzed for macrophage regulatory cytokines. In an ex vivo experimental set-up, decellularized porcine aortic valve conduits were reseeded with ECs with and without SWT (0.1 mJ/mm², 300 impulses, 3 Hz), fibroblasts as well as peripheral blood mononuclear cells (all human) and tested in a pulsatile flow perfusion system for cell coverage.

Results: Treated ECs showed an increase of macrophage migration inhibitory factor and macrophage inflammatory protein 1 β , whereas CD40 ligand and complement component C5/C5a were decreased.

Subcutaneously implanted grafts showed increased mRNA levels of tumor necrosis factor α and interleukin 6 in the treatment group. Enhanced repopulation with recipient cells could be observed after SWT. Augmented macrophage infiltration and increased polarization towards M2 macrophages was observed in treated animals. Enhanced recruitment of osteoclastic cells in proximity to calcified tissue was found after SWT. Consequently, SWT resulted in decreased areas of calcification in treated animals. The reseeding experiment revealed that fibroblasts showed the best coverage compared with other cell types. Moreover, SW-treated ECs exhibited enhanced repopulation compared with untreated controls.

Conclusions: SWs reduce the calcification of subcutaneously implanted decellularized xenografts via the modulation of the acute macrophage-mediated inflammatory response and improves the in vitro repopulation of decellularized grafts. It may therefore serve as a feasible adjunct to heart valve tissue engineering.

Study Performance: **orthogold180c** with applicator CG050-P

10.23. *Low Energy Shock Wave Therapy Induces Angiogenesis in Acute Hind-Limb Ischemia via VEGF Receptor 2 Phosphorylation* (Holfeld, Tepekoylu, et al., 2014)

University Hospital for Cardiac Surgery, Innsbruck Medical University, Innsbruck, Austria.

Objectives: Low energy shock waves have been shown to induce angiogenesis, improve left ventricular ejection fraction and decrease angina symptoms in patients suffering from chronic ischemic heart disease. Whether there is as well an effect in acute ischemia was not yet investigated.

Methods: Hind-limb ischemia was induced in 10-12 weeks old male C57/Bl6 wild-type mice by excision of the left femoral artery. Animals were randomly divided in a treatment group (SWT, 300 shock waves at 0.1 mJ/mm², 5 Hz) and untreated controls (CTR), n = 10 per group. The treatment group received shock wave therapy immediately after surgery.

Results: Higher gene expression and protein levels of angiogenic factors VEGF-A and PlGF, as well as their receptors Flt-1 and KDR have been found. This resulted in significantly more vessels per high-power field in SWT compared to controls. Improvement of blood perfusion in treatment animals was confirmed by laser Doppler perfusion imaging. Receptor tyrosine kinase profiler revealed significant phosphorylation of VEGF receptor 2 as an underlying mechanism of action. The effect of VEGF signaling was abolished upon incubation with a VEGFR2 inhibitor indicating that the effect is indeed VEGFR 2 dependent.

Conclusions: Low energy shock wave treatment induces angiogenesis in acute ischemia via VEGF receptor 2 stimulation and shows the same promising effects as known from chronic myocardial ischemia. It may therefore develop as an adjunct to the treatment armamentarium of acute muscle ischemia in limbs and myocardium.

Study Performance: **orthogold100** device with applicator CP050

10.24. *Shockwave Therapy Differentially Stimulates Endothelial Cells: Implications on the Control of Inflammation via Toll-Like Receptor 3* (Holfeld, Tepeköylü, Kozaryn, Urbschat, et al., 2014)

University Hospital for Cardiac Surgery, Innsbruck Medical University, Innsbruck, Austria.

Shock wave therapy (SWT) reportedly improves ventricular function in ischemic heart failure. Angiogenesis and inflammation modulatory effects were described. However, the mechanism remains largely unknown. We hypothesized that SWT modulates inflammation via toll-like receptor 3 (TLR3)



through the release of cytosolic RNA. SWT was applied to human umbilical vein endothelial cells (HUVECs) with 250 impulses, 0.08 mJ/mm² and 3 Hz. Gene expression of TLR3, inflammatory genes and signalling molecules was analysed at different time points by real-time polymerase chain reaction. SWT showed activation of HUVECs: enhanced expression of TLR3 and of the transporter protein for nucleic acids cyclophilin B, of pro-inflammatory cytokines cyclophilin A and interleukin-6 and of anti-inflammatory interleukin-10. No changes were found in the expression of vascular endothelial cell adhesion molecule. SWT modulates inflammation via the TLR3 pathway. The interaction between interleukin (IL)-6 and IL-10 in TLR3 stimulation can be schematically seen as a three-phase regulation over time.

Study Performance: **orthogold180c** with applicator CG050-P

10.25. *Molecular and Cellular Effects of In Vitro Shockwave Treatment on Lymphatic Endothelial Cells* (Rohringer et al., 2014)

Ludwig Boltzmann Institute for Experimental and Clinical Traumatology, Donaueschingenstrasse 13, Vienna, Austria; Austrian Cluster for Tissue Regeneration, Vienna, Austria.

Extracorporeal shockwave treatment was shown to improve orthopedic diseases and wound healing and to stimulate lymphangiogenesis in vivo. The aim of this study was to investigate in vitro shockwave treatment (IVSWT) effects on lymphatic endothelial cell (LEC) behavior and lymphangiogenesis. We analyzed migration, proliferation, vascular tube forming capability and marker expression changes of LECs after IVSWT compared with HUVECs. Finally, transcriptome- and miRNA analyses were conducted to gain deeper insight into the IVSWT-induced molecular mechanisms in LECs. The results indicate that IVSWT-mediated proliferation changes of LECs are highly energy flux density-dependent and LEC 2D as well as 3D migration was enhanced through IVSWT. IVSWT suppressed HUVEC 3D migration but enhanced vasculogenesis. Furthermore, we identified podoplaninhigh and podoplaninlow cell subpopulations, whose ratios changed upon IVSWT treatment. Transcriptome- and miRNA analyses on these populations showed differences in genes specific for signaling and vascular tissue. Our findings help to understand the cellular and molecular mechanisms underlying shockwave-induced lymphangiogenesis in vivo.

Study Performance: **dermagold100** with applicator OP155

10.26. *Shockwaves Induce Postnatal Vasculogenesis in infarcted Myocardium by Recruitment of Bone Marrow Derived Endothelial Progenitors* (Holfeld et al., 2014)

Medical University; Innsbruck; Austria.

Introduction: Recently shock waves at low energy levels were described to induce angiogenesis and regeneration in ischemic tissue. Improvement of myocardial perfusion and relief of angina symptoms in human patients with severe coronary artery disease have been shown. We hypothesized that the recruitment of progenitor cells from bone marrow to infarcted myocardium may be involved as well.

Methods: Sub-lethally irradiated C57Bl/6 wild-type mice received bone marrow transplantation (BmTx) from transgenic GFP mice (C57BL/6Tg (CAG-EGFP)10sb/J) (n=6 per group). 4 weeks after BmTx, myocardial infarction was induced by LAD ligation. Treatment group (SWT) received shock wave therapy (0.38mJ/mm², 200 impulses, 3Hz) 3 weeks after infarction, whereas control animals (CTR) underwent sham treatment. Hearts were harvested 3 weeks after therapy. GFP positive bone marrow

derived cells in the heart were detected by immunofluorescence microscopy. Lectin counterstaining revealed endothelial progenitor cells (EPCs). Gene expression of pivotal factors SDF-1, CXCR4, VEGF receptors and others was performed. Functional outcome was measured with a pressure catheter inserted into the left ventricle. For further mechanistic findings an in-vitro migration assay using human umbilical vein endothelial cells (HUVECs) was performed.

Results: Higher numbers of bone marrow derived endothelial progenitor cells per high power field have been found in the treatment group (CTR 3.98 ± 0.6 vs. SWT 17.89 ± 1.6 , $p < 0.0001$). The main chemoattractant for EPC recruitment SDF-1 mRNA, was increased (CTR 1.86 ± 0.68 vs. SWT 5.19 ± 1.18 , $p = 0.02$). Migration assay revealed higher migration rates (CTR 171.9 ± 15.89 vs. SWT 234.5 ± 25.9 , $p = 0.04$). Functional outcome as assessed by pressure catheter showed an increase in dPdtmax (CTR 1957 ± 343 vs. SWT 3007 ± 617.4 , $p > 0.059$), a decrease in dPdtmin (CTR -1532 ± 251.3 vs. SWT -2603 ± 346.7 , $p = 0.03$) and an increase in Tau (CTR 33.68 ± 5.99 vs. SWT 124.7 ± 42.15 , $p = 0.09$) indicating functional improvement after SWT.

Discussion: Low energy shock waves induce postnatal vasculogenesis in infarcted myocardium by the recruitment of bone marrow derived endothelial progenitor cells. **Conclusion:** Shock wave treatment may develop a regenerative adjunct or alternative treatment option to state of the art revascularization in myocardial infarction. Notably, it has already been applied in angina patients without causing any severe side effects.

17th International Congress of the ISMST 2014 in Milano, Italy. Abstract No. 56.

Study Performance: **dermagold100**

10.27. *In Vitro Shockwave Treatment Influences Lymphatic Endothelial Cells Marker Expression and Proliferation (Riedl et al., 2014)*

Ludwig Boltzmann Institute for Experimental and Clinical Traumatology, Vienna.

Introduction: Extracorporeal shockwave treatment (ESWT) is a promising therapy for treating orthopedic diseases and chronic wounds and further induces blood and lymphatic vessel growth. In this study we analyzed the effects of shockwaves on lymphatic endothelial cells (LEC) in vitro.

Methods: LEC were stimulated in a water bath with an MTS Dermagold 100 device. Twenty-four hours later, flow cytometry analyses for endothelial marker expression were performed. The LEC proliferation and viability changes after ESWT were determined by manual counting and MTT assays. 2D and 3D migration changes were investigated by scratch and bead assays. Furthermore, miRNA expression changes were evaluated.

Results: The proliferation rates of LEC varied when stimulation with different energy flux densities was applied and 2D and 3D migration was significantly enhanced by ESWT. The endothelial markers CD31, VE-Cadherin, VEGFR2 as well as the LEC marker VEGFR3 expression did not change after ESWT. However, we found an energy density and population-dependent increase in the expression of the LEC-specific podoplanin. Different miRNA level alterations after ESWT including podoplanin-regulating miR-29b were identified.

Discussion: Since lymphatic vessels play a key role in tissue hemostasis, regeneration of lymphatic vessels is of crucial interest for tissue engineering purposes or for lymphedema patients. Our results add new insights into ESWT-induced changes of LEC behavior and reveal podoplanin as one of the target molecules of ESWT.

Conclusion: ESWT influences the proliferation and migration of isolated lymphatic endothelial cells and mediates podoplanin upregulation in these cells.



17th International Congress of the ISMST 2014 in Milano, Italy. Abstract No. 3.

Study Performance: **dermagold100**

10.28. *In Vitro Shockwave Treatment Influences Lymphatic Endothelial Cells Marker Expression and Proliferation (Riedl et al., 2013)*

Ludwig Boltzmann Institute for Experimental and Clinical Traumatology, Vienna.

Introduction: Shockwave treatment (SWT) holds promise in treating orthopedic diseases and chronic wounds. Additionally, it has been shown to increase blood and lymphatic vessel densities. In this study we analyzed the effects of shock waves in lymphatic endothelial cells (LECs) in an in vitro setup.

Methods: LECs were stimulated using an in vitro experimental set-up with an unfocused shockwave device (dermagold100, MTS, Germany). Twenty-four hours later, the cells were subjected to flow cytometry for endothelial marker expression. Moreover, 2D as well as 3D migration assays were employed. To analyze the effects of different extracellular matrices, cells were cultured either on fibronectin, collagen or uncoated surfaces.

Results: LECs reacted with varying proliferation rates when stimulated with different energies. In 2D- and 3D-migration assays LECs did not behave differently upon SWT treatment. The endothelial markers CD31, VE-Cadherin, VEGFR-2 as well as the LEC marker VEGFR-3 expression were not altered after SWT. However, we found an energy-dependent increase in expression of podoplanin, another marker for LECs. In addition, the extracellular matrix was shown to influence podoplanin expression and inducibility upon SWT.

Discussion: Regeneration of lymphatic vessels is of crucial interest for tissue engineering purposes or for lymphedema patients. SWT has been shown to stimulate the growth of new blood as well as lymphatic vessels. Our results add new insights into SWT-induced changes of LEC behavior and reveal podoplanin as one of the target molecules of SWT.

Conclusion: Shockwave treatment influences the proliferation of isolated lymphatic endothelial cells and upregulates podoplanin in these cells.

16th International Congress of the ISMST 2013 in Salzburg, Austria, Abstract No. P4.

Study Performance: **dermagold100**

10.29. *Shock Wave Treatment Induces Angiogenesis and Mobilizes Endogenous CD31/CD34-Positive Endothelial Cells in a Hindlimb Ischemia Model: Implications for Angiogenesis and Vasculogenesis (Tepeköylü et al., 2013)*

University Hospital for Cardiac Surgery, Innsbruck Medical University, Innsbruck, Austria.

Objectives: Shock waves have been shown to induce recruitment of intravenously injected endothelial progenitor cells to ischemic hind limbs in rats. We hypothesized that shock wave treatment as sole therapy would induce angiogenesis in this ischemia model and would lead to mobilization of endogenous endothelial (progenitor) cells.

Methods: A total of 18 rats, aged 5 weeks old, were subdivided into 3 groups: sham (n = 6), ischemic muscle with shock wave treatment (shock wave treatment group, n = 6), and without shock wave treatment (control, n = 6). Hind limb ischemia was induced by ligation of the femoral artery. Three weeks later, shock wave treatment (300 impulses at 0.1 mJ/mm²) was applied to the adductor muscle; the controls were left untreated. Muscle samples were analyzed using real-time polymerase chain reaction for angiogenic factors and chemoattractants for endothelial progenitor cell mobilization.

Fluorescence activated cell sorting analysis of the peripheral blood was performed for CD31/CD34-positive cells. Perfusion was measured using laser Doppler imaging. Functional improvement was evaluated by walking analysis.

Results: Angiogenic factors/endothelial progenitor cell chemoattractants, stromal cell-derived factor-1 and vascular endothelial growth factor, were increased in the treatment group, as shown by real-time polymerase chain reaction, indicating the mobilization of endothelial progenitor cells. Fluorescence activated cell sorting analysis of the peripheral blood revealed high numbers of CD31/CD34-positive cells in the treatment group. Greater numbers of capillaries were found in the treated muscles. Blood perfusion increased markedly in the treatment group and led to functional restoration, as shown by the results from the walking analysis.

Conclusions: Shock wave therapy therefore could develop into a feasible alternative to stem cell therapy in regenerative medicine, in particular for ischemic heart and limb disease.

Study Performance: **orthogold180c** with applicator CG050-P

10.30. *Early Angiogenic Response to Shock Waves in a Three-Dimensional Model of Human Microvascular Endothelial Cell Culture (HMEC-1)* (Sansone et al., 2012)

Orthopaedic Department, University of Milan, IRCCS Orthopedic Institute Galeazzi, Milan, Italy.

The exact nature of shock wave (SW) action is not, as yet, fully understood, although a possible hypothesis may be that shock waves induce neoangiogenesis. To test this hypothesis, a three-dimensional (3D) culture model on Matrigel was developed employing a human microvascular endothelial cell line (HMEC-1) which was stimulated with low energy soft- focused SW generated by an SW lithotripter. After 12 hours we observed a statistically significant increase in capillary connections subsequent to shock-wave treatment in respect to the control group and a marked 3-hour down-regulation in genes involved in the apoptotic processes (BAX, BCL2LI, GADD45A, PRKCA), in cell cycle (CDKN2C, CEBPB, HK2, IRF1, PRKCA), oncogenes (JUN, WNT1), cell adhesion (ICAM-1), and proteolytic systems (CTSD, KLK2, MMP10). Our preliminary results indicate that microvascular endothelial cells in vitro quickly respond to SW, proliferating and forming vessel-like structures, depending on the energy level employed and the number of shocks released. The early decreased expression in the analysed genes could be interpreted as the first reactive response of the endothelial cells to the external stimuli and the prelude to the events characterizing the neo-angiogenic sequence.

Study Performance: **orthogold100** with applicator OP-155

10.31. *New Insights into Morphology of Cardiac Tissue Regeneration after Direct Epicardial Shock Wave Treatment* (Holfeld et al., 2011)

Dept. of Cardiac Surgery, Innsbruck Medical University, Austria.

Introduction: Shockwave Therapy (SWT) of ischemic skeletal muscle was shown to enhance the recruitment of intravenously injected endothelial progenitor cells (EPC) in rats. In a previous trial we showed that direct epicardial SWT induces angiogenesis in ischemic heart failure in rats without injection of EPC's. We therefore hypothesized that SWT causes recruitment of autologous EPC's in hind limb ischemia.

Methods: 5-week-old rats were subdivided in 3 groups: sham (n=18), ischemic muscle with SWT (SWT group, n=18) and without SWT (control, n=18). Hind limb ischemia was induced by ligation of the femoral artery. Three weeks later SWT (300 impulses at 0.1 mJ/ mm²) was applied on the adductor muscle; controls were left untreated. Blood flow was measured by laser Doppler imaging. Muscle



samples were analyzed by RT-PCR for angiogenetic factors and chemoattractants for EPC recruitment. FACS analysis of the peripheral blood was performed for CD31 and CD34 positive cells. Functional improvement was evaluated by walking analysis.

Results: Six weeks after SWT there was increased blood flow within the ischemic muscle and functional improvement. PCNA analysis revealed increased proliferation in the SWT group. SDF-1 and VEGF were both up-regulated in the treatment group, indicating the recruitment of EPC's. FACS analysis of peripheral blood showed high numbers of CD31 / CD34 positive cells in the treatment group.

Discussion: This study showed that Shockwave Therapy of ischemic tissue induces recruitment of endothelial progenitor cells. We believe that they may originate from bone marrow and will have to prove this hypothesis in a future trial.

Conclusion: Shockwave Therapy may develop into a feasible alternative to (stem) cell therapy in regenerative medicine, in particular for ischemic heart disease.

14th ISMST Congress in Kiel, Germany. Abstract No. 19.

Study Performance: **Cardiogold**

10.32. Changes in Connexine Expression of Cardiomyocytes after In Vitro Shock Wave Treatment (Holfeld et al., 2010)

Dept. of Cardiothoracic Surgery, Medical University of Vienna, Austria. Core Unit for Biomedical Research, Medical University of Vienna, Austria. AUVA Trauma Center Meidling, Vienna, Austria.

Introduction: Recently shock wave therapy (SWT) at low energy levels is well known to effect tissue regeneration in ischemic myocardium. However, the underlying mechanism remains largely unknown. Methods: Primary cell cultures of endothelial cells and fibroblasts were established from native rat hearts. Additionally, H9C2-cardiomyocytes (American Type Culture Collection) were used. A thermostatically controlled water bath was designed to avoid distracting physical effects. Adherent cells in common cell culture flasks fully filled with culture medium were dunked into the water bath. Unfocused SWT at an energy flux density of 0.15 mJ/mm² were applied with a frequency of 5 Hz. Non-treated cells were used as controls. Several analyses of immunohistochemistry and molecular biology was performed.

Results: SWT causes significant changes in expression of connexines Cx40, Cx43 and Cx45 in cardiomyocytes. The expression of connexines is largely disproportionate in differentiated and normal cells. Changes in metabolic and electrical coupling of cardiomyocytes may cause considerable effects onto the myocardium.

Discussion: Gap junctions are water-filled pores formed by the docking of two hemi-channels (connexons), contributed by each of the adjoining cells. Gap junctions are responsible for direct exchange of small hydrophilic molecules and ions between neighboring cells. Therein metabolites and messengers such as sodium, potassium, calcium, cAMP/cGMP, ADP/ATP and inositol 1,4,5-triphosphate are included. This results in metabolic and electrical coupling of cells. Cx40, Cx43 and Cx45 are expressed between cardiomyocytes. Changes in their expression cause alteration of cell communication.

Conclusion: SWT causes significant changes in connexine expression of cardiomyocytes. The expression of connexines is largely disproportionate in differentiated and normal cells. This alteration of cell communication may at least be part of the tissue regenerative effect mediated by SWT in ischemic myocardium.

13th ISMST Congress in Chicago, USA. Abstract No. 9.

Study Performance: **DermaGold** with applicator CP155

10.33. *Recruitment of Endothelial Progenitor Cells after Direct Epicardial Shock Wave Treatment of Ischemic Heart Failure in Rats (Holfeld et al., 2010)*

Department of Cardiothoracic Surgery, Medical University of Vienna, Vienna, Austria.

Introduction: Shock wave therapy (SWT) reportedly improves ventricular function by enhancing angiogenesis in ischemic myocardium. We hypothesized that recruitment of Endothelial Progenitor Cells (EPC) may therein be involved.

Methods: Adult Sprague Dawley rats were subdivided in 3 groups: sham-operated (sham), infarcted myocardium with epicardial SWT (SWT group) and infarcted myocardium without epicardial SWT (control). Four weeks following myocardial infarction (MI), SWT (100 impulses at 0.15 mJ/m²) was applied directly to the infarcted region in the SWT-group, control animals were left untreated. Cardiac function was evaluated using echocardiography. Angiogenesis was evaluated by analysis of several RNA and protein expressions.

Results: Fourteen weeks after epicardial SWT, left ventricular function improved in the SWT-group as compared to 4 weeks after MI and as compared to the controls. Quantitative histology revealed more vital cells and more endothelial cells in the SWT group.

SDF-1 and its receptor CXCR-4 were both upregulated in the treatment group as shown by immunohistochemistry. FACS analysis of peripheral blood showed significantly more circulating EPCs in the treatment group.

Discussion: It is well known that SWT causes neo-vascularization. The chemoattractant SDF-1 is responsible for recruitment and homing of EPCs. We found high numbers of circulating EPCs in peripheral blood of the treatment group after direct epicardial SWT. At the same time SDF-1 and its receptor CXCR-4 were upregulated in the myocardium. These findings indicate that one of the main mechanisms of SWT may be recruitment of vessel forming cells.

Conclusion: Direct epicardial shock wave therapy induces neo-vascularisation in an experimental model of ischemic heart failure in rats. Thereby high numbers of circulating endothelial progenitor cells can be found in peripheral blood. Therefore, one of SWT's main mechanism may be recruitment of vessel forming cells.

13th ISMST Congress in Chicago, USA. Abstract No. 23.

Study Performance: **CardioGold** CG050

10.34. *Direct Epicardial Shock Wave Therapy Improves Ventricular Function and Induces Angiogenesis in Ischemic Heart Failure (Zimpfer et al., 2009)*

Department of Cardiothoracic Surgery, Medical University of Vienna, Vienna, Austria.

Objectives: Direct application of low-energy unfocused shock waves induces angiogenesis in ischemic soft tissue. The potential effects of epicardial shock wave therapy applied in direct contact to ischemic myocardium are uncertain.

Methods: For induction of ischemic heart failure in a rodent model, a left anterior descending artery ligation was performed in adult Sprague-Dawley rats. After 4 weeks, reoperation with (treatment group, n = 60) or without (control group, n = 60) epicardial shock wave therapy was performed. Low-energy shock waves were applied in direct contact with the infarcted myocardium (300 impulses at 0.38 mJ/m²). Additionally, healthy animals (n = 30) with normal myocardium were studied.



Angiogenesis, ventricular function upregulation of growth factors, and brain natriuretic peptide levels were analyzed.

Results: Histologic analysis revealed significant angiogenesis 6 weeks (treatment group: 8.2 +/- 3.7 vs control group: 2.9 +/- 1.9 vessels per field, $P = .016$) and 14 weeks (treatment group: 7.1 +/- 3.1 vs control group: 3.2 +/- 1.8 vessels per field, $P = .011$) after shock wave treatment. In the treatment group ventricular function improved throughout the follow-up period (6 weeks: 37.4% +/- 9% [$P < .001$] and 14 weeks: 39.5% +/- 9% [$P < .001$]). No improvement of ventricular function was observed in the control group (6 weeks: 28.6% +/- 5% and 14 weeks: 21.4% +/- 5%). Rat brain natriuretic peptide 45 levels were lower in the treatment group compared with those in the control group 6 and 14 weeks after treatment. Vascular endothelial growth factor, Fms-related tyrosine kinase 1, and placental growth factor levels were upregulated after 24 and 48 hours and 7 days in the treatment group. No effects on healthy myocardium were observed.

Conclusion: Direct epicardial low-energy shock wave therapy induces angiogenesis and improves ventricular function in a rodent model of ischemic heart failure.

Study Performance: **orthogold180c** with applicator CG050-P

10.35. *Shock Wave Therapy as an Alternative to Cardiac Cell Therapy – An In-Vitro Examination (Holfeld et al., 2009)*

Department of Cardiothoracic Surgery and Core Unit for Biomedical Research, Medical University of Vienna, Austria.

Introduction: Recently it has been well documented that shock waves at low energy levels induce tissue regenerative effects. Transthoracic application of shock waves (SW) can be shown to augment myocardial vascularization in a porcine model of myocardial infarction. SW even improve myocardial perfusion and cause relief of angina symptoms in human patients with severe coronary artery disease. Nevertheless, the underlying mechanism remains largely unknown.

Methods: Primary cell cultures of endothelial cells and fibroblasts were established from native rat hearts. Additionally, H9C2-cardiomyocytes (American Type Culture Collection) were used. A thermostatically controlled water bath was designed to avoid distracting physical effects. Adherent cells in common cell culture flasks filled with culture medium were dunked into the water bath. Unfocused SW at an energy flux density of 0.15 mJ/mm² were applied to the cells with a frequency of 5 Hz. Non-treated cells were used as a control group. Number of cells and their vitality were analysed over a period of 7 days. Numerous analyses of immunohistochemistry and molecular biology were performed.

Results: SW stimulate every cardiac cell type to a different extent. Each cell type reacts at a different time point after treatment as well. The distance between the applicator and the cells and the energy flux density have a strong influence on the cells' behavior. Between day 4 and day 5 the duplication time of treated cells was significantly higher compared to controls. Immunohistochemistry and molecular biology show significant differences in the gene expression of MMP's, TIMP's and collagen. Treated cells also alter their cytoskeleton (Vimentin, Tubulin, beta-Actin) and show significantly more proliferation (Ki-67) and changes in the expression of adhesion molecules (CD31) as well as connexins 40, 43, 45. No apoptosis was found in the treatment group.

Discussion: SW activate proliferation of cardiac cells. Endothelial cells proliferate fastest, which underlines the known effect of neovascularization in-vivo. Moreover, cells alter the assembly of microfilaments, and thus seem to ameliorate cell migration. Changes in the MMP and TIMP levels, as well as the expression of adhesion molecules seem to be strongly involved in the SW tissue regenerative effect on ischemic myocardium.

12th ISMST Congress in Sorrento, Italy. Abstract No. 53.

Study Performance: **dermagold** with applicator CP155

10.36. *Direct Epicardial Shock Wave Therapy in a Porcine Model of Myocardial Infarction – Pre-clinical Safety and Feasibility Aspects (Holfeld et al., 2009)*

Dept. of Cardiothoracic Surgery, Medical University of Vienna Laboratory for Cardiovascular Research, Medical University of Vienna, 1090 Vienna, Austria.

Introduction: Animal trials with a rodent model of myocardial infarction showed promising results of direct epicardial shock wave therapy (DESWT). Cardiac function improved to a normal level however, safety and feasibility in a large animal model with hearts comparable to human hearts remain unknown.

Methods: Pigs were subdivided in 3 groups: unharmed myocardium with DESWT (healthy control, n=2), infarcted myocardium with DESWT (SWT-group, n=6) and infarcted myocardium without DESWT (control, n=2). Four weeks following myocardial infarction (MI), DESWT (300 impulses at 0.15 mJ/mm²) was applied directly to the infarcted area in the healthy control and the SWT-group; controls were left untreated. According to human cardiac surgery, some animals were treated with heparin prior to DESWT. Cardiac function was evaluated using echocardiography before MI, 4 weeks after MI and 4 weeks after DESWT. Electrocardiographic recording was performed during and after treatment.

Results: After DESWT, ejection fraction improved in the SWT-group as compared to 4 weeks after MI ($62 \pm 9.1\%$, $p=0.006$); no improvement was observed in the control group ($46 \pm 5\%$, $p=0.126$). As compared to healthy controls ($69 \pm 1.4\%$) ejection fraction normalized in the SWT-group 4 weeks after SWT ($p=0.358$); it remained decreased in the control group ($p=0.031$). No arrhythmias were observed during treatment. In histological examinations no lesions of cardiac cells could be found.

Discussion: DESWT improves left ventricular function in a porcine model of myocardial infarction. No adverse effects, in particular no arrhythmias or cell lesions, were observed. Even in heparin treated animals DESWT showed no side-effects.

Conclusion: DESWT therefore seems to be an effective and safe therapeutic strategy for the treatment of ischemic heart disease.

12th ISMST Congress in Sorrento, Italy. Abstract No. 55.

Study Performance: **cardiogold** with applicator CG050

10.37. *The Importance of a Standardized Model for Shock Wave In-Vitro Trials – a Proposal Plus Preliminary Results of Cardiac Cells (Holfeld et al., 2008)*

Dept. of Cardiothoracic Surgery and Core Unit for Biomedical Research, Medical University Vienna, Austria.

Introduction: Literature reveals very diverse methods of applying shock waves onto cell cultures. Since results of equal cells treated in different ways are not comparable, establishing a standardized model for future in-vitro trials would be useful.

Methods: Primary cell cultures of endothelial cells and fibroblasts were established from native rat hearts. Additionally, H9C2-cardiomyocytes (American Tissue Culture Collection) were used. All cell types were cultured using DMEM medium supplement with different nutrients and growth factors. A thermostatically controlled water bath was designed to avoid distracting physical effects, in particular, reflections. Adherent cells in common cell culture flasks filled with culture medium were dunked into



the water bath. Various energy flux densities of unfocused SWT were applied in different distances to the cells. Number of cells and their vitality then were analyzed over a period of 7 days.

Results: The water bath is a good method to avoid reflections and negative pressure of the shock waves. SWT stimulates every cardiac cell type to a different extent. Each cell type reacts at a different timepoint after treatment. The distance between the applicator and the cells, as well as the energy flux density have a strong influence on the cells' behavior.

Conclusion: SWT stimulates growth of cardiac cells. The thermostatically controlled water bath is a useful and recommendable tool for further shock wave in-vitro trials.

11th ISMST Congress in Juan le Pins, France Abstract No. 52.

Study Performance: **DermaGold**

10.38. *Epicardial Shock Wave Therapy Induces Neoangiogenesis and Improves Left Ventricular Function After Myocardial Infarction in Pigs In Vivo (Holfeld et al., 2008)*

Dept. of Cardiothoracic Surgery, Medical University Vienna.

Introduction: Therapeutic options of ischemic heart failure are limited. Shock wave therapy (SWT) reportedly induces VEGF overexpression in ischemic myocardium. We hypothesized that epicardial SWT improves ventricular function in an experimental model of ischemic heart failure by inducing neoangiogenesis.

Methods: Pigs were subdivided in 3 groups: unharmed myocardium with epicardial SWT (healthy control, n=2), infarcted myocardium with epicardial SWT (SWT-group, n=6) and infarcted myocardium without epicardial SWT (control, n=2). Four weeks following myocardial infarction (MI), epicardial SWT (300 impulses at 0.15 mJ/m²) was applied directly to the infarcted area in the healthy control and the SWT-group; controls were left untreated. Cardiac function was evaluated using echocardiography before MI, 4 weeks after MI and 4 weeks after SWT. Angiogenesis was evaluated 4 weeks after treatment by immunohistology with von Willebrand Factor antibody, which was morphometried with Lucia software.

Results: Compared to healthy controls (68±0.7%), left ventricular ejection fraction decreased in the SWT (43±2.5%, p<0.001) and control group (41±4.2%, p=0.012) 4 weeks after MI. After epicardial SWT, ejection fraction improved in the SWT-group as compared to 4 weeks after MI (62±9.1%, p=0.006), no improvement was observed in the control group (46±5%, p=0.126). As compared to healthy controls (69±1.4%) ejection fraction normalized in the SWT-group 4 weeks after SWT (p=0.358), it remained decreased in the control group (**p=0.031**). **No adverse effects were observed.**

Discussion: Epicardial SWT improves left ventricular function after myocardial infarction in pigs.

Conclusion: Epicardial SWT therefore seems to be an effective and safe therapeutic strategy for the treatment of ischemic heart disease.

11th ISMST Congress in Juan le Pins, France Abstract No. 62.

Study Performance: **CardioGold** CG050

10.39. *Direct Epicardial Shock Wave Therapy Improves Left Ventricular Function in an Experimental Model of Ischemic Heart Failure (Zimpfer et al., 2008)*

Dept. of Cardiothoracic Surgery, Medical University Vienna.

Introduction: Prognosis of ischemic heart failure is poor and therapeutic options are limited. Shock wave therapy (SWT) reportedly induces VEGF overexpression in ischemic skin flaps and ischemic myocardium. Here, we hypothesized that epicardial SWT improves ventricular function by enhancing angiogenesis in an experimental model of ischemic heart failure in rats.

Methods: Adult Sprague Dawley rats were subdivided into 3 groups: sham-operated (sham), infarcted myocardium with epicardial SWT (SWT group) and infarcted myocardium without epicardial SWT (control). Four weeks following myocardial infarction (MI), epicardial SWT (100 impulses at 0.38 mJ/m²) was applied directly to the infarcted region in the SWT-group, control animals were untreated. Cardiac function was evaluated using echocardiography before MI, 4 weeks after MI and 12 weeks after SWT. Angiogenesis was evaluated 12 weeks after treatment in serial sections stained with von Willebrand Factor antibody, which were digitalized and morphometried.

Results: As compared to sham group (50±4%), left ventricular function decreased in the SWT (21±9%, p<0.001) and control (18±4%, p<0.001) group 4 weeks after MI. Fourteen weeks after epicardial SWT, left ventricular function improved in the SWT-group as compared to 4 weeks after MI (37±8%, p=0.021) and as compared to the controls (21±4%, p<0.001). Quantitative histology revealed more vital cells (384±84 cells/field in SWT vs. 288±56 in controls, p=0.02) and enhanced angiogenesis (7.1±3.3 vessels/field in SWT vs. 3.2±1.8 in controls, p=0.016) in the SWT group.

Conclusion: Direct epicardial shock wave therapy improves left ventricular function and induces neoangiogenesis in an experimental model of ischemic heart failure in rats.

11th ISMST Congress in Juan le Pins, France Abstract No. 63.

Study Performance: **CardioGold** CG050

10.40. *Effects of Unfocused Shock Waves Stimulation on Human Microvascular Endothelial Cell Line HMEC-1 (d'Agostino et al., 2007)*

Orthopaedic Department of the University of Milan (Milan, Italy).

Introduction: Unfocused Shock Waves (uSW) can induce soft tissue regeneration, mainly due to neoangiogenesis, the mechanisms of which are partly unknown. The aim of our study was to investigate the effects of uSW on human microvascular endothelial cell line HMEC-1.

Methods: Cell cultures were stimulated with uSW (Dermagold, MTS) according to different protocols. Cell viability was assessed spectrophotometrically by XTT assay; for angiogenesis experiments, cells were grown in 24-well plates on Matrigel matrix, and vessels-like structures were quantified by counting the capillary connections under an inverted microscope.

Results: Most relevant results were obtained at lower energies and 200 pulses. Results of 24h XTT assay showed enhanced metabolic activity in treated cultures, compared to controls (Treated/Controls Optical Density ratio was 1.8). Results from 24h-angiogenesis assay showed more capillary connections in uSW treated cultures than controls (31.40 ± 2.064 vs. 17.00 ± 3.286; p<0.05).

Discussion: In the literature, endothelial cell damage has been described after lithotripsy. Our data (enhanced metabolic activity and increased in vitro angiogenesis after uSW stimulation of HMEC-1 cell line), while encouraging a suitable use of this in vitro model, suggest some intriguing speculation about mechano-induced tissue healing and angiogenesis.

Conclusion: A preliminary report on the potential metabolic enhancement and mitogenic effect on human microvascular endothelial cells, induced by unfocused Shock Wave (uSW) stimulation is presented. On this basis, the mechanism of neoangiogenesis in vivo and the role of endothelium as the main target of shock waves in living tissues may be postulated.

10th International Congress of the ISMST 2007 in Toronto, Canada, Abstract 37.



11. Physics / In Vitro Engineering

11.1. *Physical Considerations for In Vitro ESWT Research Design* (Slezak, Rose, et al., 2022)

Department of Physics Utah Valley University Orem, USA.

In vitro investigations, which comprise the bulk of research efforts geared at identifying an underlying biomechanical mechanism for extracorporeal shock wave therapy (ESWT), are commonly hampered by inadequate descriptions of the underlying therapeutic acoustical pressure waves. We demonstrate the necessity of in-situ sound pressure measurements inside the treated samples considering the significant differences associated with available applicator technologies and cell containment. A statistical analysis of pulse-to-pulse variability in an electrohydraulic applicator yields a recommendation for a minimal pulse number of $n = 300$ for cell pallets and suspensions to achieve reproducible treatments. Non-linear absorption behavior of sample holders and boundary effects are shown for transient peak pressures and applied energies and may serve as a guide when in-situ measurements are not available or can be used as a controllable experimental design factor. For the use in microbiological investigations of ESWT we provide actionable identification of common problems in describing physical shockwave parameters and improving experimental setups by; (1) promoting in-situ sound field measurements, (2) statistical evaluation of applicator variability, and (3) extrapolation of treatment parameters based on focal and treatment volumes.

Study Performance: **orthogold100**, Applicator OP155 and OE050

11.2. *Variable Sound Fields of Electro-Hydraulic Extracorporeal Shockwave Applicator* (Slezak et al., 2019)

Department of Physics Utah Valley University Orem, USA.

Introduction: Electro-Hydraulic Extracorporeal Shockwave generation results a shot-varying non-linear sound-fields which are not yet properly characterized.

Material and Method: We have utilized a non-linear wave-propagation simulation in conjunction with experimental spark-gap measurements to predict statistical variations of generated sound-fields. These results are in turn validated with experimental point-wise field measurements in reference water baths as well as in-situ applications.

Results: Experimental verification of simulation results for reproducible fields (i.e. Electro-magnetic and piezo) show good agreement and a significant advantage of non-linear simulation techniques over linear approximations for higher pressure waves. Electro-Hydraulic shock generation based on is shown to result in a probabilistic field distribution based on experimental spark-location distributions.

Discussion: We provide clear evidence based on theoretical models alongside supporting experimental of the non-stationary nature of Electro-Hydraulic generated sound-fields. The indeterminate location of spark-gap induced collapsing plasma bubble results in a inter-shot variable field which applies varying energies and peak pressures throughout the treatment area. In combination with anatomic models the resulting in-silico treatment options can be numerically modeled and differences in applicator technologies estimated.

Conclusion: We introduce a novel approach to characterize the sound-fields Electro-Hydraulic applicators. This approach is applied in estimating and comparing of treatment modalities.

22th International Congress of the ISMST 2019 in Beijing, China, Abstract B2.

Study Performance: **OW100**

11.3. *Shock Wave Treatment for In Vitro Engineering Applications (Weihs et al., 2016)*

University of Applied Sciences Technikum Wien, Dept. Of Biochemical Engineering, Vienna, Austria.

Introduction: Recently, the cellular effects of shock wave treatment have been thoroughly studied using *in vitro* approaches. We already described intracellular pathways involved in the shock wave treatment effect using the *in vitro* shock wave treatment (IVSWT) water bath set-up and various cell types. We suppose that the beneficial cellular effects of shock waves – such as increased proliferation or enhanced growth factor expression – could also be exploited in the emerging field of the application on 3D cell culture systems and cell/scaffold constructs would therefore provide a promising tool for tissue engineering purposes.

Methods: Several three-dimensional cell culture systems such as spheroids of stem cells, various cell-loaded hydrogels and scaffolds, were subjected to *in vitro* shock wave treatment.

Results: Diverse protocols were developed and tested to establish optional treatment set-ups and parameters, e.g. stiffness of the used scaffolds, medium density as well as optimal number of shock wave treatments were evaluated in order to find the optimal conditions for diverse 3D systems.

Discussion: The potential of shock wave treatment to trigger mechanosensitive pathways can be used to improve proliferation or differentiation in 3D systems *in vitro* in order to support scaffold maturation and ultimately enhance cell-scaffold performance. Thus, the experience on the application of shock waves on 3D cell culture systems and scaffolds will help to establish shock wave treatment as a potent tool in the field of tissue engineering and regenerative medicine.

4th ISMST Basic Research Meeting in Vienna, Austria.

Study Performance: **dermagold100** with OP155 applicator

11.4. *Shock Wave Application to Cell Cultures (Holfeld, Tepeköylü, Kozaryn, Mathes, et al., 2014)*

University Hospital for Cardiac Surgery, Innsbruck Medical University, Innsbruck, Austria.

Shock waves nowadays are well known for their regenerative effects. Basic research findings showed that shock waves do cause a biological stimulus to target cells or tissue without any subsequent damage. Therefore, *in vitro* experiments are of increasing interest. Various methods of applying shock waves onto cell cultures have been described. In general, all existing models focus on how to best apply shock waves onto cells. However, this question remains: What happens to the waves after passing the cell culture? The difference of the acoustic impedance of the cell culture medium and the ambient air is that high, that more than 99% of shock waves get reflected! We therefore developed a model that mainly consists of a Plexiglas built container that allows the waves to propagate in water after passing the cell culture. This avoids cavitation effects as well as reflection of the waves that would otherwise disturb upcoming ones. With this model we are able to mimic *in vivo* conditions and thereby gain more and more knowledge about how the physical stimulus of shock waves gets translated into a biological cell signal ("mechanotransduction").

Study Performance: **orthogold180c** with applicator CG050-P

11.5. *Accumulated Total Energy Flux Density an Indicator to Compare Electrohydraulic and Piezoelectric Device? (Neumann and Duchtstein, 2012)*

Institute for Pharmacy; University of Hamburg; Hamburg, Germany.



Introduction: Piezoelectric and electrohydraulic devices are commonly used for shockwave therapy. So far there is no way to compare the application parameters and energy flux densities of both devices. Generated shock-waves have different wave characteristics, which follow a slight curve in case of electrohydraulic and a cone shape in case of piezoelectric devices. Furthermore, the load voltage of the generation principles varies whereby the emitted energy is different. The energy flux densities in the defined zones (-6 dB, 5 MPa, 5 mm) of a pressure-area curve of a single wave (**Figure Pressure zones**) can be measured and help to compare both machines.

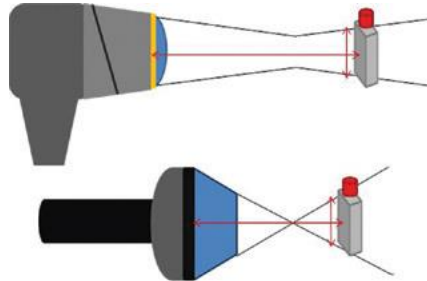
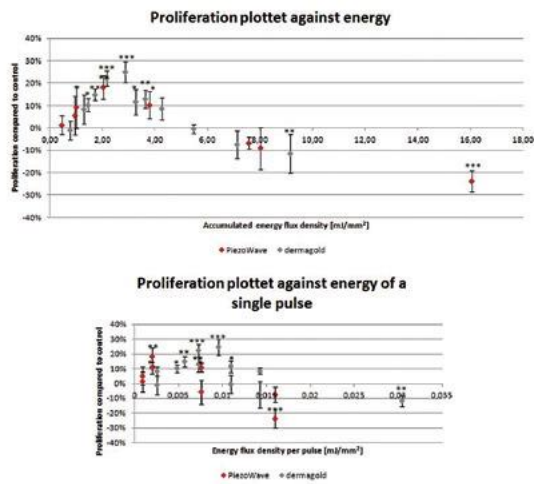
Materials and Methods: Normal human dermal fibroblasts were treated using the IVSWT Water Bath. Shock-wave machines used were Orthowave 180c CP-155, MTS Europe GmbH or PiezoWave F7G3, Richard Wolf GmbH. Seven Days after treatment proliferation results compared to control were measured. Several distances between applicator and cells were tested, as well as different energy levels and number of pulses. With the theorem of intersecting lines, the treated diameter was calculated (**Figure Treated diameter**). Considering the number of applied pulses, the emitted energy in the observed zone and the treated area, an accumulated energy flux density for every zone was calculated.

Results: First, the measured emitted energies, which imply the level of intensity, were plotted against the load voltage and compared in every energy zone (**Figure Regression curves**). As a result, it could be seen that only the 5 MPa zone was useful for analysis. The emitted energy of the piezoelectric device is in the -6dB zone nearly stable for every level of intensity. This follows from an increase in energy flux density but decrease of the focus zone. In the 5 mm zone the area of the focus from the electrohydraulic device is not covered. Loss of effective energy compared to the piezoelectric device follows from that. Proliferation results for both principles of shock wave generation compared to control were plotted against the accumulated energy flux density (**Figure Graphs proliferation and energy**). Both devices show comparable results, which can be seen in the first graph. The curve, created from the results of the PiezoWave and dermagold, follows a skew distribution with steep increase to lower and slight decrease to higher accumulated energy flux densities. Statistically significant enhancement of proliferation is shown between an accumulated energy flux density of 1-4 mJ/mm² in both cases ($n \geq 3$; Mean \pm SD; * $p < 0,05$; ** $p < 0,01$; *** $p < 0,001$). Over 9 mJ/mm² energy input a significant reduction of cell numbers due to cell loss is shown. That means that accumulated energy flux densities in the 5 MPa zone are comparable for electrohydraulic and piezoelectric principles of generation. The second graph shows that the energy, which is necessary for a positive effect, cannot be applied with a single pulse. Choosing energy flux densities over 0,01 mJ/mm² significant reduction of cell numbers is caused.

Conclusion: The effect of shock-wave treatment with both electrohydraulic and piezoelectric devices on the proliferation of fibroblasts can be compared for same accumulated energy flux density in the 5 MPa zone. Between 1-4 mJ/mm² an equal enhancement of proliferation was proved in both cases.

Discussion: Presented data show results which are only measured for the proliferation of fibroblasts seven days after treatment. Some accumulated energy flux densities were not analysed because experiments were already finished before this way of analysis was developed. To compare both devices for clinical usage more experiments have to be carried out to verify these results.

FIGURES



Published in *ISMST Journal Schockwave*, June 2022 – Volume 8 – Issue 1

Study Performance: **Ortho**wave 180c CP-155



12. Bibliography

- Ahmed, E., eldibany, moustafa, Melek, L., & abdelnaby, hoda. (2022). COMPARATIVE STUDY BETWEEN THE EFFECT OF SHOCKWAVE THERAPY AND LOW-INTENSITY PULSED ULTRASOUND (LIPUS) ON BONE HEALING OF MANDIBULAR FRACTURES (CLINICAL & RADIOGRAPHIC STUDY). *Alexandria Dental Journal*, 47(1), 29–35. <https://doi.org/10.21608/adjalexu.2022.26630.1076>
- Antonic, V., Hartmann, B., Balks, P., Schaden, W., & Ottomann, C. (2018). Extracorporeal shockwave therapy as supplemental therapy for closure of large full thickness defects—Rat full-thickness skin graft model. *Wound Medicine*. <https://doi.org/10.1016/j.wndm.2017.11.001>
- Antonic V, Hartmann B, Münch S, Belfekroun C, Niedobitek G, et al. (2015). Extracorporeal Shockwaves (ESW) Promote Proliferation and Differentiation of Keratinocytes In vitro-Histology and Immunohistochemistry. *J Bioengineer & Biomedical Sci* 5:161. <https://doi.org/10.4172/2155-9538>
- Atsawasuwana, P., Chen, Y., Ganjawalla, K., Kelling, A. L., & Evans, C. A. (2018). Extracorporeal shockwave treatment impedes tooth movement in rats. *Head and Face Medicine*. <https://doi.org/10.1186/s13005-018-0181-5>
- Basoli, V., Chaudary, S., Cruciani, S., Santaniello, S., Balzano, F., Ventura, C., Redl, H., Dungal, P., & Maioli, M. (2020). Mechanical Stimulation of Fibroblasts by Extracorporeal Shock Waves: Modulation of Cell Activation and Proliferation Through a Transient Proinflammatory Milieu. *Cell Transplantation*. <https://doi.org/10.1177/0963689720916175>
- Belloli, L., Cugno, M., D'Agostino, M. C., Ughi, N., Tedeschi, A., Respizzi, S., & Marasini, B. (2013). Shock wave therapy for systemic sclerosis. In *Rheumatology International* (Vol. 33, Issue 4, pp. 1099–1100). <https://doi.org/10.1007/s00296-011-2277-0>
- Bereket, C., Cakir-Özkan, N., Önger, M. E., & Arici, S. (2018). The effect of different doses of extracorporeal shock waves on experimental model mandibular distraction. *Journal of Craniofacial Surgery*. <https://doi.org/10.1097/SCS.00000000000004571>
- Bhojani, N., Mandeville, J. A., Hameed, T. A., Soergel, T. M., McAteer, J. A., Williams, J. C., Krambeck, A. E., & Lingeman, J. E. (2015). Lithotripter outcomes in a community practice setting: Comparison of an electromagnetic and an electrohydraulic lithotripter. *Journal of Urology*. <https://doi.org/10.1016/j.juro.2014.09.117>
- Cai, Z., Falkensammer, F., Andrukhov, O., Chen, J., Mittermayr, R., & Rausch-Fan, X. (2016). Effects of Shock Waves on Expression of IL-6, IL-8, MCP-1, and TNF- α Expression by Human Periodontal Ligament Fibroblasts: An In Vitro Study. *Medical Science Monitor : International Medical Journal of Experimental and Clinical Research*, 22, 914–921. <https://doi.org/10.12659/MSM.897507>
- Chen, R. F., Chang, C. H., Wang, C. T., Yang, M. Y., Wang, C. J., & Kuo, Y. R. (2019). Modulation of vascular endothelial growth factor and mitogen-activated protein kinase-related pathway involved in extracorporeal shockwave therapy accelerate diabetic wound healing. *Wound Repair and Regeneration*. <https://doi.org/10.1111/wrr.12686>
- Chen, R.-F., Lin, Y.-N., Liu, K.-F., Wang, C.-T., Ramachandran, S., Wang, C.-J., & Kuo, Y.-R. (2020). The Acceleration of Diabetic Wound Healing by Low-Intensity Extracorporeal Shockwave Involves in the GSK-3 β Pathway. *Biomedicines*. <https://doi.org/10.3390/biomedicines9010021>

- Chen, R. F., Yang, M. Y., Wang, C. J., Wang, C. T., & Kuo, Y. R. (2020). Proteomic analysis of peri-wounding tissue expressions in extracorporeal shock wave enhanced diabetic wound healing in a streptozotocin-induced diabetes model. *International Journal of Molecular Sciences*. <https://doi.org/10.3390/ijms21155445>
- Chen, R., Lin, Y., Liu, K., Lee, C., Hu, C., Wang, C., Wang, C., & Kuo, Y. (2023). Compare the effectiveness of extracorporeal shockwave and hyperbaric oxygen therapy on enhancing wound healing in a <scp>streptozotocin-induced</scp> diabetic rodent model. *The Kaohsiung Journal of Medical Sciences*. <https://doi.org/10.1002/kjm2.12746>
- Chuangsuwanich, A., Kongkunnawat, N., Kamanamool, M., Maipeng, G., Kamanamool, N., & Tonaree, W. (2022). Extracorporeal Shock Wave Therapy for Hypertrophic Scars. *Archives of Plastic Surgery*, 49(04), 554–560. <https://doi.org/10.1055/s-0042-1751027>
- Dahm, F., Feichtinger, X., Vallant, S.-M., Haffner, N., Schaden, W., Fialka, C., & Mittermayr, R. (2021). High-energy extracorporeal shockwave therapy in humeral delayed and non-unions. *Eur J Trauma Emerg Surg., online ahe*. <https://doi.org/10.1007/s00068-021-01782-1>
- Davis, T. A., Stojadinovic, A., Anam, K., Amare, M., Naik, S., Peoples, G. E., Tadaki, D., & Elster, E. A. (2009). Extracorporeal shock wave therapy suppresses the early proinflammatory immune response to a severe cutaneous burn injury. *Int Wound J*, 6(1), 11–21. <https://doi.org/10.1111/j.1742-481X.2008.00540.x>
- de Girolamo, L., Stanco, D., Galliera, E., Viganò, M., Lovati, A. B., Marazzi, M. G., Romeo, P., & Sansone, V. (2014). Soft-Focused Extracorporeal Shock Waves Increase the Expression of Tendon-Specific Markers and the Release of Anti-inflammatory Cytokines in an Adherent Culture Model of Primary Human Tendon Cells. *Ultrasound in Medicine & Biology*, 40(6), 1204–1215. <https://doi.org/10.1016/j.ultrasmedbio.2013.12.003>
- Delgado-Márquez, A. M., Carmona, M., Vanaclocha, F., & Postigo, C. (2015). Effectiveness of extracorporeal shock wave lithotripsy to treat dystrophic calcinosis cutis ulcers. In *Actas Dermo-Sifiliograficas*. <https://doi.org/10.1016/j.adengl.2014.12.004>
- Demir, O., & Arici, N. (2021). Dose-related effects of extracorporeal shock waves on orthodontic tooth movement in rabbits. *Scientific Reports*. <https://doi.org/10.1038/s41598-021-82997-5>
- Dumfarth, J., Zimpfer, D., Vögele-Kadletz, M., Holfeld, J., Sihorsch, F., Schaden, W., Czerny, M., Aharinejad, S., Wolner, E., & Grimm, M. (2008). Prophylactic Low-Energy Shock Wave Therapy Improves Wound Healing After Vein Harvesting for Coronary Artery Bypass Graft Surgery: A Prospective, Randomized Trial. *The Annals of Thoracic Surgery*, 86(6), 1909–1913. <https://doi.org/10.1016/j.athoracsur.2008.07.117>
- Falkensammer, F., Arnhart, C., Krall, C., Schaden, W., Freudenthaler, J., & Bantleon, H. P. (2014). Impact of extracorporeal shock wave therapy (ESWT) on orthodontic tooth movement—a randomized clinical trial. *Clinical Oral Investigations*. <https://doi.org/10.1007/s00784-014-1199-0>
- Falkensammer, F., Rausch-Fan, X., Arnhart, C., Krall, C., Schaden, W., & Freudenthaler, J. (2014). Impact of extracorporeal shock-wave therapy on the stability of temporary anchorage devices in adults: A single-center, randomized, placebo-controlled clinical trial. *American Journal of Orthodontics and Dentofacial Orthopedics*. <https://doi.org/10.1016/j.ajodo.2014.06.008>



- Falkensammer, F., Rausch-Fan, X., Schaden, W., Kivaranovic, D., & Freudenthaler, J. (2015). Impact of extracorporeal shockwave therapy on tooth mobility in adult orthodontic patients: A randomized single-center placebo-controlled clinical trial. *Journal of Clinical Periodontology*. <https://doi.org/10.1111/jcpe.12373>
- Falkensammer, F., Schaden, W., Krall, C., Freudenthaler, J., & Bantleon, H. P. (2016). Effect of extracorporeal shockwave therapy (ESWT) on pulpal blood flow after orthodontic treatment: a randomized clinical trial. *Clinical Oral Investigations*. <https://doi.org/10.1007/s00784-015-1525-1>
- Fallnhauser, T., Wilhelm, P., Priol, A., & Windhofer, C. (2019). Extracorporeal Shockwave Therapy for the treatment of scaphoid delayed union and nonunion: A retrospective analysis examining the rate of consolidation and further outcome variables. *Handchirurgie Mikrochirurgie Plastische Chirurgie*. <https://doi.org/10.1055/a-0914-2963>
- Fansa, A., Talsania, A. J., Kennedy, J. G., & O'Malley, M. J. (2020). Efficacy of Unfocused Medium-Intensity Extracorporeal Shock Wave Therapy (MI-ESWT) for Plantar Fasciitis. *The Journal of Foot and Ankle Surgery*. <https://doi.org/10.1053/j.jfas.2020.08.027>
- Feichtinger, X., Heimel, P., Tangl, S., Keibl, C., Nürnberger, S., Schanda, J. E., Hercher, D., Kocijan, R., Redl, H., Grillari, J., Fialka, C., & Mittermayr, R. (2022). Improved biomechanics in experimental chronic rotator cuff repair after shockwaves is not reflected by bone microarchitecture. *PLoS ONE*. <https://doi.org/10.1371/journal.pone.0262294>
- Feichtinger, X., Monforte, X., Keibl, C., Hercher, D., Schanda, J., Teuschl, A. H., Muschitz, C., Redl, H., Fialka, C., & Mittermayr, R. (2019). Substantial Biomechanical Improvement by Extracorporeal Shockwave Therapy After Surgical Repair of Rodent Chronic Rotator Cuff Tears. *American Journal of Sports Medicine*. <https://doi.org/10.1177/0363546519854760>
- Fleckenstein, J., Fritton, M., Himmelreich, H., & Banzer, W. (2017). Effect of a Single Administration of Focused Extracorporeal Shock Wave in the Relief of Delayed-Onset Muscle Soreness: Results of a Partially Blinded Randomized Controlled Trial. *Archives of Physical Medicine and Rehabilitation*, 98(5), 923–930. <https://doi.org/10.1016/j.apmr.2016.11.013>
- Furia, J. P., Juliano, P. J., Wade, A. M., Schaden, W., & Mittermayr, R. (2010). Shock wave therapy compared with intramedullary screw fixation for nonunion of proximal fifth metatarsal metaphyseal-diaphyseal fractures. *Journal of Bone and Joint Surgery - Series A*, 92(4), 846–854. <https://doi.org/10.2106/JBJS.I.00653>
- Ginini, J. G., Emodi, O., Sabo, E., Maor, G., Shilo, D., & Rachmiel, A. (2019). Effects of Timing of Extracorporeal Shock Wave Therapy on Mandibular Distraction Osteogenesis: An Experimental Study in a Rat Model. *Journal of Oral and Maxillofacial Surgery*. <https://doi.org/10.1016/j.joms.2018.07.018>
- Göl, E. B., Özkan, N., Bereket, C., & Önger, M. E. (2020). Extracorporeal Shock-Wave Therapy or Low-Level Laser Therapy: Which is More Effective in Bone Healing in Bisphosphonate Treatment? *The Journal of Craniofacial Surgery*. <https://doi.org/10.1097/SCS.00000000000006506>
- Gollmann-Tepeköylü, C., Grimm, M., Holfeld, J., Gollmann-tepeköylü, C., Nägele, F., Graber, M., Pölzl, L., Lobenwein, D., Hirsch, J., An, A., Irschick, R., Röhrs, B., Kremser, C., Hackl, H., Huber, R., Venezia, S., Hercher, D., Fritsch, H., Bonaros, N., ... Holfeld, J. (2020). Shock waves promote spinal cord repair via TLR3. *JCI Insight*, 5(15).

- Gollmann-Tepeköylü, C., Lobenwein, D., Theurl, M., Primessnig, U., Lener, D., Kirchmair, E., Mathes, W., Graber, M., Pölzl, L., An, A., Koziel, K., Pechriggl, E., Voelkl, J., Paulus, P., Schaden, W., Grimm, M., Kirchmair, R., & Holfeld, J. (2018). Shock wave therapy improves cardiac function in a model of chronic ischemic heart failure: Evidence for a mechanism involving vegf signaling and the extracellular matrix. *Journal of the American Heart Association*. <https://doi.org/10.1161/JAHA.118.010025>
- Gollmann-Tepeköylü, C., Pölzl, L., Graber, M., Hirsch, J., Nägele, F., Lobenwein, D., Hess, M. W., Blumer, M. J., Kirchmair, E., Zipperle, J., Hromada, C., Mühleder, S., Hackl, H., Hermann, M., Al Khamisi, H., Förster, M., Lichtenauer, M., Mittermayr, R., Paulus, P., ... Holfeld, J. (2019). miR-19a-3p containing exosomes improve function of ischaemic myocardium upon shock wave therapy. *Cardiovascular Research*. <https://doi.org/10.1093/cvr/cvz209>
- Gstoettner, C., Salminger, S., Sturma, A., Moser, V., Hausner, T., Brånemark, R., & Aszmann, O. C. (2020). Successful salvage via re-osseointegration of a loosened implant in a patient with transtibial amputation. *Prosthetics and Orthotics International*. <https://doi.org/10.1177/0309364620953985>
- Haffner, N., Antonic, V., Smolen, D., Slezak, P., Schaden, W., Mittermayr, R., & Stojadinovic, A. (2016). Extracorporeal shockwave therapy (ESWT) ameliorates healing of tibial fracture non-union unresponsive to conventional therapy. *Injury*, 47(7), 1506–1513. <https://doi.org/10.1016/j.injury.2016.04.010>
- Hausner, T., Pajer, K., Halat, G., Hopf, R., Schmidhammer, R., Redl, H., & Nógrádi, A. (2012). Improved rate of peripheral nerve regeneration induced by extracorporeal shock wave treatment in the rat. *Experimental Neurology*, 236(2), 363–370. <https://doi.org/10.1016/j.expneurol.2012.04.019>
- Hayon, S., Panken, E. J., & Bennett, N. E. (2023). Variations in Low Intensity Shockwave Treatment Protocols for Erectile Dysfunction: A Review of the Literature and Guide to Offering Treatment. *The World Journal of Men's Health*, 41. <https://doi.org/10.5534/wjmh.230105>
- Hazan-Molina, H., Aizenbud, I., Kaufman, H., Teich, S., & Aizenbud, D. (2016). The influence of shockwave therapy on orthodontic tooth movement induced in the rat. In *Advances in Experimental Medicine and Biology* (Vol. 878, pp. 57–65). https://doi.org/10.1007/5584_2015_179
- Hazan-Molina, H., Gabet, Y., Aizenbud, I., Aizenbud, N., & Aizenbud, D. (2022). Orthodontic force and extracorporeal shock wave therapy: Assessment of orthodontic tooth movement and bone morphometry in a rat model. *Archives of Oral Biology*. <https://doi.org/10.1016/j.archoralbio.2021.105327>
- Hazan-Molina, H., Reznick, A. Z., Kaufman, H., & Aizenbud, D. (2012). Assessment of IL-1 β and VEGF concentration in a rat model during orthodontic tooth movement and extracorporeal shock wave therapy. *Archives of Oral Biology*, 58(2), 142–150. <https://doi.org/10.1016/j.archoralbio.2012.09.012>
- Hazan-Molina, H., Reznick, A. Z., Kaufman, H., & Aizenbud, D. (2015). Periodontal cytokines profile under orthodontic force and extracorporeal shock wave stimuli in a rat model. *Journal of Periodontal Research*, 50(3), 389–396. <https://doi.org/10.1111/jre.12218>



- Hercher, D., Redl, H., & Schuh, C. M. A. P. (2020). Motor and sensory Schwann cell phenotype commitment is diminished by extracorporeal shockwave treatment in vitro. *Journal of the Peripheral Nervous System*. <https://doi.org/10.1111/jns.12365>
- Hirsch, J., Nägele, F., Pölzl, L., Graber, M., Grimm, M., Lechner, S., Schweiger, V., Gollmann-Tepeköylü, C., & Holfeld, J. (2021). A standardized murine model of extracorporeal shockwave therapy induced soft tissue regeneration. *Journal of Visualized Experiments*. <https://doi.org/10.3791/62338>
- Holfeld, J., Tepekoylu, C., Blunder, S., Lobenwein, D., Kirchmair, E., Dietl, M., Kozaryn, R., Lener, D., Theurl, M., Paulus, P., Kirchmair, R., & Grimm, M. (2014). Low energy shock wave therapy induces angiogenesis in acute hind-limb ischemia via VEGF receptor 2 phosphorylation. *PLoS One*, 9(8), e103982. <https://doi.org/10.1371/journal.pone.0103982>
- Holfeld, J., Tepeköylü, C., Kozaryn, R., Mathes, W., Grimm, M., & Paulus, P. (2014). Shock wave application to cell cultures. *Journal of Visualized Experiments: JoVE*. <https://doi.org/10.3791/51076>
- Holfeld, J., Tepeköylü, C., Kozaryn, R., Urbschat, A., Zacharowski, K., Grimm, M., & Paulus, P. (2014). Shockwave therapy differentially stimulates endothelial cells: Implications on the control of inflammation via toll-like receptor 3. *Inflammation*, 37(1), 65–70. <https://doi.org/10.1007/s10753-013-9712-1>
- Holfeld, J., Tepeköylü, C., Reissig, C., Lobenwein, D., Scheller, B., Kirchmair, E., Kozaryn, R., Albrecht-Schgoer, K., Krapf, C., Zins, K., Urbschat, A., Zacharowski, K., Grimm, M., Kirchmair, R., & Paulus, P. (2016). Toll-like receptor 3 signalling mediates angiogenic response upon shock wave treatment of ischaemic muscle. *Cardiovascular Research*, 109(2), 331–343. <https://doi.org/10.1093/cvr/cvv272>
- Holfeld, J., Zimpfer, D., Albrecht-Schgoer, K., Stojadinovic, A., Paulus, P., Dumfarth, J., Thomas, A., Lobenwein, D., Tepeköylü, C., Rosenhek, R., Schaden, W., Kirchmair, R., Aharinejad, S., & Grimm, M. (2016). Epicardial shock-wave therapy improves ventricular function in a porcine model of ischaemic heart disease. *Journal of Tissue Engineering and Regenerative Medicine*, 10(12), 1057–1064. <https://doi.org/10.1002/term.1890>
- Holsapple, J. S., Cooper, B., Berry, S. H., Staniszevska, A., Dickson, B. M., Taylor, J. A., Bachoo, P., & Wilson, H. M. (2021). Low intensity shockwave treatment modulates macrophage functions beneficial to healing chronic wounds. *International Journal of Molecular Sciences*. <https://doi.org/10.3390/ijms22157844>
- Hsu, C. J., Wang, D. Y., Tseng, K. F., Fong, Y. C., Hsu, H. C., & Jim, Y. F. (2008). Extracorporeal shock wave therapy for calcifying tendinitis of the shoulder. *Journal of Shoulder and Elbow Surgery*, 17(1), 55–59. <https://doi.org/10.1016/j.jse.2007.03.023>
- Joos, E., Vultureanu, I., Nonneman, T., & Adriaenssens, N. (2020). Low-Energy Extracorporeal Shockwave Therapy as a Therapeutic Option for Patients with a Secondary Late-Stage Fibro-Lymphedema After Breast Cancer Therapy: *Lymphat Res Biol*, online ahe(00), 1–6. <https://doi.org/10.1089/lrb.2020.0033>
- Kim, J., Soubra, A., Kim, H., Greenberg, J., Ottaiano, N., Morenas, R., Chacko, B., Wisen, W., Fatima, N., Dick, B., Halat, S., Almajed, W., Raheem, O., Abdel-Mageed, A., & Hellstrom, W. (2022). 63 Evaluating Different Low-intensity Extracorporeal Shockwave Therapy Intensities in the

- Treatment of Peyronie's Disease in a Rat Model. *The Journal of Sexual Medicine*, 19(Supplement_1), S33–S33. <https://doi.org/10.1016/j.jsxm.2022.01.075>
- Koolen, M. K. E., Kruyt, M. C., Öner, F. C., Schaden, W., Weinans, H., & van der Jagt, O. P. (2019). Effect of unfocused extracorporeal shockwave therapy on bone mineral content of twelve distal forearms of postmenopausal women: a clinical pilot study. *Archives of Osteoporosis*. <https://doi.org/10.1007/s11657-019-0650-x>
- Koolen, M. K. E., Kruyt, M. C., Zadpoor, A. A., Öner, F. C., Weinans, H., & van der Jagt, O. P. (2017). Optimization of screw fixation in rat bone with extracorporeal shock waves. *Journal of Orthopaedic Research*. <https://doi.org/10.1002/jor.23615>
- Kuo, Y. R., Wang, C. T., Wang, F. S., Chiang, Y. C., & Wang, C. J. (2009). Extracorporeal shock-wave therapy enhanced wound healing via increasing topical blood perfusion and tissue regeneration in a rat model of STZ-induced diabetes. *Wound Repair and Regeneration*, 17(4), 522–530. <https://doi.org/10.1111/j.1524-475X.2009.00504.x>
- Larking, A. M., Dupont, S., Clinton, M., Hardy, M., & Andrews, K. (2010). Randomized control of extracorporeal shock wave therapy versus placebo for chronic decubitus ulceration. *Clinical Rehabilitation*, 24(3), 222–229. <https://doi.org/10.1177/0269215509346083>
- Li, H., Matheu, M. P., Sun, F., Wang, L., Sanford, M. T., Ning, H., Banie, L., Lee, Y. C., Xin, Z., Guo, Y., Lin, G., & Lue, T. F. (2016). Low-energy Shock Wave Therapy Ameliorates Erectile Dysfunction in a Pelvic Neurovascular Injuries Rat Model. *The Journal of Sexual Medicine*, 13(1), 22–32. <https://doi.org/10.1016/j.jsxm.2015.11.008>
- Link, K. A., Koenig, J. B., Silveira, A., Plattner, B. L., & Lillie, B. N. (2013). Effect of unfocused extracorporeal shock wave therapy on growth factor gene expression in wounds and intact skin of horses. *American Journal of Veterinary Research*, 74(2), 324–332. <https://doi.org/10.2460/ajvr.74.2.324>
- Lobenwein, D., Huber, R., Kerbler, L., Gratl, A., Wipperf, S., Gollmann-Tepeköylü, C., & Holfeld, J. (2022). Neuronal Pre-and Postconditioning via Toll-like Receptor 3 Agonist or Extracorporeal Shock Wave Therapy as New Treatment Strategies for Spinal Cord Ischemia: An In Vitro Study. *Journal of Clinical Medicine*, 11(8). <https://doi.org/10.3390/jcm11082115>
- Lobenwein, D., Tepekoylu, C., Kozaryn, R., Pechriggl, E. J., Bitsche, M., Graber, M., Fritsch, H., Semsroth, S., Stefanova, N., Paulus, P., Czerny, M., Grimm, M., & Holfeld, J. (2015). Shock Wave Treatment Protects From Neuronal Degeneration via a Toll-Like Receptor 3 Dependent Mechanism: Implications of a First-Ever Causal Treatment for Ischemic Spinal Cord Injury. *Journal of the American Heart Association*, 4(10). <https://doi.org/10.1161/JAHA.115.002440>
- Marcus, B. (2020). Extracorporeal Shock Wave Therapy (Eswt) For the Treatment of Chronic , Non-Healing Wounds : A Case Series. *Stem Cells Regen Med.*, 4(2), 1–7.
- Mirza, N. (2017). The Concept of Spark Wave Therapy (Swt) Assisted Penile Augmentation. *The Journal of Sexual Medicine*. <https://doi.org/10.1016/j.jsxm.2017.04.565>
- Mittermayr, R., Haffner, N., Eder, S., Flatscher, J., Schaden, W., Slezak, P., & Slezak, C. (2022). Safe and Effective Treatment of Compromised Clavicle Fracture of the Medial and Lateral Third Using Focused Shockwaves. *Journal of Clinical Medicine*, 11(7). <https://doi.org/10.3390/jcm11071988>



- Mittermayr R, Haffner N, Feichtinger X, S. W. (2021). The role of shockwaves in the enhancement of bone repair - from basic principles to clinical application. *Injury*, 50020-1383. <https://doi.org/10.1016/j.injury.2021.02.081>
- Mittermayr, R., Hartinger, J., Antonic, V., Meinl, A., Pfeifer, S., Stojadinovic, A., Schaden, W., & Redl, H. (2011). Extracorporeal Shock Wave Therapy (ESWT) Minimizes Ischemic Tissue Necrosis Irrespective of Application Time and Promotes Tissue Revascularization by Stimulating Angiogenesis. *Annals of Surgery*, 253(5), 1024–1032. <https://doi.org/10.1097/SLA.0b013e3182121d6e>
- Monclús, P., Bosque, M., Margalef, R., Colomina, M. T., Valderrama-Canales, F. J., Just, L., & Santafé, M. M. (2023). Shock waves as treatment of mouse myofascial trigger points. *Pain Practice*. <https://doi.org/10.1111/papr.13237>
- Novak, K. F., Govindaswami, M., Ebersole, J. L., Schaden, W., House, N., & Novak, M. J. (2008). Effects of low-energy shock waves on oral bacteria. *Journal of Dental Research*, 87, 928–931. <https://doi.org/10.1177/154405910808701009>
- Onger, M. E., Bereket, C., Sener, I., Ozkan, N., Senel, E., & Polat, A. V. (2017). Is it possible to change of the duration of consolidation period in the distraction osteogenesis with the repetition of extracorporeal shock waves? *Medicina Oral, Patologia Oral y Cirugia Bucal*. <https://doi.org/10.4317/medoral.21556>
- Ottomann, C., Hartmann, B., Tyler, J., Maier, H., Thiele, R., Schaden, W., & Stojadinovic, A. (2010). Prospective randomized trial of accelerated re-epithelization of skin graft donor sites using extracorporeal shock wave therapy. *Journal of the American College of Surgeons*. <https://doi.org/10.1016/j.jamcollsurg.2010.05.012>
- Ottomann, C., Stojadinovic, A., Lavin, P. T., Gannon, F. H., Heggeness, M. H., Thiele, R., Schaden, W., & Hartmann, B. (2012). Prospective Randomized Phase II Trial of Accelerated Reepithelialization of Superficial Second-Degree Burn Wounds Using Extracorporeal Shock Wave Therapy. *Annals of Surgery*, 255(1), 23–29. <https://doi.org/10.1097/SLA.0b013e318227b3c0>
- Ottomann et al. (2009). Accelerated reepithelisation of a IIb ° scald through extracorporeal shock wave therapy. *Reepithelisierung, Beschleunigte Fallvorstellung, Stoßwellentherapie*, 3, 1–4.
- Ottomann MD, C., & Antonic PhD, V. (2015). In Vitro Effects of Extracorporeal Shockwave Therapy (ESWT) on Proliferation and Metabolic Activity of Adult Human Keratinocytes. *Journal of Bioengineering & Biomedical Science*. <https://doi.org/10.4172/2155-9538.1000171>
- Özkan, E., Bereket, M. C., Önger, M. E., & Polat, A. V. (2018). The effect of unfocused extracorporeal shock wave therapy on bone defect healing in diabetics. *Journal of Craniofacial Surgery*. <https://doi.org/10.1097/SCS.00000000000004303>
- Özkan, E., Bereket, M. C., Şenel, E., & Önger, M. E. (2019). Effect of electrohydraulic extracorporeal shockwave therapy on the repair of bone defects grafted with particulate allografts. *Journal of Craniofacial Surgery*. <https://doi.org/10.1097/SCS.00000000000005213>
- Özkan, E., Şenel, E., Bereket, M. C., & Önger, M. E. (2023). The effect of shock waves on mineralization and regeneration of distraction zone in osteoporotic rabbits. *Annals of Medicine*, 55(1), 1346–1354. <https://doi.org/10.1080/07853890.2023.2192958>

- Pishchalnikov, Y. a, McAteer, J. a, Williams, J. C., Connors, B. a, Handa, R. K., Lingeman, J. E., & Evan, A. P. (2013). Evaluation of the LithoGold LG-380 lithotripter: in vitro acoustic characterization and assessment of renal injury in the pig model. *Journal of Endourology / Endourological Society*, 27(5), 631–639. <https://doi.org/10.1089/end.2012.0611>
- Pölzl, L., Nägele, F., Hirsch, J., Graber, M., Grimm, M., Gollmann-Tepeköylü, C., & Holfeld, J. (2020). Exosome isolation after in vitro shock wave therapy. *Journal of Visualized Experiments*. <https://doi.org/10.3791/61508>
- Pölzl L, Nägele F, Hirsch J, Graber M, Lobenwein D, Kirchmair E, Huber R, Dorfmueller C, Lechner S, Schäfer G, Hermann M, Fritsch H, Tancevski I, Grimm M, Holfeld J, G.-T. C. (2021). Defining a therapeutic range for regeneration of ischemic myocardium via shock waves. *Sci Rep.*, 11(1), 409. <https://doi.org/10.1038/s41598-020-79776-z>
- Porst, H. (2020). Review of the Current Status of Low Intensity Extracorporeal Shockwave Therapy (Li-ESWT) in Erectile Dysfunction (ED), Peyronie's Disease (PD), and Sexual Rehabilitation After Radical Prostatectomy With Special Focus on Technical Aspects of the Different . In *Sexual Medicine Reviews*. <https://doi.org/10.1016/j.sxmr.2020.01.006>
- Priglinger, E., Schuh, C. M. A. P., Steffenhagen, C., Wurzer, C., Maier, J., Nuernberger, S., Holnthoner, W., Fuchs, C., Suessner, S., Rünzler, D., Redl, H., & Wolbank, S. (2017). Improvement of adipose tissue-derived cells by low-energy extracorporeal shock wave therapy. *Cytotherapy*, 19(9), 1079–1095. <https://doi.org/10.1016/j.jcyt.2017.05.010>
- Qiu, X., Lin, G., Xin, Z., Ferretti, L., Zhang, H., Lue, T. F., & Lin, C.-S. (2013). Effects of low-energy shockwave therapy on the erectile function and tissue of a diabetic rat model. *The Journal of Sexual Medicine*, 10(3), 738–746. <https://doi.org/10.1111/jsm.12024>
- Quadlbauer, S., Pezzei, C., Beer, T., Jurkowitsch, J., Keuchel, T., Schlintner, C., Schaden, W., Hausner, T., & Leixnering, M. (2019). Treatment of scaphoid waist nonunion by one, two headless compression screws or plate with or without additional extracorporeal shockwave therapy. *Archives of Orthopaedic and Trauma Surgery*. <https://doi.org/10.1007/s00402-018-3087-6>
- Quadlbauer, S., Pezzei, Ch., Jurkowitsch, J., Beer, T., Moser, V., Rosenauer, R., Salminger, S., Hausner, T., & Leixnering, M. (2023). Double screw versus angular stable plate fixation of scaphoid waist nonunions in combination with intraoperative extracorporeal shockwave therapy (ESWT). *Archives of Orthopaedic and Trauma Surgery*. <https://doi.org/10.1007/s00402-023-04806-0>
- Ramon, S., Lucenteforte, G., Alentorn-Geli, E., Steinbacher, G., Unzurrunzaga, R., Álvarez-Díaz, P., Barastegui, D., Grossi, S., Sala, E., Martinez-De la Torre, A., Mangano, G. R. A., Cuscó, X., Rius, M., Ferré-Aniorte, A., & Cugat, R. (2023). Shockwave Treatment vs Surgery for Proximal Fifth Metatarsal Stress Fractures in Soccer Players: A Pilot Study. *Foot & Ankle International*. <https://doi.org/10.1177/10711007231199094>
- Rohringer, S., Holnthoner, W., Hackl, M., Weihs, A. M., Rünzler, D., Skalicky, S., Karbiener, M., Scheideler, M., Pröll, J., Gabriel, C., Schweighofer, B., Gröger, M., Spittler, A., Grillari, J., & Redl, H. (2014). Molecular and cellular effects of in vitro shockwave treatment on lymphatic endothelial cells. *PLoS ONE*, 9(12). <https://doi.org/10.1371/journal.pone.0114806>
- Saffon, J. P., Martínez, J. M., Sandoval, C., & Corredor, H. A. (2017). Effectiveness of Shock Wave Therapy: Implementation of a Soft Wide Focus Applicator in Patients With Erectile Dysfunction. *The Journal of Sexual Medicine*. <https://doi.org/10.1016/j.jsxm.2017.04.567>



- Saggini, R., Fioramonti, P., Bellomo, R. G., Di Stefano, A., Scarcello, L., Di Pancrazio, L., Iodice, P., Saggini, A., & Scuderi, N. (2013). Chronic ulcers: Treatment with unfocused extracorporeal shock waves. *European Journal of Inflammation*. <https://doi.org/10.1177/1721727X1301100219>
- Saggini, R., Saggini, A., Carmignano, S., Palermo, T., Barassi, G., Onesti, M., Bellomo, R., & Scuderi, N. (2016). The Role of Extracorporeal Shock Wave Therapy and Manual Lymphatic Drainage in Chronic Ulcers Treatment. *International Journal of Pharmaceutical Sciences Research*. <https://doi.org/10.15344/2394-1502/2016/119>
- Saggini, R., Saggini, A., Spagnoli, A. M., Dodaj, I., Cigna, E., Maruccia, M., Soda, G., Bellomo, R. G., & Scuderi, N. (2015). Extracorporeal shock wave therapy: An emerging treatment modality for retracting scars of the hands. *Ultrasound in Medicine and Biology*, 42(1), 185–195. <https://doi.org/10.1016/j.ultrasmedbio.2015.07.028>
- Sağır, D., Bereket, C., Onger, M. E., Bakhit, N., Keskin, M., & Ozkan, E. (2019). Efficacy of Extracorporeal Shockwaves Therapy on Peripheral Nerve Regeneration. *The Journal of Craniofacial Surgery*. <https://doi.org/10.1097/SCS.00000000000005671>
- Sansone, V., D'Agostino, M. C., Bonora, C., Sizzano, F., De Girolamo, L., & Romeo, P. (2012). Early angiogenic response to shock waves in a three-dimensional model of human microvascular endothelial cell culture (HMEC-1). *Journal of Biological Regulators and Homeostatic Agents*, 26(1), 29–37.
- Sathishkumar, S., Meka, A., Dawson, D., House, N., Schaden, W., Novak, M. J., Ebersole, J. L., & Kesavalu, L. (2008). Extracorporeal Shock Wave Therapy Induces Alveolar Bone Regeneration. *Journal of Dental Research*, 87(7), 687–691. <https://doi.org/10.1177/154405910808700703>
- Schaden, W., Fischer, A., & Sailer, A. (2001). Extracorporeal Shock Wave Therapy of Nonunion or Delayed Osseous Union. *Clinical Orthopaedics and Related Research*, 387, 90–94. <https://doi.org/10.1097/00003086-200106000-00012>
- Schaden, W., Thiele, R., Kolpl, C., Pusch, M., Nissan, A., Attinger, C. E., Maniscalco-Theberge, M. E., Peoples, G. E., Elster, E. A., & Stojadinovic, A. (2007). Shock wave therapy for acute and chronic soft tissue wounds: a feasibility study. *Journal of Surgical Research*, 143(1), 1–12. <https://doi.org/10.1016/j.jss.2007.01.009>
- Schuh, C. M. A. P., Heher, P., Weihs, A. M., Banerjee, A., Fuchs, C., Gabriel, C., Wolbank, S., Mittermayr, R., Redl, H., Rünzler, D., & Teuschl, A. H. (2014). In vitro extracorporeal shock wave treatment enhances stemness and preserves multipotency of rat and human adipose-derived stem cells. *Cytotherapy*, 16(12), 1666–1678. <https://doi.org/10.1016/j.jcyt.2014.07.005>
- Schuh, C. M. A. P., Hercher, D., Stainer, M., Hopf, R., Teuschl, A. H., Schmidhammer, R., & Redl, H. (2016). Extracorporeal shockwave treatment: A novel tool to improve Schwann cell isolation and culture. *Cytotherapy*, 18(6), 760–770. <https://doi.org/10.1016/j.jcyt.2016.03.002>
- Senel, E., Ozkan, E., Bereket, M. C., & Gungor, M. E. (2019). The assessment of new bone formation induced by unfocused extracorporeal shock wave therapy applied on pre-surgical phase of distraction osteogenesis. *European Oral Research*. <https://doi.org/10.26650/eor.20190041>
- Shafshak, T., & Amer, M. A. (2023). Focused extracorporeal shockwave therapy for youth sports-related apophyseal injuries: case series. *Journal of Orthopaedic Surgery and Research*, 18(1), 616. <https://doi.org/10.1186/s13018-023-04065-0>

- Shoskes, D., & Mooney, B. (2018). 329 Case series of low intensity shock wave therapy for men with chronic prostatitis/chronic pelvic pain syndrome. *The Journal of Sexual Medicine*. <https://doi.org/10.1016/j.jsxm.2018.04.292>
- Silveira A, Koenig JB, Arroyo LG, Trout D, Moens NM, LaMarre J, B. A. (2010). Effects of unfocused extracorporeal shock wave therapy on healing of wounds of the distal portion of the forelimb in horses. *Am J Vet Res*, 71(2), 229–234.
- Slezak, C., Anderson, K., Hillock, T., Miller, M., Dungel, P., Kopp, O., Sterflinger, K., & Slezak, P. (2022). Shockwaves Increase In Vitro Resilience of *Rhizopus oryzae* Biofilm under Amphotericin B Treatment. *International Journal of Molecular Sciences*, 23(16), 9226. <https://doi.org/10.3390/ijms23169226>
- Slezak, C., Flatscher, J., & Slezak, P. (2022). A Comparative Feasibility Study for Transcranial Extracorporeal Shock Wave Therapy. *Biomedicines*, 10(6), 1457. <https://doi.org/10.3390/biomedicines10061457>
- Slezak, C., Rose, R., Jilge, J. M., Nuster, R., Hercher, D., & Slezak, P. (2022). Physical considerations for in vitro eswt research design. *International Journal of Molecular Sciences*. <https://doi.org/10.3390/ijms23010313>
- Sorg, H., Zwetich, I., Tilkorn, D. J., Kolbenschlag, J., Hauser, J., Goertz, O., Spindler, N., Langer, S., & Ring, A. (2021). Effects of extracorporeal shock waves on microcirculation and angiogenesis in the in vivo wound model of the diver box. *European Surgical Research*. <https://doi.org/10.1159/000515737>
- Soubra, A., Kim, J., Kim, H., Greenberg, J., Ottaiano, N., Morenas, R., Chacko, B., Wisen, W., Fatima, N., Dick, B., Halat, S., Almajed, W., Raheem, O., Abdel-Mageed, A., & Hellstrom, W. (2022). 53 Low-intensity Extracorporeal Shockwave Therapy as an Adjunct to Xiaflex® in the Treatment of Peyronie's Disease. *The Journal of Sexual Medicine*, 19(Supplement_1), S28–S28. <https://doi.org/10.1016/j.jsxm.2022.01.065>
- Stojadinovic, A., Elster, E. A., Anam, K., Tadaki, D., Amare, M., Zins, S., & Davis, T. A. (2008). Angiogenic response to extracorporeal shock wave treatment in murine skin isografts. *Angiogenesis*, 11(4), 369–380. <https://doi.org/10.1007/s10456-008-9120-6>
- Stojadinovic, A., Elster, E., & Potter, B. (2010). Combat Wound Initiative Program. *Military Medicine*, 175(7), 18–24.
- Stojadinovic, A., Potter, B. K., Eberhardt, J., Shawen, S. B., Andersen, R. C., Forsberg, J. A., Shwery, C., Ester, E. A., & Schaden, W. (2011). Development of a prognostic naïve Bayesian classifier for successful treatment of nonunions. *Journal of Bone and Joint Surgery - Series A*. <https://doi.org/10.2106/JBJS.I.01649>
- Sukubo, N. G., Tibalt, E., Respizzi, S., Locati, M., & d'Agostino, M. C. (2015). Effect of shock waves on macrophages: A possible role in tissue regeneration and remodeling. *International Journal of Surgery*, 24, 124–130. <https://doi.org/10.1016/j.ijssu.2015.07.719>
- Tepeköylü, C., Lobenwein, D., Blunder, S., Kozaryn, R., Dietl, M., Ritschl, P., Pechriggl, E. J., Blumer, M. J. F., Bitsche, M., Schistek, R., Kotsch, K., Fritsch, H., Grimm, M., & Holfeld, J. (2015). Alteration of inflammatory response by shock wave therapy leads to reduced calcification of decellularized



- aortic xenografts in mice. *European Journal of Cardio-Thoracic Surgery*, 47(3), e80–e90. <https://doi.org/10.1093/ejcts/ezu428>
- Tepeköylü, C., Lobenwein, D., Urbschat, A., Graber, M., Pechriggl, E. J., Fritsch, H., Paulus, P., Grimm, M., & Holfeld, J. (2018). Shock wave treatment after hindlimb ischaemia results in increased perfusion and M2 macrophage presence. *Journal of Tissue Engineering and Regenerative Medicine*, 12(1), e486–e494. <https://doi.org/10.1002/term.2317>
- Tepeköylü, C., Primessnig, U., Pölzl, L., Graber, M., Lobenwein, D., Nägele, F., Kirchmair, E., Pechriggl, E., Grimm, M., & Holfeld, J. (2017). Shockwaves prevent from heart failure after acute myocardial ischaemia via RNA/protein complexes. *Journal of Cellular and Molecular Medicine*, 21(4). <https://doi.org/10.1111/jcmm.13021>
- Tepeköylü, C., Wang, F. S., Kozaryn, R., Albrecht-Schgoer, K., Theurl, M., Schaden, W., Ke, H. J., Yang, Y., Kirchmair, R., Grimm, M., Wang, C. J., & Holfeld, J. (2013). Shock wave treatment induces angiogenesis and mobilizes endogenous CD31/CD34-positive endothelial cells in a hindlimb ischemia model: Implications for angiogenesis and vasculogenesis. *Journal of Thoracic and Cardiovascular Surgery*. <https://doi.org/10.1016/j.jtcvs.2013.01.017>
- Van Der Jagt, O. P., Piscaer, T. M., Schaden, W., Li, J., Kops, N., Jahr, H., Van Der Linden, J. C., Waarsing, J. H., Verhaar, J. A. N., De Jong, M., & Weinans, H. (2011). Unfocused extracorporeal shock waves induce anabolic effects in rat bone. *Journal of Bone and Joint Surgery - Series A*. <https://doi.org/10.2106/JBJS.I.01535>
- van der Jagt, O. P., van der Linden, J. C., Schaden, W., van Schie, H. T., Piscaer, T. M., Verhaar, J. a N., Weinans, H., & Waarsing, J. H. (2009). Unfocused extracorporeal shock wave therapy as potential treatment for osteoporosis. *Journal of Orthopaedic Research: Official Publication of the Orthopaedic Research Society*, 27(11), 1528–1533. <https://doi.org/10.1002/jor.20910>
- Van Der Jagt, O. P., Waarsing, J. H., Kops, N., Schaden, W., Jahr, H., Verhaar, J. A. N., & Weinans, H. (2013). Unfocused extracorporeal shock waves induce anabolic effects in osteoporotic rats. *Journal of Orthopaedic Research*, 31(5), 768–775. <https://doi.org/10.1002/jor.22258>
- Vinay, J., Moreno, D., Vives, A., Rajmil, O., Ruiz-Castañe, E., & Sanchez-Curbelo, J. (2017). 026 Penile Low Intensity Shock Wave Therapy for PDE5I Non-Responders: A Prospective, Randomized, Placebo-Controlled Study. *The Journal of Sexual Medicine*. <https://doi.org/10.1016/j.jsxm.2016.11.028>
- Wang, C.-J., Kuo, Y.-R., Wu, R.-W., Liu, R.-T., Hsu, C.-S., Wang, F.-S., & Yang, K. D. (2009). Extracorporeal shockwave treatment for chronic diabetic foot ulcers. *The Journal of Surgical Research*, 152(1), 96–103. <https://doi.org/10.1016/j.jss.2008.01.026>
- Weihs, A. M., Fuchs, C., Teuschl, A. H., Hartinger, J., Slezak, P., Mittermayr, R., Redl, H., Junger, W. G., Sitte, H. H., & Rünzler, D. (2014). Shock wave treatment enhances cell proliferation and improves wound healing by ATP release-coupled extracellular signal-regulated kinase (ERK) activation. *The Journal of Biological Chemistry*, 289(39), 27090–27104. <https://doi.org/10.1074/jbc.M114.580936>
- Wolff, K. S., Wibmer, A., Pusch, M., Prusa, A. M., Pretterklieber, M., Teufelsbauer, H., & Schaden, W. (2011). The Influence of Comorbidities and Etiologies on the Success of Extracorporeal Shock Wave Therapy for Chronic Soft Tissue Wounds: Midterm Results. *Ultrasound in Medicine and Biology*, 37(7), 1111–1119. <https://doi.org/10.1016/j.ultrasmedbio.2011.04.007>

- Wu, A. K., Zhang, X., Wang, J., Ning, H., Zaid, U., Villalta, J. D., Wang, G., Banie, L., Lin, G., & Lue, T. F. (2018). Treatment of stress urinary incontinence with low-intensity extracorporeal shock wave therapy in a vaginal balloon dilation induced rat model. *Translational Andrology and Urology*. <https://doi.org/10.21037/tau.2017.12.36>
- Wu, S. S., Ericson, K. J., & Shoskes, D. A. (2020). Retrospective comparison of focused shockwave therapy and radial wave therapy for men with erectile dysfunction. *Translational Andrology and Urology*. <https://doi.org/10.21037/tau-20-911>
- Yang, M.-Y., Chiang, Y.-C., Huang, Y.-T., Chen, C.-C., Wang, F.-S., Wang, C.-J., & Kuo, Y.-R. (2014). Serum Proteomic Analysis of Extracorporeal Shock Wave Therapy–Enhanced Diabetic Wound Healing in a Streptozotocin-Induced Diabetes Model. *Plastic and Reconstructive Surgery*, 133(1), 59–68. <https://doi.org/10.1097/01.prs.0000439050.08733.cf>
- Yih, J. (2020). 195 Retrospective Chart Review of Treatment Outcome Following Low-Intensity Shockwave Therapy for the Treatment of Vestibulodynia with UroGold 100™. *The Journal of Sexual Medicine*. <https://doi.org/10.1016/j.jsxm.2019.11.192>
- Yih, J., Goldstein, S., Georgeon, L., Ramirez, R., & Goldstein, I. (2020). 318 Retrospective Review of Improvement of Erectile Function after Low Intensity Shockwave Treatment with UroGold 100™. *The Journal of Sexual Medicine*. <https://doi.org/10.1016/j.jsxm.2019.11.139>
- Zhang, X., Ruan, Y., Wu, A. K., Zaid, U., Villalta, J. D., Wang, G., Banie, L., Reed-Maldonado, A. B., Lin, G., & Lue, T. F. (2020). Delayed Treatment With Low-intensity Extracorporeal Shock Wave Therapy in an Irreversible Rat Model of Stress Urinary Incontinence. *Urology*. <https://doi.org/10.1016/j.urology.2020.03.035>
- Zimpfer, D., Aharinejad, S., Holfeld, J., Thomas, A., Dumfarth, J., Rosenhek, R., Czerny, M., Schaden, W., Gmeiner, M., Wolner, E., & Grimm, M. (2009). Direct epicardial shock wave therapy improves ventricular function and induces angiogenesis in ischemic heart failure. *The Journal of Thoracic and Cardiovascular Surgery*, 137(4), 963–970. <https://doi.org/10.1016/j.jtcvs.2008.11.006>
- Zins, S. R., Amare, M. F., Tadaki, D. K., Elster, E. A., & Davis, T. A. (2010). Comparative analysis of angiogenic gene expression in normal and impaired wound healing in diabetic mice: Effects of extracorporeal shock wave therapy. *Angiogenesis*, 13(4), 293–304. <https://doi.org/10.1007/s10456-010-9186-9>

A decorative graphic in the bottom left corner consisting of several overlapping, wavy, blue lines that create a sense of motion and depth.

Witness. The Spark of Life.

MTS Medical UG (limited liability) | Robert-Bosch-Str. 18 | 78467 Konstanz |
Germany | www.mts-medical.com